

# Guideline Safe Use of Contrast Media Part 3

This part comprises:

- Iodine-induced hyperthyroidism
- Safe use of contrast media during pregnancy and lactation
- Safe use of contrast media in patients with rare diseases
- Safe time intervals between contrast media administrations
- Contrast induced encephalopathy
- Hypersensitivity reactions after contrast media administration (extension of [part 2](#))
- Analytical interference of contrast media with laboratory tests
- Gadolinium deposition (extension of [part 2](#))

## **INITIATED BY**

Radiological Society of The Netherlands (NVvR)

## **IN ASSOCIATION WITH**

Netherlands Association of Internal Medicine (NIV)

The Dutch Association of Neurosurgery (NVvN)

The Dutch Society of Allergology and Clinical Immunology (NVvAKI)

The Dutch Society of Cardiology (NVVC)

The Dutch Society of Clinical Chemistry and Laboratory Medicine (NVKC)

The Dutch Society of Endocrinology (NVE)

The Dutch Society of Neurology (NVN)

The Dutch Society of Obstetrics and Gynaecology (NVOG)

The Dutch Society of Surgery (NVvH) / The Dutch Society of Vascular Surgery (NVvV)

## **WITH THE ASSISTANCE OF**

Knowledge Institute of Medical Specialists

## **FINANCED BY**

Quality Funds of Medical Specialists

**Colophon**

GUIDELINE SAFE USE OF CONTRAST MEDIA - PART 3

© 2022

Radiological Society of the Netherlands

Mercatorlaan 1200, 3528 BL Utrecht

088 110 25 25

[nvvr@radiologie.nl](mailto:nvvr@radiologie.nl)

[www.radiologen.nl](http://www.radiologen.nl)

**All rights reserved**

The text in this publication can be copied, saved, or made public in any manner: electronically, by photocopy or in another way, but only with prior permission of the publisher. Permission for usage of (parts of) the text can be requested by writing or e-mail, only form the publisher. Address and email: see above.

## Content

<b>The guideline development group</b> .....	<b>4</b>
<b>Overall Introduction</b> .....	<b>5</b>
<b>Abbreviations used in this guideline</b> .....	<b>7</b>
<b>Summary of recommendations*</b> .....	<b>9</b>
<b>Samenvatting van aanbevelingen (Nederlands)</b> .....	<b>24</b>
<b>Justification of the guideline</b> .....	<b>39</b>
<b>Chapter 1 Prevention of Iodine-Induced Hyperthyroidism after Iodine-Based Contrast Media</b>	
<b>Administration</b> .....	<b>47</b>
<b>Chapter 2 Safe Use of Contrast Media during Pregnancy</b> .....	<b>54</b>
<b>Chapter 3 Safe Use of Contrast Media during Lactation</b> .....	<b>64</b>
<b>Chapter 4 Safe use of Contrast Media in Patients with Rare Diseases</b> .....	<b>68</b>
Module 4.1 Safe Use of Contrast Media in Patients with Multiple Myeloma.....	68
Module 4.2 Safe Use of Contrast Media in Patients with Pheochromocytoma and Paragangliomas.....	73
Module 4.3 Safe Use of Contrast Media in Patients with Myasthenia Gravis.....	77
Module 4.4 Safe Use of Contrast Media in Patients with Systemic Mastocytosis .....	81
<b>Chapter 5 Safe Time Intervals between Contrast-Enhanced Studies</b> .....	<b>86</b>
Module 5 Multiple Examinations with Contrast Media in Patients with Normal or Reduced Renal Function .....	86
<b>Chapter 6 Prevention of Contrast-Induced Encephalopathy</b> .....	<b>103</b>
<b>Chapter 7 Follow-up Strategies after Hypersensitivity Reactions to Contrast Media</b> .....	<b>107</b>
Introduction to Hypersensitivity Reactions to Contrast Media .....	107
Supplement: Definitions of Adverse Drug Reactions .....	120
Module 7.1 In Vitro Tests in Patients with Hypersensitivity Reactions to Contrast Media .....	125
Module 7.2 Diagnostic Value of Skin Testing for Hypersensitivity Reactions to Contrast Media .....	130
Module 7.3 Risk Factors for Hypersensitivity Reactions to Contrast Media .....	141
Module 7.4 Prophylactic Measures for Prevention of Recurrent Hypersensitivity Reactions to Contrast Media .....	152
<b>Appendix 1. Flow charts</b> .....	<b>175</b>
<b>Appendix 2. Contrast Media Hypersensitivity: The Lalli and Weber Effects</b> .....	<b>177</b>
<b>Appendix 3. Allergology Services in The Netherlands</b> .....	<b>179</b>
<b>Chapter 8 Analytical Interference of Contrast Media with Clinical Laboratory Tests</b> .....	<b>180</b>
<b>Chapter 9 Gadolinium Deposition after Administration of Gadolinium-Based Contrast Agents</b> ....	<b>188</b>
Introduction to Safe Use of Gadolinium-Based Contrast Agents .....	188
Module 9.1 Gadolinium Deposition in the Brain and Body.....	198
Module 9.2 Strategies for Dose Reduction of Gadolinium-Based Contrast Agents .....	205
<b>Supplemental Tables</b> .....	<b>222</b>

## The guideline development group

### Guideline development group

- Dekkers I.A. (Ilona), clinical epidemiologist and radiologist, Leiden University Medical Center, Leiden
- Geenen R.W.F. (Remy), radiologist, Noordwest Ziekenhuisgroep, Alkmaar
- Kerstens M.N. (Michiel), internist-endocrinologist, University Medical Centre Groningen
- Krabbe J.G. (Hans), clinical chemist-endocrinologist, Medisch Spectrum Twente, Enschede
- Rossius M.J.P. (Mariska), radiologist, Erasmus Medical Centre, Rotterdam
- Uyttenboogaart M. (Maarten), neurologist and neuro-interventionalist, University Medical Centre Groningen
- van de Luijngaarden K.M. (Koen), vascular surgeon, Maasstad Ziekenhuis, Rotterdam
- van der Molen A.J. (Aart), chair guideline development group, radiologist, Leiden University Medical Center, Leiden
- van der Wolk S.L. (Sabine), gynaecologist-obstetrician, Haga Ziekenhuis, Den Haag
- van de Ven A.A.J.M. (Annick), internist-allergologist-immunologist, University Medical Centre Groningen (until 1.7.2022)
- van der Houwen, T.B. (Tim), internist-allergologist-immunologist, Amsterdam University Medical Center (from 1.7.2022)

### Invited experts

- van Maaren M.S. (Maurits), internist-allergologist-immunologist, Erasmus MC, Rotterdam

### Methodological support

- Abdollahi M. (Mohammadreza), advisor, Knowledge Institute of the Federation Medical Specialists
- Labeur Y.J. (Yvonne), junior advisor, Knowledge Institute of the Federation Medical Specialists
- Mostovaya I.M. (Irina), senior advisor, Knowledge Institute of the Federation Medical Specialists

## Overall Introduction

### Reason for making this guideline

The Radiological Society of the Netherlands (Nederlandse Vereniging voor Radiologie/NVvR) deemed a set of new guidelines on the Safe Use of Contrast Media (CM) highly necessary and relevant. In radiology, contrast media, such as Iodine-based Contrast Media (ICM) and Gadolinium Based Contrast Agents (GBCA), are extensively used. The overall goal of this set of guidelines was to increase safety and awareness around contrast media. Practical recommendations are given in each chapter.

The four parts of the Safe Use of Contrast Media guidelines cover following topics regarding CM safety:

#### [Safe Use of Contrast Media - Part 1](#) (finalized in 2017):

- Prevention of contrast-associated acute kidney injury (CA-AKI\*) from iodine-based contrast media
- Iodine-based contrast media use in patients with type-2 diabetes taking metformin
- Iodine-based contrast media use in patients on chronic dialysis

#### [Safe Use of Contrast Media - Part 2](#) (finalized in 2019):

- Prophylaxis and management of hypersensitivity reactions to contrast media
- Safe use of gadolinium-based contrast agents, in terms of prevention of post-contrast acute kidney injury (PC-AKI) and Nephrogenic systemic fibrosis (NSF)
- Contrast media injections with power injectors through (peripherally inserted) central venous lines and implantable ports
- Contrast media extravasation

#### Safe Use of Contrast Media - Part 3 (finalized in 2022):

- Prevention of iodine-induced hyperthyroidism
- Safe use of contrast media use during pregnancy and lactation
- Safe use of contrast media use in patients with rare diseases:
  - Patients with Multiple Myeloma (M. Kahler)
  - Patients with Pheochromocytoma and Paraganglioma
  - Patients with Myasthenia Gravis
  - Patients with Mastocytosis
- Safe time intervals between contrast-enhanced studies
- Prevention of recurrent hypersensitivity reactions to contrast media (update of part 2), including the Weber and Lalli effects
- Analytical Interference of contrast media with clinical laboratory tests
- Gadolinium deposition in the body after gadolinium-based contrast agents (both update of part 2 and a new module about strategies for GBCA dose reduction)

#### Safe Use of Contrast Media - Part 4 Children (to be finalized in 2024):

- Prevention of contrast-associated acute kidney injury (CA-AKI\*) from iodine-based contrast media
- Prophylaxis and management of hypersensitivity reactions to contrast media
- Gadolinium deposition in the body after gadolinium-based contrast agents

\*Note: Post-contrast acute kidney injury is synonymous with contrast-associated acute kidney injury

### Aim of the current guideline

The aim of the Part 3 of Safe Use of Contrast Media guidelines is to critically review the recent evidence with the above trend in mind and tries to formulate new practical guidelines for all hospital

physicians to provide the safe use of contrast media in diagnostic and interventional studies. The ultimate goal of this guideline is to increase the quality of care, by providing efficient and expedient healthcare to the specific patient populations that may benefit from this healthcare and simultaneously guard patients from ineffective care. Furthermore, such a guideline should ideally be able to save money and reduce day-hospital waiting lists.

### **Focus of the guideline**

This part 3 of the Safe Use of Contrast Media guideline focuses on all adult (18 years and older) patients that receive CM during radiologic or cardiologic studies or interventions. The patient population for which these guidelines are developed are patients who receive intravascular, oral or intracavitary (intra-articular, intra-vesical, intra-cholangiographic) contrast media both in the clinical setting, as well as for outpatients. The guidelines do not cover radioactive contrast tracer use in nuclear medicine.

### **Users of this guideline**

This guideline is intended for all hospital physicians that request or perform diagnostic or interventional radiologic or cardiologic studies for their patients in which CM are involved.

### **Terminology and definitions**

The terminology and definitions of specific topics will be discussed in each of the specific topics/modules of this guideline. Abbreviations used in this guideline can be found below.

### **Guideline Disclaimers**

#### General

The aim of clinical guidelines is to help clinicians to make informed decisions for their patients. However, adherence to a guideline does not guarantee a successful outcome. Ultimately, healthcare professionals must make their own treatment decisions about care on a case-by-case basis, after consultation with their patients, using their clinical judgement, knowledge and expertise. A guideline cannot replace a physician's judgment in diagnosing and treatment of particular patients.

Guidelines may not be complete or accurate. The guideline development group and members of their boards, officers and employees disclaim all liability for the accuracy or completeness of a guideline, and disclaim all warranties, express or implied to their incorrect use.

Guidelines users always are urged to seek out newer information that might impact the diagnostic and treatment recommendations contained within a guideline.

#### Individualisation

In specific high-risk patient groups clinicians may have to regress from these general guidelines and decide on individualisation to best fit the needs of their patients.

#### Life-threatening situations or conditions

In acute life-threatening situations or conditions clinicians may have to regress from these general guidelines and decide on individualisation to best fit the needs of their patients in these situations or conditions.

## Abbreviations used in this guideline

ACR	American College of Radiology
ADR	Adverse Drug Reaction
AGEP	Acute Generalized Exanthematous Pustulosis
AGREE	Appraisal of Guidelines for Research & Evaluation
BAT	Basophil Activation Test
CA	Contrast Agent/Agents
CA-AKI	Contrast-Associated Acute Kidney Injury
CI	Confidence Interval
CM	Contrast Medium/Media
CT	Computed Tomography
DPT	Drug Provocation Test(s)
DHR	Drug Hypersensitivity Reaction(s)
DRESS	Drug Reaction with Eosinophilia and Systemic Symptoms
EAACI	European Association of Allergy and Clinical Immunology
EMA	European Medicines Agency
ENDA	European Network for Drug Allergies
ESUR	European Society of Urogenital Radiology
FDE	Fixed Drug Eruption
GBCA	Gadolinium-Based Contrast Agent/Agents
Gd	Gadolinium
GRADE	Grades of Recommendation, Assessment, Development, and Evaluation
HSR	Hypersensitivity Reaction/Reactions
ICM	Iodine-based Contrast Medium/Media
I	Iodine
IDT	Intradermal Test(s)
IgE	Immunoglobulin E
IHR	Immediate Hypersensitivity Reaction(s)
IM, i.m.	Intramuscular
IV, i.v.	Intravenous
LAREB	Landelijke Registratie en Evaluatie van Bijwerkingen
LTT	Lymphocyte Transfer Test
MPE	Maculopapular Exanthema
MRI	Magnetic Resonance Imaging
NIHR	Non-immediate Hypersensitivity Reaction(s)
NPV	Negative Predictive Value
NSF	Nephrogenic Systemic Fibrosis
NVvR	Nederlandse Vereniging voor Radiologie
OBS	Observational Study
OR	Odds Ratio
PO	Peroral
PPV	Positive Predictive Value
RCT	Randomized Clinical Trial
SCAR	Severe Cutaneous Adverse Reaction
SD	Standard Deviation
SDRIFE	Symmetrical Drug-Related Intertriginous and Flexural Exanthemas
SJS	Stevens-Johnson Syndrome
SPT	Skin Prick Test(s)
SR	Systematic Review
ST	Skin Test(s)
TEN	Toxic Epidermal Necrolysis

US  
WAO

Ultrasound  
World Allergy Organisation



## Summary of recommendations\*

\*Dutch version [below](#)

### Chapter 1 Prevention of Iodine-Induced Hyperthyroidism after Iodine-Based Contrast Media Administration

#### Clinical question

What are strategies for the prevention of iodine-induced thyroid dysfunction in:

- Patients with a history of cardiovascular disease and/or more than 65 years old
- Patients with a history of thyroid problems (goitre, hyperthyroidism, hypothyroidism)
- Patients who receive radioactive iodine treatment of the thyroid

#### Recommendations

Do not routinely measure the thyroid function before administration of iodine-based contrast media.

Consider measurement of thyroid function in high-risk patients for iodine-induced hyperthyroidism, especially in subjects older than 65 years and those with severe cardiovascular morbidity.

Consider prophylactic treatment prescribed by an internal medicine specialist in selected patients with subclinical hyperthyroidism receiving iodine-based contrast media (e.g., patients older than 65 years or with severe cardiovascular morbidity), starting one day before contrast administration and continuing for 14 days, consisting of thiamazole 30 mg once daily, with possible addition of potassium perchlorate 500 mg twice daily.

Avoid isotope imaging of the thyroid and/or radioactive iodine treatment for 4 to 8 weeks after iodine-based contrast media injection or withhold iodine-based contrast media administration 4 to 8 weeks before planned isotope imaging of the thyroid or radioactive iodine treatment.

### Chapter 2 Safe Use of Contrast Media during Pregnancy

#### Clinical question

What is the safety profile of contrast media (iodine-based contrast media or gadolinium-based contrast agents) during pregnancy for mother and child?

#### Recommendations

Do not withhold a pregnant patient imaging with iodine-based contrast media when this is medically indicated.

Be cautious with gadolinium-based contrast agents due to potential risks to the foetus. Only use contrast agents when the benefits clearly outweigh the possible risks.

### Chapter 3 Safe Use of Contrast Media during Lactation

#### Clinical question

What is the safety profile of contrast media (iodine-based contrast media or gadolinium-based contrast agents) during the lactation period for mother and child?

#### Recommendations

Due to the limited amount of excretion of into breast milk, the guideline development group believes it is safe to continue breastfeeding after administration of contrast media.

If patients wish to discontinue breastfeeding (shared decision making), a discontinuation of 24 hours is sufficient.

### Chapter 4 Safe Use of Contrast Media in Patients with Rare Diseases

#### Module 4.1 Safe Use of Contrast Media in Patients with Multiple Myeloma

#### Clinical question

Which prevention strategies are effective to prevent contrast-associated acute kidney injury (CA-AKI) in patients with Multiple Myeloma?

#### Recommendations

Always consider the general principles for prevention of acute kidney injury that were published in the [guideline Safe Use of Contrast Media, Part 1](#):

- Optimal nephrology care should be the primary goal in all chronic kidney disease patients, with attention to hydration status and medication use.
- Aim for clinical euvolemia, using normal saline or Ringer's lactate, before administration of intravascular iodine-based contrast media, regardless of eGFR.
- Consider patients with an eGFR  $<30$  ml/min/1.73m<sup>2</sup> at risk for CA-AKI.
- Consult a nephrologist/internist for patients with an eGFR  $<30$  ml/min/1.73m<sup>2</sup>.

Determine in each patient with multiple myeloma whether administration of iodine-based contrast media is indicated or if an alternative imaging technique is possible.

- Apply the same precautions to prevent contrast-associated acute kidney injury (CA-AKI) in patients with multiple myeloma as in subjects without this disease, if there are no additional risk factors associated with multiple myeloma for development of acute renal insufficiency.
- For (euvoletic) patients with an eGFR <30 ml/min/1,73m<sup>2</sup> undergoing intravascular administration of iodine-based contrast media prehydrate with 3ml/kg/h NaHCO<sub>3</sub> 1.4% for 1h (or a total of 250ml) pre-CM administration.

In selected patients with additional risk factors associated with multiple myeloma for development of acute renal insufficiency (e.g., hypercalcemia, light chain cast nephropathy, amyloidosis), close consultation between the haematologist and imaging physician is needed to ensure an optimal risk-benefit balance, including whether administration of contrast media is warranted and if preventive measures are needed.

## Module 4.2 Safe Use of Contrast Media in Patients with Pheochromocytoma or Paraganglioma

### Clinical question

What safety strategy should be used for contrast media administration in patients with pheochromocytoma or paraganglioma (PPGL)?

This clinical question includes the following underlying question:

- How should intra-arterial and intravenous contrast administration be applied in patients with pheochromocytoma or paraganglioma?

### Recommendations

Prophylactic treatment with an  $\alpha$ -adrenergic receptor blocker ( $\pm$   $\beta$ -adrenergic receptor blocker) is not indicated before intravenous administration of iodine-based contrast media in patients with pheochromocytoma or paraganglioma.

Prophylactic treatment with an  $\alpha$ -adrenergic receptor blocker ( $\pm$   $\beta$ -adrenergic receptor blocker) is not indicated before intra-arterial administration of iodine-based contrast media in patients with pheochromocytoma or paraganglioma.

Gadolinium-based contrast agents and ultrasound contrast agents may be safely used in patients with pheochromocytoma or paraganglioma.

## Module 4.3 Safe Use of Contrast Media in Patients with Myasthenia Gravis

### Clinical question

What is role of contrast media in patients with exacerbations of myasthenia gravis after contrast media administration?

### Recommendations

Do not withhold contrast media to patients with myasthenia gravis, as the risk of a contrast media induced myasthenic exacerbation is very low.

## Module 4.4 Safe Use of Contrast Media in Patients with Systemic Mastocytosis

### Clinical question

Which strategies are effective in preventing hypersensitivity reactions and anaphylactic shock in patients with systemic mastocytosis after contrast media administration?

### Recommendations

Do not withhold iodine-based contrast media or gadolinium-based contrast agents in patients with systemic mastocytosis.

Recommendation for administration of contrast media in patients with systemic mastocytosis:

- Continue maintenance anti- allergic medication (e.g., H1-/H2-antihistamines)
- Be vigilant to react to a possible hypersensitivity reaction
- Observe the patient  $\geq 30$  min with IV in place
- In case of an allergic reaction, refer to a drug allergy specialist

## Chapter 5 Safe Time Intervals between Contrast-Enhanced Studies

### Module 5 Multiple Examinations with Contrast Media in Patients with Normal or Reduced Renal Function

### Clinical question

What is a safe time interval in patients with normal and reduced renal function between two radiological or cardiological examinations with contrast media?

What is a safe time interval in patients with reduced renal function between:

- 1 Two examinations using enhanced imaging with iodine-based contrast media?
- 2 Two examinations using enhanced imaging with gadolinium-based contrast agents?
- 3 Two examinations using enhanced imaging with an iodine-based contrast medium and a gadolinium-based contrast agent?

This question contains the following subgroups:

- Elective CT/Angio/MRI in patients with normal renal function (eGFR  $>60$  ml/min/1.73m<sup>2</sup>)

- Elective CT/Angio/MRI in patients with moderately reduced renal function (eGFR 30-60 ml/min/1.73m<sup>2</sup>)
- Elective CT/Angio/MRI in patients with severely reduced renal function (eGFR < 30 ml/min/1.73m<sup>2</sup>)
- CT/Angio/MRI in emergency or life-threatening situations

## Recommendations

### 1. Safe time intervals in enhanced imaging with iodine-based contrast media

Consider a waiting time between **elective** contrast-enhanced CT or (coronary) angiography with successive iodine-based contrast media administrations in patients with **normal renal function** (eGFR >60 ml/min/1.73m<sup>2</sup>) of:

- Optimally 12 hours (near complete clearance of the previously administered iodine-based contrast media)
- Minimally 4 hours (if clinical indication requires rapid follow-up)

Consider a waiting time between **elective** contrast-enhanced CT or (coronary) angiography with successive iodine-based contrast media administrations in patients with **moderately reduced renal function** (eGFR 30-60 ml/min/1.73m<sup>2</sup>) of:

- Optimally 48 hours (near complete clearance of the previously administered iodine-based contrast media)
- Minimally 16 hours (if clinical indication requires rapid follow-up)

Consider a waiting time between **elective** contrast-enhanced CT or (coronary) angiography with successive iodine-based contrast media administrations in patients with **severely reduced renal function** (eGFR < 30 ml/min/1.73m<sup>2</sup>) of:

- Optimally 168 hours (near complete clearance of the previously administered iodine-based contrast media)
- Minimally 60 hours (if clinical indication requires rapid follow-up)

In **emergency or life-threatening situations**, employ less waiting time between contrast-enhanced CT or (coronary) angiography with successive iodine-based contrast media administrations.

### 2. Safe time intervals in enhanced imaging with gadolinium-based contrast agents

Consider a waiting time between **elective** contrast-enhanced MRI with successive gadolinium-based contrast agent administrations in patients with **normal renal function** (eGFR >60 ml/min/1.73m<sup>2</sup>) of:

- Optimally 12 hours (near complete clearance of the previously administered gadolinium-based contrast agent)

- Minimally 4 hours (if clinical indications require rapid follow-up)

Consider a waiting time between **elective** contrast-enhanced MRI with successive gadolinium-based contrast agent administrations in patients with **moderately reduced renal function** (eGFR 30-60 ml/min/1.73m<sup>2</sup>) of:

- Optimally 48 hours (near complete clearance of the previously administered gadolinium-based contrast agent)
- Minimally 16 hours (if clinical indications require rapid follow-up)

Consider a waiting time between **elective** contrast-enhanced MRI with successive gadolinium-based contrast agent administrations in patients with **severely reduced renal function** (eGFR < 30 ml/min/1.73m<sup>2</sup>) of:

- Optimally 168 hours (near complete clearance of the previously administered gadolinium-based contrast agent)
- Minimally 60 hours (if clinical indications require rapid follow-up)

**In emergency or life-threatening situations**, employ less waiting time between contrast-enhanced MRI with successive gadolinium-based contrast agent administrations.

### 3. Safe time intervals in enhanced imaging with an iodine-based contrast medium and a gadolinium-based contrast agent

When combining contrast-enhanced CT or (coronary) angiography with an iodine-based contrast medium and contrast-enhanced MRI with a gadolinium-based contrast agent on the same day in **elective** situations, it is better to start with the MRI examination, unless the CT examination is intended for the kidneys, ureters, or bladder (CT Urography).

Consider a waiting time between **elective** contrast-enhanced MRI with a gadolinium-based contrast agent and contrast-enhanced CT or (coronary) angiography with an iodine-based contrast medium in patients with **normal renal function** (eGFR >60 ml/min/1.73m<sup>2</sup>) of:

- Optimally 6 hours (near complete clearance of the effects of the previously administered gadolinium-based contrast agent)
- Minimally 2 hours (if the clinical indication requires rapid follow-up)

Consider a waiting time between **elective** contrast-enhanced MRI with a gadolinium-based contrast agent and contrast-enhanced CT or (coronary) angiography with an iodine-based contrast medium in patients with **moderately reduced renal function** (eGFR 30-60 ml/min/1.73m<sup>2</sup>) of:

- Optimally 48 hours (near complete clearance of the previously administered gadolinium-based contrast agent)

- Minimally 16 hours (if the clinical indication requires rapid follow-up)

Consider a waiting time between **elective** contrast-enhanced MRI with a gadolinium-based contrast agent and contrast-enhanced CT or (coronary) angiography with an iodine-based contrast medium in patients with **severely reduced renal function** (eGFR < 30 ml/min/1.73m<sup>2</sup>) of:

- Optimally 168 hours (near complete clearance of the previously administered gadolinium-based contrast agent)
- Minimally 60 hours (if the clinical indication requires rapid follow-up)

When combining contrast-enhanced CT or (coronary) angiography with an iodine-based contrast medium and contrast-enhanced MRI with a gadolinium-based contrast agent on the same day in **emergency or life-threatening situations**, employ no waiting time and perform back-to-back examinations.

## Chapter 6 Prevention of Contrast-Induced Encephalopathy

### Clinical question

Which strategies are effective for prevention of Contrast-Induced Encephalopathy (CIE)?

### Recommendations

Health care providers should be aware of the existence of Contrast-Induced Encephalopathy (CIE) following iodine-based contrast media administration.

Adequate prevention strategies have not been investigated in detail.

General advice for clinical practice:

1. Minimize the amount of iodine-based contrast media as much as possible during endovascular interventions.
2. Consider to hydrate patients with severe renal dysfunction (eGFR <30 ml/min/1.73m<sup>2</sup>) receiving iodine-based contrast media (see protocol in [Safe Use of Contrast Media Part 1](#)).
3. Closely monitor patients the first six hours after endovascular interventions for neurological symptoms and consult a neurologist immediately in case of neurological symptoms.
4. Depending on the clinical symptoms of contrast-induced encephalopathy, treatment with antiepileptic drugs, corticosteroids, intravenous hydration, and/or mannitol may be recommended.

## Chapter 7 Follow-up Strategies after Hypersensitivity Reactions to Contrast Media

### Module 7.1 In Vitro Tests in Patients with Hypersensitivity Reactions to Contrast Media (update of module 3 in [guideline part 2](#))

### Clinical question

What is the diagnostic value of serum and/or urine testing for contrast media induced hypersensitivity reactions?

### Recommendations

Measure serum tryptase, preferably between 1-2 hours (range 15 minutes to 4 hours) from the start of all moderate to severe immediate hypersensitivity reactions to contrast media. This measurement serves as a baseline for further allergologic examinations.

\*See also [flow charts](#)

Basophil activation tests are reserved for selected patients with moderate to severe acute hypersensitivity reactions and are only available in specialized drug allergy centres.

For nonimmediate hypersensitivity reactions there are no meaningful *in vitro* diagnostic tests available in the Netherlands.

## Module 7.2 Diagnostic Value of Skin Testing for Hypersensitivity Reactions to Contrast Media (update of module 4 in [guideline part 2](#))

### Clinical question

What should be done in patients with a history of hypersensitivity reactions after contrast media administration to decrease the risk of developing a recurrent hypersensitivity reaction?

### Recommendations

Refer the patient to a drug allergy specialist to perform skin tests for the suspected culprit and several commonly used alternatives, ideally within 6 months after the hypersensitivity reaction.

Refer the following patient groups:

- Moderate to severe immediate hypersensitivity reactions to a contrast medium
- Severe mucocutaneous non-immediate hypersensitivity reactions to a contrast medium
- Hypersensitivity reactions to two or more different contrast media (e.g., two different iodine-based contrast media or gadolinium agents, or an iodine-based contrast medium and a gadolinium-based contrast agent)
- All patients with breakthrough hypersensitivity reactions despite premedication with corticosteroids and/or H1-antihistamines

\*See also [flow charts](#)

Always specify the used contrast medium in the referral to the drug allergy specialist.



## Module 7.3 Risk Factors for Hypersensitivity Reactions to Contrast Media (update of module 5.1 in previous guideline)

### Clinical question

Which patients are at increased risk of developing hypersensitivity reactions after contrast media administration?

### Recommendations

Only consider a previous hypersensitivity reaction after contrast media administration a relevant risk factor for developing a new hypersensitivity reaction.

\*See also [flow charts](#)

## Module 7.4 Prophylactic Measures for Prevention of Recurrent Hypersensitivity Reactions to Contrast Media (update of module 5.2 of previous guideline)

### Clinical question

Which prophylactic measures should be taken in patients at increased risk of hypersensitivity reactions to contrast media?

This question contains the following patient categories:

- I Patients with previous immediate (acute) hypersensitivity reactions to iodine-based contrast media or gadolinium-based contrast agents
- II Patients with a previous breakthrough reaction to contrast media
- III Patients with previous hypersensitivity reactions to multiple contrast media
- IV Patients with previous nonimmediate (delayed) hypersensitivity reactions to iodine-based contrast media or gadolinium-based contrast agents

In addition, the following subjects were elaborated:

- V Cross-reactivity between contrast media
- VI Documentation of hypersensitivity reactions

### Recommendations

In all patients with a (documented) history of a hypersensitivity reaction to an iodine-based contrast medium or a gadolinium-based contrast agent, consider an alternative imaging modality. When this is not possible, consider performing an unenhanced exam, but only if the reduction in diagnostic quality is acceptable.

\*See also [flow charts](#)

I Patients with previous immediate (acute) hypersensitivity reactions to iodine-based contrast media or gadolinium-based contrast agents

In patients with a (documented) history of a **mild immediate** hypersensitivity reaction to an iodine-based contrast medium or a gadolinium-based contrast agent:

- Treat these patients as any other patient because of the low risk of developing a moderate or severe reaction

\*See also [flow charts](#)

In patients with a (documented) history of a **moderate or severe** hypersensitivity reaction to iodine-based contrast media or gadolinium-based contrast agents

- Postpone imaging and refer the patient to a drug allergy specialist

If there is no time to refer the patient to a drug allergy specialist:

- Choose a different iodine-based contrast medium or gadolinium-based contrast agent if the culprit contrast medium is known\*
- Consider a test dose by first giving 10% of the total contrast dose and observing the patient for >15 minutes; particularly with severe reactions and/or unknown culprit
- Observe the patient  $\geq$  30 min with IV in place
- Be vigilant to react to a possible new hypersensitivity reaction

\*See also [flow charts](#)

## II Patients with a previous breakthrough reaction to contrast media

In patients with a breakthrough hypersensitivity reaction to iodine-based contrast media or gadolinium-based contrast agents, always refer to a drug allergy specialist for skin testing with a panel of different iodine-based contrast media or gadolinium-based contrast agents.

\*See also [flow charts](#)

## III Patients with previous hypersensitivity reactions to multiple contrast media

In patients with hypersensitivity reactions to multiple iodine-based or gadolinium-based contrast media (either two or more different iodine-based contrast media or gadolinium-based contrast agents or to an iodine-based contrast medium and a gadolinium-based contrast agent) apply the same as above, but always refer the patient to a drug allergy specialist.

\*See also [flow charts](#)

## IV Patients with previous nonimmediate (delayed) hypersensitivity reactions to iodine-based contrast media or gadolinium-based contrast agents

- Do **not** give iodine-based contrast media or gadolinium-based contrast agents to a patient with a previous (suspected) severe nonimmediate skin eruption with danger signs\*\*
- Refer the patient immediately to a drug allergy specialist

\*See also [flow charts](#)

In patients with a history of a mild-moderate nonimmediate skin eruption without danger signs\*\*:

- Choose a different iodine-based contrast medium or gadolinium-based contrast agent if the culprit contrast medium is known\*
- Instruct the patient in case of a recurrent reaction to take pictures of the skin lesions and contact the radiology or cardiology department for feedback

\*See also [flow charts](#)

\* Consider cross-reactivity of contrast media (see Tables 7.4.1 and 7.4.2) and an increased risk for NIHR with use of iso-osmolar ICM.

\*\* Danger signs: erosive and/or haemorrhagic lesions, blistering and skin disruption, mucosal involvement, extracutaneous organ involvement (high fever, abnormal liver / kidney values, lymphadenopathy)

## V Cross-reactivity between contrast media

Cross-reactivity is most relevant in *allergic* hypersensitivity reactions.

It occurs with a higher frequency among:

- Iodine-based contrast media with a *N*-(2,3 hydroxypropyl)-carbamoyl side chain
- Macrocyclic gadolinium-based contrast agents

The drug allergy specialist determines through skin testing with a panel of different iodine-based contrast media and gadolinium-based contrast agents:

- The allergic nature of the hypersensitivity reaction
- Cross-reactivity between contrast media
- Suggestions for safe alternative contrast media

## VI Documentation of hypersensitivity reactions

The physician responsible for the administration of the contrast medium should accurately document the hypersensitivity reaction in the imaging report.

The physician responsible for the administration of the contrast medium or the drug allergy specialist should accurately document the hypersensitivity reaction in the electronic patient dossier.

It is essential that reporting should be based on the name of the *specific* contrast medium and be done by *physicians or drug allergy specialists* with experience in the use of contrast media.

After all hypersensitivity reactions to contrast media, the following should be registered:

- The place, date, and time of CM administration - in the imaging report and in the electronic patient record.
- The specific contrast medium name and dose (volume, concentration) - in the imaging report and in the electronic patient record.
- The type of hypersensitivity reaction, immediate or non-immediate - in the imaging report and in the electronic patient record.
- All patient symptoms and vital signs (blood pressure, pulse, respiration rate, oxygen saturation) - in the imaging report and in the electronic patient record.
- The treatment given and the response of the patient to the treatment - in the imaging report and in the electronic patient record.
- Any clinical follow-up and advice on the need for future premedication - in the imaging report and in the electronic patient record.
- Any results of the consultation with a drug allergy specialist on future CM administration - in the electronic patient record.

The physician responsible for the administration of the contrast medium or the drug allergy specialist should accurately document severe or unusual hypersensitivity reactions to the National Pharmacovigilance Authority LAREB.

## Chapter 8 Analytical Interference of Contrast Media on Clinical Laboratory Tests

### Clinical question

How can contrast media interfere with commonly performed laboratory tests?

- 1 Iodine-based contrast media' interference
- 2 Gadolinium-based contrast agents' interference

### Recommendations

#### Blood Analysis

Be aware that the potential interference of contrast media on laboratory tests is crucial to prevent adverse patient work-up. As with all laboratory tests, the results should be interpreted in relationship with the patient's medical history and clinical examination.

Consult the laboratory specialist if there are any discrepancies between clinical presentation and laboratory tests.

Perform clinical laboratory testing prior to administering contrast media or delay blood collection for non-emergency clinical laboratory testing\* for:

- At least 4 hours and optimally 12 hours after administration of the contrast medium in patients with normal kidney function (eGFR > 60 mL/min/1.73 m<sup>2</sup>)
- At least 16 hours and optimally 48 hours after administration of the contrast medium in patients with reduced kidney function (eGFR 30-60 mL/min/1.73 m<sup>2</sup>)

- At least 60 hours and optimally 168 hours after administration of the contrast medium in patients with reduced kidney function (eGFR < 30 mL/min/1.73 m<sup>2</sup>)

\*See also [Chapter 5 Safe time intervals](#)

### Urine Analysis

Perform urine clinical laboratory tests prior to contrast media administration. Another option is to delay urine collection for at least\*\*:

- At least 24 hours after administration of the contrast medium in patients with normal kidney function (eGFR > 60 mL/min/1.73 m<sup>2</sup>)
- At least 48 hours after administration of the contrast medium in patients with reduced kidney function (eGFR 30-60 mL/min/1.73 m<sup>2</sup>)
- At least 168 hours after administration of the contrast medium in patients with reduced kidney function (eGFR < 30 mL/min/1.73 m<sup>2</sup>)

\*\* based on near complete clearance of contrast media

## **Chapter 9 Gadolinium Deposition after Administration of Gadolinium-Based Contrast Agents**

### **Module 9.1 Gadolinium Deposition in the Brain and Body**

#### **Clinical question**

What is the effect of gadolinium deposition in the brain and body?

#### **Recommendations**

To date, even though there is evidence that gadolinium is deposited in tissues, there is no evidence of clinical symptoms nor harm associated with gadolinium deposition in the brain and body.

Ensure a strict indication for gadolinium-enhanced MRI and only use EMA-approved gadolinium-based contrast agents in all patients to minimize possible gadolinium deposition.

\*See also [module 9.2 Strategies for Dose Reduction of Gadolinium-Based Contrast Agents](#)

This guideline committee supports the ACR Committee on Drugs and Contrast Media's suggested terminology of Symptoms Associated with Gadolinium Exposure (SAGE) for self-reported symptoms and signs.

### **Module 9.2 Strategies for Dose Reduction of Gadolinium-Based Contrast Agents**

#### **Clinical question**

In which way can the dose of gadolinium be reduced / minimized without compromising diagnostic accuracy?

The following categories were defined:

- I Potential dose-reduction strategies for neuroimaging with gadolinium-based contrast agents
- II Potential dose-reduction strategies for cardiovascular imaging with gadolinium-based contrast agents
- III Potential dose-reduction strategies for musculoskeletal imaging with gadolinium-based contrast agents
- IV Potential dose-reduction strategies for abdominal imaging with gadolinium-based contrast agents
- V Potential dose-reduction strategies for breast imaging with gadolinium-based contrast agents

## Recommendations

### I Potential dose-reduction strategies for neuroimaging with gadolinium-based contrast agents

Findings of the LEADER-75 trial indicate that the dose of gadolinium-based contrast agents (gadobutrol) may be reduced to up to 75% of the standard dose (0.075 mmol/kg bodyweight (equivalent to 0.075 ml/kg bodyweight)) in patients with suspected brain lesions.

The use of deep learning based methods for gadolinium dose reduction in patients suspected with brain metastasis is not recommended based on the current literature.

### II Potential dose-reduction strategies for cardiovascular imaging with gadolinium-based contrast agents

The use of standard dose imaging is recommended in patients with clinical indications for the administration of gadolinium-based contrast agents in cardiac MRI.

Non-CE MRA techniques (e.g., time-of-flight MRA) are widely available and can be used for accurate evaluation of stenosis grade of the supra-aortic vasculature.

Non-CE ECG-gated MRA sequences are widely available and recommended over (low-dose) CE MRA techniques for the evaluation of aortic dimensions.

### III Potential dose-reduction strategies for musculoskeletal imaging with gadolinium-based contrast agents

The use of standard dose imaging is recommended in patients with clinical indications for the administration of gadolinium-based contrast agents in musculoskeletal imaging.

### IV Potential dose-reduction strategies for abdominal imaging with gadolinium-based contrast agents

*Prostate*

There is increasing evidence that biparametric (T2w + DWI) protocols may be used as an alternative to multiparametric (T2w + DWI + DCE) protocols for the detection of prostate cancer.

*Liver*

The use of standard dose imaging is recommended in patients with clinical indications for the administration of gadolinium-based contrast agents in liver MRI.

V Potential dose-reduction strategies for breast imaging with gadolinium-based contrast agents

The use of standard dose imaging is recommended in patients with clinical indications for the administration of gadolinium based contrast agents in breast MRI.

## Samenvatting van aanbevelingen (Nederlands)

### Hoofdstuk 1 Preventie van jodium-geïnduceerde hyperthyroïdie na het gebruik van jodiumhoudend contrastmiddel

#### Klinische vraag

Wat zijn strategieën voor de preventie van jodium-geïnduceerde schildklierdysfunctie bij:

- Patiënten met een geschiedenis van hart- en vaatziekten
- Patiënten van meer dan 65 jaar oud
- Patiënten met een geschiedenis van schildklier problemen (struma, hyperthyroïdie, hypothyroïdie)

#### Aanbevelingen

Meet de schildklierfunctie niet routinematig voor toediening van jodiumhoudend contrastmiddel.

Overweeg meting van de schildklierfunctie bij patiënten met een verhoogd risico op het ontwikkelen van jodium-geïnduceerde hyperthyroïdie, vooral bij personen ouder dan 65 jaar en patiënten met ernstige cardiovasculaire morbiditeit.

Overweeg een profylactische behandeling in geselecteerde patiënten met subklinische hyperthyroïdie, die jodiumhoudend contrastmiddel ontvangen, bijvoorbeeld patiënten ouder dan 65 jaar oud of met ernstige cardiovasculaire morbiditeit.

Start profylactische therapie één dag voor contrastmiddeltoediening en continueer 14 dagen met thiamazol (30 mg eenmaal per dag) en voeg indien nodig kaliumperchloraat toe (500mg tweemaal per dag).

Vermijd isotopen-beeldvorming van de schildklier en/of behandeling met radioactief jodium tot 4-8 weken na injectie van jodiumhoudend contrastmiddel. Of geef geen jodiumhoudend contrastmiddel 4-8 weken voor een geplande isotopen-scintigrafie van de schildklier of voor een behandeling met radioactief jodium.

### Hoofdstuk 2 Veilig gebruik van contrastmiddelen tijdens de zwangerschap

#### Klinische vraag

Wat is het veiligheidsprofiel van contrastmiddelen (jodiumhoudend en gadoliniumhoudend) tijdens de zwangerschap voor moeder en kind?

#### Aanbevelingen



Onthoud geen zwangere patiënten van beeldvorming met jodiumhoudend contrastmiddel, wanneer dit medisch geïndiceerd is.

Wees terughoudend met gadoliniumhoudend contrastmiddel vanwege de potentiële risico's voor de foetus. Gebruik alleen contrastmiddelen wanneer de baten duidelijk groter zijn dan de risico's.

### Hoofdstuk 3 Veilig gebruik van contrastmiddelen bij lactatie

#### Klinische vraag

Wat is het veiligheidsprofiel van contrastmiddelen (jodiumhoudend en gadoliniumhoudend) tijdens de lactatieperiode voor moeder en kind?

#### Aanbevelingen

Vanwege de beperkte excretie van contrastmiddelen in de moedermelk, is de werkgroep van mening dat het veilig is om borstvoeding te continueren na toediening van contrastmiddelen.

Als de patiënte de borstvoeding zelf wenst te onderbreken (gezamenlijke besluitvorming met de arts), dan is een tijdsperiode van 24 uur voldoende.

### Hoofdstuk 4 Veilig gebruik van contrastmiddelen bij patiënten met zeldzame ziekten

#### Module 4.1 Veilig gebruik van contrastmiddelen bij patiënten met multipel myeloom

#### Klinische vraag

Welke preventiestrategieën zijn effectief om contrastmiddel-geassocieerde acute nierschade (CA-AKI) bij patiënten met multipel myeloom te voorkomen?

#### Aanbevelingen

Neem altijd de algemene principes voor preventie van acute nierschade in acht, die al werden gepubliceerd in de richtlijn [Veilig Gebruik van Contrastmiddelen, Deel 1](#):

- Optimale nefrologische zorg dient het primaire doel te zijn bij alle patiënten met chronische nierziekten, met specifieke aandacht voor hydratiestatus en medicatiegebruik.
- Streef naar klinische euvolemie, gebruik normaal saline of Ringer's lactaat, voorafgaand aan een onderzoek met intravasculair jodiumhoudend contrastmiddel, ongeacht de eGFR waarde.
- Beschouw patiënten met een eGFR <30 ml/min/1,73m<sup>2</sup> tot een hoogrisico-groep voor CA-AKI.
- Consulteer een internist/nefroloog bij patiënten met een eGFR <30 ml/min/1,73m<sup>2</sup>.

Bepaal bij elke patiënt met een multipel myeloom of toediening van jodiumhoudend contrastmiddel noodzakelijk is, of dat alternatieve beeldvorming mogelijk is.

- Pas dezelfde voorzorgsmaatregelen toe om contrastmiddel-geassocieerde acute nierschade (CA-AKI) te voorkomen bij patiënten met multipel myeloom als bij patiënten zonder deze ziekte, wanneer er geen extra risicofactoren zijn, geassocieerd met multipel myeloom, voor het ontwikkelen van acute nierinsufficiëntie.
- Voor (euvolemische) patiënten met een eGFR <30 ml/min/1,73m<sup>2</sup> waarbij intravasculair jodiumhoudend contrastmiddel toegediend zal worden, prehydreer de patient met 3ml/kg/u NaHCO<sub>3</sub> 1,4% gedurende 1 uur (of 250ml in totaal) voor toediening van het contrastmiddel.

Bij geselecteerde patiënten met extra risicofactoren voor het ontwikkelen van acute nierinsufficiëntie (bijv. hypercalciëmie, lichte keten nefropathie, amyloïdose) is voorafgaand overleg tussen hematoloog en radioloog of cardioloog nodig om een betrouwbare inschatting te maken van de voordelen en de risico's. Hierbij moet worden bepaald of er een absolute indicatie is voor de toediening van jodiumhoudend contrastmiddel en of preventieve maatregelen in dat geval noodzakelijk zijn.

## Module 4.2 Veilig gebruik van contrastmiddelen bij patiënten met een feochromocytoom of paraganglioom

### Klinische vraag

Wat voor strategie wordt aanbevolen om contrastmiddel veilig toe te dienen bij patiënten met een feochromocytoom of paraganglioom?

Deze klinische vraag bevat de volgende subvraag:

- Hoe zou intra-arterieel en intraveneus contrast moeten worden toegediend bij patiënten met een feochromocytoom of paraganglioom?

### Aanbevelingen

Profylactische therapie met een adrenerge  $\alpha$ -receptorblokker ( $\pm$  adrenerge  $\beta$ -receptorblokker) is niet geïndiceerd bij intraveneuze toediening van jodiumhoudend contrastmiddel bij patiënten met een feochromocytoom of paraganglioom.

Profylactische therapie met een adrenerge  $\alpha$ -receptorblokker ( $\pm$  adrenerge  $\beta$ -receptorblokker) is niet geïndiceerd bij intra-arteriële toediening van jodiumhoudend contrastmiddel bij patiënten met een feochromocytoom of paraganglioom.

Gadoliniumhoudend contrastmiddel en contrastmiddel voor echografisch onderzoek kunnen veilig worden gebruikt bij patiënten met een feochromocytoom of paraganglioom.

#### **Module 4.3 Veilig gebruik van contrastmiddelen bij patiënten met Myasthenia Gravis**

##### **Klinische vraag**

Wat is de rol van contrastmiddelen bij patiënten met exacerbaties van myasthenia gravis na contrastmiddeltoediening?

##### **Aanbeveling**

Onthoud patiënten met myasthenia gravis niet van beeldvorming met contrastmiddel omdat het risico op exacerbatie door contrastmiddel erg laag is.

#### **Module 4.4 Veilig gebruik van contrastmiddelen bij patiënten met Mastocytose**

##### **Klinische vraag**

Welke strategieën zijn effectief om hypersensitiviteitsreacties en anafylactische shock te voorkomen bij patiënten met systemische mastocytose na contrastmiddeltoediening?

##### **Aanbevelingen**

Onthoud patiënten met systemische mastocytose niet van beeldvorming met een jodiumhoudend of gadoliniumhoudend contrastmiddel.

Aanbevelingen bij toedienen van contrastmiddelen bij patiënten met systemische mastocytose:

- Continueer antiallergische onderhoudsmedicatie (v.b. H1/H2-antihistamine)
- Wees alert om te reageren op een mogelijke hypersensitiviteitsreactie
- Observeer de patiënt  $\geq 30$  min met behoud van intraveneuze toegang
- Na een allergische reactie, verwijs indien nodig naar een allergoloog

#### **Hoofdstuk 5 Veilige tijdsintervallen tussen onderzoeken met contrastmiddeltoediening**

##### **Module 5 Meerdere onderzoeken met contrastmiddelen bij patiënten met normale of gereduceerde nierfunctie**

##### **Klinische vraag**

Wat is een veilig tijdsinterval bij patiënten met een verminderde nierfunctie tussen twee radiologische of cardiologische onderzoeken?

Wat is een veilig tijdsinterval bij patiënten met een verminderde nierfunctie en:

- 1 Twee onderzoeken met jodiumhoudend contrastmiddel?
- 2 Twee onderzoeken met gadoliniumhoudend contrastmiddel?
- 3 Twee onderzoeken met jodiumhoudend- en gadoliniumhoudend contrastmiddel?

Deze vraag bevat de volgende subgroepen:

- Electieve CT/Angio/MRI bij patiënten met een normale nierfunctie (eGFR >60 ml/min/1.73m<sup>2</sup>)
- Electieve CT/Angio/MRI bij patiënten matig verminderde nierfunctie (eGFR 30-60 ml/min/1.73m<sup>2</sup>)
- Electieve CT/Angio/MRI bij patiënten met ernstig verminderde nierfunctie (eGFR < 30 ml/min/1.73m<sup>2</sup>)
- CT/Angio/MRI bij spoedeisende of levensbedreigende situaties

## Aanbevelingen

1. Veilig tijdsinterval tussen radiologische of cardiologische onderzoeken met jodiumhoudende contrastmiddelen

Overweeg een wachttijd tussen **electieve** contrastmiddel-versterkte CT of (coronair) angiografie onderzoeken met meerdere jodiumhoudende contrastmiddeltoedieningen bij patiënten met een **normale nierfunctie** (eGFR>60 ml/min/1.73m<sup>2</sup>) van:

- Optimaal 12 uur (bijna complete eliminatie van vorig toegediend jodiumhoudend contrastmiddel)
- Minimaal 4 uur (als de klinische indicatie een snelle follow up vereist)

Overweeg een wachttijd tussen **electieve** contrastmiddel-versterkte CT of (coronair) angiografie onderzoeken met meerdere jodiumhoudende contrastmiddeltoedieningen bij patiënten met een **matig verminderde nierfunctie** (eGFR 30-60 ml/min/1.73m<sup>2</sup>) van:

- Optimaal 48 uur (bijna complete eliminatie van vorig toegediend jodiumhoudend contrastmiddel)
- Minimaal 16 uur (als de klinische indicatie een snelle follow up vereist)

Overweeg een wachttijd tussen **electieve** contrastmiddel-versterkte CT of (coronair) angiografie onderzoeken met meerdere jodiumhoudende contrastmiddeltoedieningen bij patiënten met een **ernstig verminderde nierfunctie** (eGFR <30 ml/min/1.73m<sup>2</sup>) van:

- Optimaal 168 uur (bijna complete eliminatie van vorig toegediend jodiumhoudend contrastmiddel)
- Minimaal 60 uur (als de klinische indicatie een snelle follow up vereist)

Bij **spoedeisende of levensbedreigende situaties**, houd minder wachttijd aan tussen contrast-versterkte onderzoeken met opeenvolgende jodiumhoudende contrastmiddeltoedieningen.

2. Veilig tijdsinterval tussen radiologische onderzoeken met gadoliniumhoudende contrastmiddelen

Overweeg een wachttijd tussen **electieve** contrastmiddel-versterkte MRI onderzoeken met meerdere gadoliniumhoudende contrastmiddeltoedieningen bij patiënten met een **normale nierfunctie** (eGFR>60 ml/min/1.73m<sup>2</sup>) van:

- Optimaal 12 uur (bijna complete eliminatie van het vorig toegediende gadoliniumhoudende contrastmiddel)
- Minimaal 4 uur (als de klinische indicatie een snelle follow up vereist)

Overweeg een wachttijd tussen **electieve** contrastmiddel-versterkte MRI onderzoeken met meerdere gadoliniumhoudende contrastmiddeltoedieningen bij patiënten met een **matig verminderde nierfunctie** (eGFR 30-60 ml/min/1.73m<sup>2</sup>) van:

- Optimaal 48 uur (bijna complete eliminatie van vorig toegediend gadoliniumhoudend contrastmiddel)
- Minimaal 16 uur (als de klinische indicatie een snelle follow up vereist)

Overweeg een wachttijd tussen **electieve** contrastmiddel-versterkte MRI onderzoeken met meerdere gadoliniumhoudende contrastmiddeltoedieningen bij patiënten met een **ernstig verminderde nierfunctie** (eGFR <30 ml/min/1.73m<sup>2</sup>) van:

- Optimaal 168 uur (bijna complete eliminatie van vorig toegediende gadoliniumhoudende contrastmiddel)
- Minimaal 60 uur (als de klinische indicatie een snelle follow up vereist)

Bij **spoedeisende of levensbedreigende situaties**, houd minder wachttijd aan tussen contrast-versterkte onderzoeken met opeenvolgende gadoliniumhoudende contrastmiddel-toedieningen.

### 3. Veilig tijdsinterval tussen radiologische of cardiologische onderzoeken met jodiumhoudende en gadoliniumhoudende contrastmiddelen

Bij CT of (coronair) angiografie met jodiumhoudend contrastmiddel en MRI met gadoliniumhoudend contrastmiddel op dezelfde dag in **electieve** situaties, is het beter om met het MRI-onderzoek te starten, behalve als het CT onderzoek voor de nieren, ureters of blaas bedoeld is (CT Urografie).

Overweeg een wachttijd tussen een **electieve** MRI met gadoliniumhoudend contrastmiddel en een CT of (coronair) angiografie met jodiumhoudend contrastmiddel bij patiënten met **een normale nierfunctie** (eGFR >60 ml/min/1.73m<sup>2</sup>) van:

- Optimaal 6 uur (bijna complete eliminatie van vorig toegediende gadoliniumhoudende contrastmiddel)
- Minimaal 2 uur (als de klinische indicatie een snelle follow up vereist)

Overweeg een wachttijd tussen een **electieve** MRI met gadoliniumhoudend contrastmiddel en een CT of (coronair) angiografie met jodiumhoudend contrastmiddel bij patiënten met **een matig verminderde nierfunctie** (eGFR 30-60 ml/min/1.73m<sup>2</sup>) van:

- Optimaal 48 uur (bijna complete eliminatie van vorig toegediende gadoliniumhoudende contrastmiddel)
- Minimaal 16 uur (als de klinische indicatie een snelle follow up vereist)

Overweeg een wachttijd tussen een **electieve** MRI met gadoliniumhoudend contrastmiddel en een CT of (coronair) angiografie met jodiumhoudend contrastmiddel bij patiënten met **een ernstig verminderde nierfunctie** (eGFR <30 ml/min/1.73m<sup>2</sup>) van:

- Optimaal 168 uur (bijna complete eliminatie van vorig toegediende gadoliniumhoudende contrastmiddel)
- Minimaal 60 uur (als de klinische indicatie een snelle follow up vereist)

Bij CT of (coronair) angiografie met jodiumhoudend contrastmiddel en MRI met gadoliniumhoudend contrastmiddel op dezelfde dag in **spoedeisende of levensbedreigende situaties**, voer beide onderzoeken direct achter elkaar uit zonder wachttijd.

## Hoofdstuk 6 Preventie van contrastmiddel-geïnduceerde encefalopathie

### Klinische vraag

Wat zijn strategieën om contrastmiddel-geïnduceerde encefalopathie (CIE) te voorkomen?

### Aanbevelingen

Zorgmedewerkers zouden alert moeten zijn op het voorkomen van contrastmiddel-geïnduceerde encefalopathie (CIE) na toediening van een jodiumhoudend contrastmiddel.

Adequate preventiestrategieën zijn niet in detail onderzocht.

Het algemene advies voor de klinische praktijk:

1. Minimaliseer de hoeveelheid toegediend jodiumhoudend contrastmiddel zoveel mogelijk tijdens endovasculaire interventies
2. Overweeg om patiënten met een ernstige verminderde nierfunctie (eGFR <30 ml/min/1.73m<sup>2</sup>) te hydrateren voordat jodiumhoudend contrastmiddel wordt toegediend (zie protocol in richtlijn [Veilig Gebruik van Contrastmiddelen, Deel 1](#)).
3. Monitor patiënten de eerste 6 uur na endovasculaire interventies voor neurologische symptomen en consulteer laagdrempelig een neuroloog bij ontstaan van neurologische symptomen.
4. Behandel, afhankelijk van de klinische symptomen van CIE, met anti-epileptische medicatie, corticosteroiden, intraveneuze hydratatie en/of mannitol.

## Hoofdstuk 7 Follow up strategieën na hypersensitiviteitsreacties op contrastmiddelen

### Module 7.1 In vitro testen bij patiënten met hypersensitiviteitsreacties op contrastmiddelen (update van module 3 uit deel 2)

#### Klinische vraag

Wat is de diagnostische waarde van serum en/of urinetesten voor contrastmiddel-geïnduceerde hypersensitiviteitsreacties?

#### Aanbevelingen

Meet serum tryptase, het liefst binnen 1-2 uur (tussen 15 minuten en 4 uur) vanaf de start van alle matige tot ernstige acute hypersensitiviteitsreacties na contrastmiddeltoediening. Deze meting dient als baseline voor verder allergologisch onderzoek.

\*Zie ook [flow charts](#)

Basofiele activatietesten zijn gereserveerd voor selecte patiënten met matige tot ernstige acute hypersensitiviteitsreacties, en zijn alleen beschikbaar in gespecialiseerde allergologiecentra.

Voor niet-acute hypersensitiviteitsreacties zijn geen noemenswaardige in-vitro testen beschikbaar in Nederland.

### Module 7.2 Diagnostische waarde van huidtesten voor hypersensitiviteitsreacties na contrastmiddelen (update van module 4 uit deel 2)

#### Klinische vraag

Wat zou gedaan moeten worden bij patiënten met een geschiedenis van hypersensitiviteitsreacties na contrastmiddeltoediening om het risico op herhaling van hypersensitiviteitsreacties te voorkomen?

#### Aanbevelingen

Verwijs de patiënt naar een allergoloog om huidtesten uit te voeren met het te verwachten oorzakelijke contrastmiddel en met diverse alternatieve contrastmiddelen, bij voorkeur binnen 6 maanden na de hypersensitiviteitsreactie.

Doe dit bij de volgende patiëntengroepen:

- Matige tot ernstige acute hypersensitiviteitsreacties door een contrastmiddel
- Ernstige mucocutane niet-acute hypersensitiviteitsreacties door een contrastmiddel
- Hypersensitiviteitsreacties op twee of meer verschillende contrastmiddelen van hetzelfde type (bijvoorbeeld twee verschillende jodiumhoudende contrastmiddelen) of twee of meer types contrastmiddelen (bijvoorbeeld een jodiumhoudend contrastmiddel en een gadoliniumhoudend contrastmiddel)
- Alle patiënten met een doorbraak hypersensitiviteitsreactie ondanks premedicatie met corticosteroiden en/of H1-antihistaminen

\*Zie ook [flow charts](#)

Specificeer altijd het gebruikte contrastmiddel in de verwijzing naar de allergoloog.

### **Module 7.3 Risicofactoren voor hypersensitiviteitsreacties op contrastmiddelen (update van module 5.1 uit deel 2)**

#### **Klinische vraag**

Welke patiënten hebben een verhoogd risico op hypersensitiviteitsreacties na contrastmiddeltoediening?

#### **Aanbevelingen**

Beschouw alleen een eerdere hypersensitiviteitsreactie als een relevante risicofactor voor het ontwikkelen van een nieuwe hypersensitiviteitsreactie.

### **Module 7.4 Profylactische maatregelen om hypersensitiviteitsreacties na contrastmiddelen te voorkomen (update van module 5.2 uit deel 2)**

#### **Klinische vraag**

Welke profylactische maatregelen zouden moeten worden genomen bij patiënten met een verhoogd risico op hypersensitiviteitsreacties na contrastmiddeltoediening?

Deze vraag bevat de volgende patiëntcategorieën:

- I Patiënten met voorgaande (acute) hypersensitiviteitsreacties na jodiumhoudend contrastmiddel of gadoliniumhoudend contrastmiddel
- II Patiënten met voorgaande doorbraakreactie na contrastmiddelen
- III Patiënten met een voorgaande hypersensitiviteitsreactie na meerdere contrastmiddelen
- IV Patiënten met een voorgaande niet-acute (vertraagde) hypersensitiviteitsreactie na jodiumhoudend contrastmiddel of gadoliniumhoudend contrastmiddel



Daarnaast werden de volgende onderwerpen behandeld:

- V Kruisreactiviteit tussen contrastmiddelen
- VI Documentatie van hypersensitiviteitsreacties

## Aanbevelingen

Bij alle patiënten met een (gedocumenteerde) geschiedenis van een hypersensitiviteitsreactie op een jodiumhoudend contrastmiddel of een gadoliniumhoudend contrastmiddel, overweeg een alternatieve beeldvormingstechniek. Wanneer dit niet mogelijk is, overweeg om onderzoek zonder contrastmiddel uit te voeren, maar alleen als dit een acceptabele reductie in diagnostische kwaliteit oplevert.

\*Zie ook [flow charts](#)

### I Patiënten met voorgaande (acute) hypersensitiviteitsreacties na jodiumhoudend contrastmiddel of gadoliniumhoudend contrastmiddel

Bij patiënten met een (gedocumenteerde) geschiedenis van een **milde acute** hypersensitiviteitsreactie door jodiumhoudend contrastmiddel of gadoliniumhoudende contrastmiddel:

- Behandel deze patiënten als elke andere patiënt, aangezien er geen risico is op het ontwikkelen van een matige of ernstige overgevoeligheidsreactie.

\*Zie ook [flow charts](#)

Bij patiënten met een (gedocumenteerde) geschiedenis van een **matige tot ernstige acute** overgevoeligheidsreactie door jodiumhoudend contrastmiddel of gadoliniumhoudende contrastmiddel:

- Stel het onderzoek uit en verwijfs naar een allergoloog.

Als er geen tijd is om de patiënt naar een allergoloog te verwijfsen:

- Kies een ander jodiumhoudend contrastmiddel of gadoliniumhoudend contrastmiddel als het contrastmiddel dat de reactie veroorzaakte bekend is\*
- Overweeg om een test te doen door eerst 10% van het contrastmiddel te geven en de patiënt >15 minuten te observeren: vooral bij ernstige reacties en wanneer het contrastmiddel dat de reactie veroorzaakte onbekend is
- Observeer de patiënt  $\geq 30$  min met behoud van intraveneuze toegang
- Wees alert op een nieuwe overgevoeligheidsreactie

\*Zie ook [flow charts](#)

### II Patiënten met voorgaande doorbraakreactie na contrastmiddelen

Verwijfs patiënten met een doorbraak overgevoeligheidsreactie op jodiumhoudend contrastmiddel of gadoliniumhoudend contrastmiddel altijd naar een allergoloog voor huidtesten met verschillende jodiumhoudende contrastmiddelen en gadoliniumhoudende contrastmiddelen.

\*Zie ook [flow charts](#)

### III Patiënten met een voorgaande hypersensitiviteitsreactie na meerdere contrastmiddelen

Verwijs patiënten met een overgevoeligheidsreactie na meerdere jodiumhoudende contrastmiddelen of gadoliniumhoudende contrastmiddelen (ofwel 2 of meer jodiumhoudende contrastmiddelen, ofwel 2 of meer gadoliniumhoudende contrastmiddelen, ofwel een jodiumhoudend contrastmiddel én een gadoliniumhoudend contrastmiddel) altijd naar een allergoloog. Pas daarnaast dezelfde principes als hierboven omschreven toe.

\*Zie ook [flow charts](#)

### IV Patiënten met een voorgaande niet-acute (vertraagde) hypersensitiviteitsreactie na jodiumhoudend contrastmiddel of gadoliniumhoudend contrastmiddel

Bij patiënten met (verdenking op) een eerdere ernstige niet-acute cutane overgevoeligheidsreactie waarbij alarmsymptomen\*\* aanwezig waren:

- Geef **geen** jodiumhoudend contrastmiddel of gadoliniumhoudend contrastmiddel
- Verwijs de patiënt direct naar een allergoloog.

Bij patiënten met een geschiedenis van een milde-matige niet-acute cutane overgevoeligheidsreactie waarbij alarmsymptomen\*\* ontbraken:

- Kies een ander jodiumhoudend contrastmiddel of gadoliniumhoudend contrastmiddel als het contrastmiddel dat de reactie veroorzaakte bekend is\*
- Geef instructies aan de patiënt als de reactie opnieuw optreedt om foto's van de huidlaesies te maken en naar de radiologie-afdeling te sturen voor beoordeling

\*Zie ook [flow charts](#)

\* Houd rekening met kruisreactiviteit van contrastmiddelen (zie Tabellen 7.4.1 en 7.4.2) en een verhoogd risico op NIHR bij iso-osmolaire ICM.

\*\* Alarmsymptomen: erosieve en/of hemorrhagische laesies, blaarvorming en schade aan de huid, betrokkenheid van slijmvliezen, extracutane orgaanbetrokkenheid (koorts, verstoorde lever- en/of nierwaarden, lymfadenopathie).

### V Kruisreactiviteit tussen contrastmiddelen

Kruisreactiviteit is het meest relevant bij *allergische* hypersensitiviteitsreacties.

Er is een hogere kans op kruisreactiviteit bij:

- Jodiumhoudend contrastmiddel met een N-(2,3 hydroxypropyl)-carbamoyl zijketen
- Macrocyclisch gadolinium-houdend contrastmiddel

De allergoloog bepaalt door middel van huidtesten met verschillende jodiumhoudende contrastmiddelen en gadoliniumhoudende contrastmiddelen:

- De oorzaak van de allergische reactie
- Kruisreactiviteit tussen verschillende contrastmiddelen
- Suggesties voor veilige alternatieve contrastmiddelen

## VI Documentatie van hypersensitiviteitsreacties

De arts die verantwoordelijk is voor de toediening van het contrastmiddel is ook verantwoordelijk voor accurate documentatie van de hypersensitiviteitsreactie in het verslag van de beeldvorming.

De arts die verantwoordelijk is voor de toediening van het contrastmiddel of de allergoloog is ook verantwoordelijk voor accurate documentatie van de hypersensitiviteitsreactie in het elektronisch patiëntendossier.

Documenteer altijd op naam van het specifieke contrastmiddel en dit moet alleen gedaan worden door artsen of allergologen met ervaring op het gebied van contrastmiddelen.

Registreer het volgende na elke overgevoeligheidsreactie op contrastmiddelen:

- De plaats, datum en tijd van de contrast toediening - in het verslag van de beeldvorming en in het elektronisch patiëntendossier.
- De naam en dosis (volume, concentratie) van het specifieke contrastmiddel - in het verslag van de beeldvorming en in het elektronisch patiëntendossier.
- Het type overgevoeligheidsreactie, acuut of laat - in het verslag van de beeldvorming en in het elektronisch patiëntendossier.
- Alle symptomen en vitale parameters (bloeddruk, pols, ademsnelheid, zuurstof saturatie) van de patiënt - in het verslag van de beeldvorming en in het elektronisch patiëntendossier.
- De behandeling die werd gegeven en de respons van de patiënt daarop - in het verslag van de beeldvorming en in het elektronisch patiëntendossier.
- Gegevens van klinische follow-up en adviezen voor toekomstige premedicatie - in het verslag van de beeldvorming en in het elektronisch patiëntendossier.
- Gegevens over consultatie van een allergoloog over toekomstige contrastmiddeltoediening - in het elektronisch patiëntendossier.

Wanneer het om een ernstige of ongebruikelijke hypersensitiviteitsreactie gaat is de arts die verantwoordelijk is voor toediening van het contrastmiddel ook verantwoordelijk voor accurate rapportering naar de nationale farmacologie-autoriteit LAREB.

## **Hoofdstuk 8 Analytische Interferentie van contrastmiddelen met klinische laboratoriumtesten**

### **Klinische vraag**

Hoe kunnen contrastmiddelen interferentie geven op vaak toegepaste laboratorium testen?

- 1 Interferentie door jodiumhoudende contrastmiddelen
- 2 Interferentie door gadoliniumhoudende contrastmiddelen

### **Aanbevelingen**

## Bloedanalyse

Wees bewust dat een potentiële interferentie van contrastmiddelen op laboratoriumtesten bestaat, en dat dit cruciaal is om onnodige work-up van patiënten te voorkomen.

Zoals bij alle laboratoriumtesten moeten de resultaten worden geïnterpreteerd in relatie tot de medische geschiedenis en het klinische onderzoek van de patiënt.

Consulteer de laboratoriumarts wanneer er discrepanties zijn tussen de klinische presentatie en de uitslagen van laboratoriumtesten.

Voer bloedonderzoeken uit voordat toediening van contrastmiddelen plaatsvindt of stel bloedonderzoek uit voor niet-spoedeisende klinische laboratoriumtesten voor een periode van\*:

- Tenminste 4 uur en optimaal 12 uur na toediening van contrastmiddelen bij patiënten met een normale nierfunctie (eGFR > 60 mL/min/1.73 m<sup>2</sup>)
- Tenminste 16 uur en optimaal 48 uur na toediening van contrastmiddelen bij patiënten met een gereduceerde nierfunctie (eGFR 30-60 mL/min/1.73 m<sup>2</sup>)
- Tenminste 60 uur en optimaal 168 uur na toediening van contrastmiddelen bij patiënten met een ernstig gereduceerde nierfunctie (eGFR < 30 mL/min/1.73 m<sup>2</sup>)

\* Zie ook [Hoofdstuk 5 Veilige tijdsintervallen tussen onderzoeken met contrastmiddeltoediening](#)

## Urine-analyse

Voer urineonderzoek uit voordat toediening van contrastmiddelen plaatsvindt of stel urineonderzoek uit voor niet-spoedeisende klinische laboratoriumtesten voor een periode van\*\*:

- Tenminste 24 uur na toediening van contrastmiddelen bij patiënten met een normale nierfunctie (eGFR > 60 mL/min/1.73 m<sup>2</sup>)
- Tenminste 48 uur na toediening van contrastmiddelen bij patiënten met een gereduceerde nierfunctie (eGFR 30-60 mL/min/1.73 m<sup>2</sup>)
- Tenminste 168 uur na toediening van contrastmiddelen bij patiënten met een ernstig gereduceerde nierfunctie (eGFR < 30 mL/min/1.73 m<sup>2</sup>)

\*\* Criteria zijn gebaseerd op bijna complete eliminatie van contrastmiddelen

## **Hoofdstuk 9 Gadoliniumdepositie in het lichaam na het gebruik van gadoliniumhoudend contrastmiddel**

### **Module 9.1 Gadoliniumdepositie in de hersenen en in het lichaam**

#### **Klinische vraag**

Wat is het effect van gadoliniumdepositie in de hersenen en in het lichaam?

#### **Aanbevelingen**

Op dit moment is er geen bewijs van klinische symptomen of schade door gadoliniumdepositie in de hersenen of het lichaam.

Zorg voor een strikte indicatie voor gadolinium-versterkt MRI en gebruik alleen EMA-goedgekeurde gadoliniumhoudende contrastmiddelen bij alle patiënten om potentiële gadoliniumdepositie te minimaliseren. \*

\*Zie ook [module 9.2 Strategieën voor dosisverlaging bij gadoliniumhoudende contrastmiddelen](#)

Deze richtlijnwerkgroep ondersteunt de door de ACR Committee on Drugs and Contrast Media gesuggereerde terminologie 'Symptoms Associated with Gadolinium Exposure' voor zelfgerapporteerde symptomen door patiënten.

## Module 9.2 Strategieën voor dosisverlaging van gadoliniumhoudende contrastmiddelen

### Klinische vraag

Op welke manier kan de dosis van gadoliniumhoudende contrastmiddelen worden geminimaliseerd zonder de diagnostische accuratesse te verminderen?

De volgende categorieën werden gedefinieerd:

- I Potentiële dosisreductiestrategieën voor neurobeeldvorming met gadoliniumhoudend contrastmiddel
- II Potentiële dosisreductiestrategieën voor cardiovasculaire beeldvorming met gadoliniumhoudend contrastmiddel
- III Potentiële dosisreductiestrategieën voor musculoskeletale beeldvorming met gadoliniumhoudend contrastmiddel
- IV Potentiële dosisreductiestrategieën voor abdominale beeldvorming met gadoliniumhoudend contrastmiddel
- V Potentiële dosisreductiestrategieën voor mammabeeldvorming met gadoliniumhoudend contrastmiddel

### Aanbevelingen

- I Potentiële dosisreductiestrategieën voor neurobeeldvorming met gadoliniumhoudend contrastmiddel

De resultaten van de LEADER-75 studie geven aan dat de dosis van gadoliniumhoudende contrastmiddelen (gadobutrol) kan worden gereduceerd tot 75% van de standaarddosering (0.075 mmol/kg lichaamsgewicht (equivalent aan 0.075 ml/kg lichaamsgewicht)) bij patiënten met verdenking op laesies in de hersenen.

Het gebruik van deep learning gebaseerde methoden voor dosisreductie van gadoliniumhoudende contrastmiddelen bij patiënten met verdenking op laesies in de hersenen kan op basis van de huidige literatuur niet worden aanbevolen.

## II Potentiële dosisreductiestrategieën voor cardiovasculaire beeldvorming met gadoliniumhoudend contrastmiddel

Beeldvorming met standaarddosering wordt aanbevolen bij patiënten met klinische indicaties voor de toediening van gadoliniumhoudende contrastmiddelen bij cardiale MRI.

MRA-technieken zonder contrastmiddel (v.b. time-of-flight MRA) zijn op grote schaal beschikbaar en kunnen worden gebruikt voor accurate evaluatie van de graad van stenose van de supra-aortale vaten.

ECG-gated MRA sequenties zijn op grote schaal beschikbaar en worden aanbevolen in plaats van lage dosis contrastmiddel-versterkte MRA technieken voor de evaluatie van aorta dimensies.

## III Potentiële dosisreductiestrategieën voor musculoskeletale beeldvorming met gadoliniumhoudend contrastmiddel

Beeldvorming met standaarddosering wordt aanbevolen bij patiënten met klinische indicaties voor de toediening van gadoliniumhoudende contrastmiddelen bij musculoskeletale MRI.

## IV Potentiële dosisreductiestrategieën voor abdominale beeldvorming met gadoliniumhoudend contrastmiddel

### *Prostaat*

Er is toenemend bewijs dat biparametrische protocollen (T2w + DWI) zouden kunnen worden gebruikt als alternatief voor multiparametrische (T2w + DWI + DCE) protocollen voor de detectie van prostaatkanker.

### *Lever*

Beeldvorming met standaarddosering wordt aanbevolen bij patiënten met klinische indicaties voor de toediening van gadoliniumhoudende contrastmiddelen bij MRI van de lever.

## V Potentiële dosisreductiestrategieën voor mammabeeldvorming met gadoliniumhoudend contrastmiddel

Beeldvorming met standaarddosering wordt aanbevolen bij patiënten met klinische indicaties voor het toedienen van gadoliniumhoudende contrastmiddelen bij MRI van de mammae.

## Justification of the guideline

### Validity

The Radiological Society of the Netherlands (NVvR) will determine around 2027 if this guideline (per module) is still valid and applicable. If necessary, the scientific societies will form a new guideline group to revise the guideline. The validity of a guideline can be shorter than 5 years, if new scientific or healthcare structure developments arise, that could be a reason to commence revisions. The Radiological Society of the Netherlands is the owner of this guideline and thus primarily responsible for the actuality of the guideline. Other scientific societies that have participated in the guideline development share the responsibility to inform the primarily responsible scientific society about relevant developments in their field.

### Initiative

- Radiological Society of the Netherlands (NVvR)

### In association with

- Netherlands Association of Internal Medicine (NIV)
- The Dutch Association of Neurosurgery (NVvN)
- The Dutch Society of Allergology and Clinical Immunology (NVvAKI)
- The Dutch Society of Cardiology (NVVC)
- The Dutch Society of Clinical Chemistry and Laboratory Medicine (NVKC)
- The Dutch Society of Endocrinology (NVE)
- The Dutch Society of Neurology (NVN)
- The Dutch Society of Obstetrics and Gynaecology (NVOG)
- The Dutch Society of Surgery (NVvH) / The Dutch Society of Vascular Surgery (NVvV)

### General Information

The Kennisinstituut van de Federatie Medisch Specialisten ([www.kennisinstituut.nl](http://www.kennisinstituut.nl)) assisted the guideline development group. The guideline was financed by Stichting Kwaliteitsgelden Medisch Specialisten (SKMS) which is a quality fund for medical specialists in The Netherlands.

### Guideline development group (GDG)

A multidisciplinary guideline development group (GDG) was formed for the development of the guideline in 2020. The GDG consisted of representatives from all relevant medical specialization fields which were using intravascular contrast administration in their field.

All GDG members have been officially delegated for participation in the GDG by their scientific societies. The GDG has developed a guideline in the period from June 2020 until November 2022. The GDG is responsible for the complete text of this guideline.

## Conflicts of interest

The GDG members have provided written statements about (financially supported) relations with commercial companies, organisations or institutions that were related to the subject matter of the guideline. Furthermore, inquiries have been made regarding personal financial interests, interests due to personal relationships, interests related to reputation management, interest related to externally financed research and interests related to knowledge valorisation. The statements on conflict of interest can be requested from the administrative office of Kennisinstituut van de Federatie Medisch Specialisten (secretariaat@kennisinstituut.nl) and were summarised below.

<i>Last name</i>	<i>Function</i>	<i>Other positions</i>	<i>Personal financial interests</i>	<i>Personal relations</i>	<i>Reputation management</i>	<i>Externally financed research</i>	<i>Knowledge valorisation</i>	<i>Other interests</i>	<i>Signed</i>	<i>Actions</i>
<b>Dekkers IA</b>	Radiologist, LUMC	Clinical Epidemiologist  Member of contrast media safety committee, European Society of Urogenital Radiology (no payment)  Member, Gadolinium Research and Education Committee, European Society of Magnetic Resonance in Medicine, and Biology (no payment)	No	No	No	No	No	Received consultancy fees from Guerbet, 2019-2022	July 24 <sup>th</sup> , 2020, Reaffirmed October 12 <sup>th</sup> , 2022	No restrictions: received in part 3 of the guideline speaker fees, but this guideline does not mention specific medication, not of working mechanism, nor of side effects.
<b>Geenen RWF</b>	Radiologist, Noordwest ziekenhuisgroep /medisch	Member of contrast media safety committee,	No	No	No	No	No	No	April 11 <sup>th</sup> , 2020, Reaffirmed October 12 <sup>th</sup> , 2022	No restrictions



<i>Last name</i>	<i>Function</i>	<i>Other positions</i>	<i>Personal financial interests</i>	<i>Personal relations</i>	<i>Reputation management</i>	<i>Externally financed research</i>	<i>Knowledge valorisation</i>	<i>Other interests</i>	<i>Signed</i>	<i>Actions</i>
	specialisten Noordwest	European Society of Urogenital Radiology (no payment)								
<b>Houwen T, van der</b>	Internist - Immunologist - Allergologist, Amsterdam UMC, also seconded allergologist in Huid Medisch Centrum	None	None	None	None	None	None	None	July 11 <sup>th</sup> , 2022 Reaffirmed October 12 <sup>th</sup> , 2022	No restrictions
<b>Kerstens MN</b>	Internist-endocrinologist, UMCG	Chairman Bijniernet (no payment)	No	No	No	No	No	No	July 1 <sup>st</sup> , 2020, reaffirmed October 25 <sup>th</sup> , 2022	No restrictions
<b>Krabbe JG</b>	Clinical chemist, Medisch Spectrum Twente	No	No	No	No	No	No	No	September 1 <sup>st</sup> , 2020, Reaffirmed October 13 <sup>th</sup> , 2022	No restrictions
<b>Luijtgarden KM, van de</b>	Vascular surgeon, Maasland Ziekenhuis	No	No	No	No	No	No	No	August 1 <sup>st</sup> , 2020, reaffirmed October 26 <sup>th</sup> , 2022	No restrictions
<b>Molen AJ, van der</b>	Radiologist LUMC	Member of contrast media safety committee, European Society of Urogenital Radiology (no payment)	No	No	No	No	No	Received consultancy fees from Guerbet, 2019-2022	July, 24 <sup>th</sup> , 2020 Reaffirmed October 12 <sup>th</sup> , 2022	No restrictions: received in part 3 of the guideline speaker fees, but this guideline does not mention specific

<i>Last name</i>	<i>Function</i>	<i>Other positions</i>	<i>Personal financial interests</i>	<i>Personal relations</i>	<i>Reputation management</i>	<i>Externally financed research</i>	<i>Knowledge valorisation</i>	<i>Other interests</i>	<i>Signed</i>	<i>Actions</i>
		Member, Gadolinium Research and Education Committee, European Society of Magnetic Resonance in Medicine, and Biology (no payment)								medication, not of working mechanism, nor of side effects.
<b>Rossius MJP</b>	Radiologist Erasmus Medical Centre	Medical coordinator (no payment)	No	No	No	No	No	No	April 7 <sup>th</sup> , 2020, Reaffirmed October 13 <sup>th</sup> , 2022	No restrictions
<b>Uyttenboogaart M</b>	Neurologist and neuro-interventionalist UMCG	Advisor International Federation of Orthopaedic Manipulative Physical Therapist / Nederlandse Vereniging Manuele Therapie	No	No	Subsidy Hart Stichting for CONTRAST (Consortium of New Treatments in Acute Stroke): WP8 Stroke logistics and Epidemiology: financing of 2 PhD students by the Hart Stichting / PPS Allowance	Work package leader CONTRAST (Consortium of New Treatments in Acute Stroke): WP8 Stroke logistics and Epidemiology	No	No	June 30 <sup>th</sup> , 2020, reaffirmed October 26 <sup>th</sup> , 2022	No restrictions: the CONTRAST consortium wp8 is only about organisation and treatment of stroke. Stroke is not in this guideline.
<b>Ven AAJM, van de</b>	Internist-allergologist-immunologist, UMCG	Education and research related to work as internist-allergist	No	No	No	No	No	No	April 7 <sup>th</sup> , 2020, Reaffirmed October 19 <sup>th</sup> , 2022	No restrictions

<i>Last name</i>	<i>Function</i>	<i>Other positions</i>	<i>Personal financial interests</i>	<i>Personal relations</i>	<i>Reputation management</i>	<i>Externally financed research</i>	<i>Knowledge valorisation</i>	<i>Other interests</i>	<i>Signed</i>	<i>Actions</i>
<i>Wolk S, van der</i>	Gynaecologist-obstetrist, Haga Ziekenhuis	No	No	No	No	No	No	No	June 30 <sup>th</sup> , 2021, reaffirmed October 25 <sup>th</sup> , 2022	No restrictions

### **Input of patient's perspective**

The guideline does not address a specific adult patient group, but a diverse set of diagnoses. Therefore, it was decided to invite a broad spectrum of patient organisations for the stakeholder consultation. The stakeholder consultation was performed at the beginning of the process for feedbacking on the framework of subjects and clinical questions addressed in the guideline, and during the commentary phase to provide feedback on the concept guideline. The list of organisations which were invited for the stakeholder consultation can be requested from the Kennisinstituut van de Federatie Medisch Specialisten ([secretariaat@kennisinstituut.nl](mailto:secretariaat@kennisinstituut.nl)). In addition, patient information on safe use of contrast media in pregnancy and lactation was developed for Thuisarts.nl, a platform to inform patients about health and disease.

### **Implementation**

During different phases of guideline development, implementation and practical enforceability of the guideline were considered. The factors that could facilitate or hinder the introduction of the guideline in clinical practice have been explicitly considered. The implementation plan can be found in the 'Appendices to modules'. Furthermore, quality indicators were developed to enhance the implementation of the guideline. The indicators can also be found in the 'Appendices to modules'.

### **Methodology**

#### AGREE

This guideline has been developed conforming to the requirements of the report of Guidelines for Medical Specialists 2.0 by the advisory committee of the Quality Counsel ([www.kwaliteitskoepel.nl](http://www.kwaliteitskoepel.nl)). This report is based on the AGREE II instrument (Appraisal of Guidelines for Research & Evaluation II) ([www.agreetrust.org](http://www.agreetrust.org)), a broadly accepted instrument in the international community and based on the national quality standards for guidelines: "Guidelines for guidelines" ([www.zorginstituutnederland.nl](http://www.zorginstituutnederland.nl)).

#### Identification of subject matter

During the initial phase of the guideline development, the GDG identified the relevant subject matter for the guideline. The framework is consisted of both new matters, which were not yet addressed in part 1 and 2 of the guideline, and an update of matters that were subject to modification (for example in case of new published literature). Furthermore, a stakeholder consultation was performed, where input on the framework was requested.

#### Clinical questions and outcomes

The outcome of the stakeholder consultation was discussed with the GDG, after which definitive clinical questions were formulated. Subsequently, the GDG formulated relevant outcome measures (both beneficial and harmful effects). The GDG rated the outcome measures as critical, important and of limited importance ([GRADE method](#)). Furthermore, where applicable, the GDG defined relevant clinical differences.

#### Search and select

For clinical questions, specific search strategies were formulated, and scientific articles published in several electronic databases were searched. First, the studies that potentially had the highest quality of research were reviewed. The GDG selected literature in pairs (independently of each other) based on the title and abstract. A second selection was performed by the methodological advisor based on full text. The databases used, selection criteria and number of included articles can be found in the modules, the search strategy in the appendix.

### Quality assessment of individual studies

Individual studies were systematically assessed, based on methodological quality criteria that were determined prior to the search. For systematic reviews, a combination of the AMSTAR checklist and PRISMA checklist was used. For RCTs the Cochrane risk of bias tool and suggestions by the CLARITY Group at McMaster University were used, and for cohort studies/observational studies the risk of bias tool by the CLARITY Group at McMaster University was used. The risk of bias tables can be found in the separate document Appendices to modules.

### Summary of literature

The relevant research findings of all selected articles were shown in evidence tables. The evidence tables can be found in the separate document Appendices to modules. The most important findings in literature were described in literature summaries. When there were enough similarities between studies, the study data were pooled.

### Grading quality of evidence and strength of recommendations

The strength of the conclusions of the included studies was determined using the GRADE-method. GRADE stands for Grading Recommendations Assessment, Development and Evaluation (see <http://www.gradeworkinggroup.org>) (Atkins, 2004). GRADE defines four levels for the quality of scientific evidence: high, moderate, low, or very low. These levels provide information about the certainty level of the literature conclusions (<http://www.guidelinedevelopment.org/handbook>).

The evidence was summarized in the literature analysis, followed by one or more conclusions, drawn from the body of evidence. The level of evidence for the conclusions can be found above the conclusions. Aspects such as expertise of GDG members, local expertise, patient preferences, costs, availability of facilities and organisation of healthcare aspects are important to consider when formulating a recommendation. These aspects are discussed in the paragraph justifications. The recommendations provide an answer to the clinical question or help to increase awareness and were based on the available scientific evidence and the most relevant justifications.

### Appendices

Internal (meant for use by scientific society or its members) quality indicators were developed with the guideline and can be found in the separate document Appendices to modules. In most cases, indicators were not applicable. For most questions, additional scientific research on the subject is warranted. Therefore, the GDG formulated knowledge gaps to aid in future research, which can be found in the separate document Appendices to modules.

### **Commentary and authorisation phase**

The concept guideline was subjected to commentaries by the involved scientific societies. The list of parties that participated in the commentary phase can be requested from the Kennisinstituut van de Federatie Medisch Specialisten ([secretariaat@kennisinstituut.nl](mailto:secretariaat@kennisinstituut.nl)). The commentaries were collected and discussed with the GDG. The feedback was used to improve the guideline; afterwards the GDG made the guideline definitive. The final version of the guideline was offered to the involved scientific societies for authorization and was authorized.

## Literature

- Brouwers MC, Kho ME, Browman GP, et al. AGREE Next Steps Consortium. AGREE II: advancing guideline development, reporting and evaluation in health care. *CMAJ*. 2010; 182(18): E839-E842.
- Medisch Specialistische Richtlijnen 2.0. Adviescommissie Richtlijnen van de Raad Kwaliteit, 2012. Available at: [\[URL\]](#).
- Schünemann H, Brožek J, Guyatt G, et al. GRADE handbook for grading quality of evidence and strength of recommendations. Updated October 2013. The GRADE Working Group, 2013. Available at: [\[URL\]](#).
- Schünemann HJ, Oxman AD, Brozek J, et al. Grading quality of evidence and strength of recommendations for diagnostic tests and strategies. *BMJ*. 2008;336(7653):1106-1110. Erratum published in: *BMJ* 2008;336(7654).
- Ontwikkeling van Medisch Specialistische Richtlijnen: stappenplan. Kennisinstituut van Medisch Specialisten, 2020.

# Chapter 1 Prevention of Iodine-Induced Hyperthyroidism after Iodine-Based Contrast Media Administration

## Clinical question

What are strategies for the prevention of iodine-induced thyroid dysfunction in:

- Patients with a history of cardiovascular disease and/or more than 65 years old
- Patients with a history of thyroid problems (goitre, hyperthyroidism, hypothyroidism)
- Patients who receive radioactive iodine treatment of the thyroid

## Introduction

Iodine-based contrast media contain substantial amounts of iodine which might result in iodine-induced hyperthyroidism (IIHT) or iodine-induced hypothyroidism. Depending on the magnitude of this risk and the clinical implications, prophylactic medication could be considered.

## Search and select

A systematic review of the literature was performed to answer the following question: What are strategies for the prevention of IIHT, with a special interest in patients described above.

- P (Patient):** Patients with an indication of ICM administration with a special interest for the subgroups described above.
- I (Intervention):** Prevention strategy for IIHT: methimazole (synonym: thiamazole), propylthiouracil, perchlorate.
- C (Comparison):** No prevention strategy for IIHT or different prevention strategy.
- O (Outcomes):** Iodine-induced hyperthyroidism, iodine-induced hypothyroidism.

## Relevant outcome measures

The guideline development group considered iodine-induced hyperthyroidism (IIHT) as a critical outcome measure for decision making, and iodine-induced hypothyroidism as important outcome measures for decision making.

The working group defined the outcome measures as follows: iodine-induced hyperthyroidism is the clinical condition of hyperthyroidism (e.g., palpitations, tremulousness, heat intolerance) caused by iodinated contrast media, which usually occurs weeks or months after its administration (Bednarczuk, 2021; Bervini, 2021). Iodine-induced hypothyroidism is the clinical condition of hypothyroidism (e.g., fatigue, weight gain, cold intolerance) caused by iodinated contrast media, which usually occurs weeks or months after its administration. Both iodinated contrast media induced hyperthyroidism and hypothyroidism are usually self-limiting conditions and resolve within weeks to months.

The working group did not define a minimal clinically important difference beforehand, because it is unclear what the prevalence of IIHT is in the no-prevention-strategy group (control group) with risk factors for IIHT (the previously described groups at risk for IIHT). Because literature about the subject is scarce, it was decided to provide only a descriptive analysis.

## Search and select (Methods)

The databases Medline (via OVID) and Embase (via Embase.com) were searched with relevant search terms until July 7<sup>th</sup>, 2021. The detailed search strategy is depicted under the tab Methods. The systematic literature search resulted in 188 hits. Studies were selected based on the following criteria: studies with comparative design, comparing different prevention strategies for IIHT in the previously described subgroups. Forty-two studies were initially selected based on title and abstract screening. After reading the full text, forty studies were excluded (see Table of excluded studies in 'Appendices to modules'), and two studies were included.

## Results

Two studies were included in the analysis of the literature. Important study characteristics and results are summarized in the evidence tables. The assessment of the risk of bias is summarized in the risk of bias tables.

## **Summary of literature**

### Description of studies

#### ***Randomized controlled study***

Nolte et al. (1996) performed a prospective randomized study aiming to investigate the efficacy of prophylactic application of thyrostatic drugs in patients with subclinical hyperthyroidism undergoing elective coronary angiography. The authors screened patients for TSH who were admitted to the hospital for coronary angiography. Patients lived in an area of moderate iodine deficiency. Inclusion criteria were age between 40-75 years, TSH levels < 0.4 mU/L, normal FT<sub>3</sub>-index, normal FT<sub>4</sub>-index, and a normal <sup>99m</sup>Techetium-uptake. Those with manifest hyperthyroidism, large autonomous thyroid adenoma, immune related thyroid disease, urine iodine excretion > 200 µmol/mol creatinine, unstable angina pectoris or a Karnofsky Index < 50% were excluded. In addition, patients were also excluded if they were using thyroid hormones, thyrostatic drugs or amiodarone or had received contrast media during the previous 6 months. In total 51 patients fulfilled the criteria and were randomly assigned to one of three groups (17 patients in each group): group 1 received 20 mg of thiamazole once a day, group 2 was treated with 900 mg of sodium perchlorate (300mg 3 times a day) and group 3 received no special therapy. The treatment started 1 day before coronary angiography and lasted for 14 days. During angiography, patients were exposed to a mean contrast volume of 149ml, ranging from 50 to 410 ml. The three groups were comparable in age, sex, mean volume of contrast and goitre size. There were no side effects reported from the thyrostatic drugs. Follow up assessment was done 30 days after coronary angiography. Nolte (1996) defined IIHT as suppressed TSH (<0.4 mU/l) and increased FT<sub>4</sub>-index and/or FT<sub>3</sub>-index. Nolte (1996) defined iodine-induced hypothyroidism as increased TSH and reduced FT<sub>4</sub>-index 30 days after coronary angiography.

#### ***Prospective interventional study***

Fricke et al. (2004) performed a prospective study that had the objective to identify which patients with subclinical hyperthyroidism should receive prophylactic medication before coronary angiography to prevent IIHT. The authors screened all patients admitted for coronary angiography and included all patients with a basal TSH level of less than 0.3 mU/l and normal levels of T<sub>3</sub> and FT<sub>4</sub>. Patients with thyroid antibodies or using medication for thyroid disease were excluded. Additional exclusion criteria were use of amiodarone, renal insufficiency (serum creatinine >133 µmol/l) or administration of contrast agents during the previous 3 months. Indication for prophylactic drug treatment was determined by the TSH level and the results of <sup>99m</sup>Techetium scintigraphy. No prophylactic medication was given to patients with 1) homogenous tracer distribution in the thyroid, <sup>99m</sup>Techetium thyroid



uptake (TCTU) less than 1.5%, and TSH ranging from 0.05 to less than 0.3 mU/l; 2) homogenous tracer distribution in the thyroid, TCTU less than 1.0%, and TSH less than 0.05 mU/l; and 3) focal uptake and TCTU less than 1.0%. All other patients received 900 mg perchlorate (divided in 3 doses per day) for 2 weeks, starting at least 3 hours before coronary angiography. Thiamazole was added depending on the volume of the autonomous thyroid volume: 20 mg for 7 days in case of a volume of 5- 10 ml, and 60 mg thiamazole in the first week followed by 20 mg in the second week in case of a volume > 10 ml. Age was no selection criterion, mean age was 65±8.7 years. Coronary angiography was performed with an average of 157(±85 ml) iopromide containing 370 mg iodine per ml. In total 56 patients underwent coronary angiography without and 19 patients with prophylactic medication, i.e., 6 patients perchlorate only and 13 patients perchlorate combined with thiamazole. Follow up assessment was done at 1, 14, and 28 days after coronary angiography. This paper did not specifically define IIHT.

## Results

Results will be described separately for the previously described subgroups.

### *1. Iodine-induced hyperthyroidism (IIHT)*

The prospective randomized controlled study by Nolte (1996) reported one case of IIHT in the thiamazole group (1/17), one case in the perchlorate group (1/17), and two cases in the control group (2/17). Thyroid hormone levels were only slightly elevated in all cases. Only two persons developed mild clinical symptoms of hyperthyroidism, one in the thiamazole group and one in the perchlorate group, but none of these needed treatment with thyrostatic drugs.

The prospective interventional study by Fricke (2004) reported two cases of IIHT in the group receiving prophylactic drug treatment (2/19). In one case prophylactic drug treatment had to be stopped because of side effects, which was followed by development of hyperthyroidism. In the other case, the patient demonstrated mild hyperthyroidism the day after coronary angiography despite prophylactic treatment with perchlorate, which was stabilized within a few days with the administration of thiamazole (Fricke, 2004). There were no cases of IIHT in the group of 56 patients who did not receive prophylactic drug treatment.

### *TSH, thyroid hormones and <sup>99m</sup>Technetium-uptake*

The prospective randomized controlled study by Nolte (1996) measured TSH, delta TSH (response 30 min after 200µg of TRH i.v.), mean FT<sub>4</sub>-index, mean FT<sub>3</sub>-index and <sup>99m</sup>Technetium-uptake at baseline and after follow-up of 30 days. The authors reported a significant decrease in TSH and increase in FT<sub>4</sub>- and FT<sub>3</sub>-index in the control group, whereas these values remained unchanged in the intervention groups or showed a slight increase (TSH in the thiamazole group). Alterations of <sup>99m</sup>Technetium-uptake were minimal in both intervention groups but was significantly reduced in the control group after 30 days.

### *TSH and free thyroxine*

The prospective interventional study by Fricke (2004) reported TSH, FT<sub>4</sub> and T<sub>3</sub> at baseline and at 1, 14 and 28 days after coronary angiography. Within the group receiving prophylactic treatment (n=19), two cases of hyperthyroidism occurred. One patient developed IIHT after interruption of the prophylactic treatment because of side effects. The other patient demonstrated mild IIHT the day after ICM administration despite prophylactic treatment with perchlorate, which was quickly resolved after addition of thiamazole. The remaining 17 patients in the prophylactic treatment group showed stable TSH and T<sub>3</sub> levels, except for a slight TSH increase and T<sub>3</sub> decrease at day 28. In this group, FT<sub>4</sub> was slightly elevated at day

14 and slightly decreased at day 28. The group without prophylactic treatment (n=56) showed an increase of TSH at day 1 and day 14, with an increase of FT4 day 14 and day 28 and a transient decrease in T3 at day 1. All changes in TSH, FT4 and T3 were within the reference range.

## 2. Iodine induced hypothyroidism

The prospective randomized study by Nolte (1996) found no cases of iodine-induced hypothyroidism 30 days after coronary angiography. Fricke (2004) did not report this outcome measure.

### Level of evidence of the literature

Observational studies start at a low GRADE. Note: interventional studies.

The level of evidence regarding the outcome measure IIHT started on a low GRADE and was further downgraded to a very low GRADE levels because of study limitations (risk of bias) and the number of included patients (imprecision).

## Conclusions

<b>Very low GRADE</b>	<p>The evidence is very uncertain about the effect of prophylactic drugs on the prevention of IIHT in patients with indication for iodinated contrast media administration and</p> <ul style="list-style-type: none"> <li>- from a low iodine area (very low GRADE).</li> <li>- with thyroid disease (very low GRADE).</li> </ul> <p><i>Fricke, 2004; Nolte, 1996</i></p>
-----------------------	---

## Justifications – evidence to decision

Iodine-based contrast medium (ICM) is administered during a CT-scan in volumes of 60-150 ml with iodine concentrations of 270-400 mg iodine (mgI) per ml. The total iodine dose of the ICM with organically bound iodine that is administered is between 16,000 and 60,000 mgI. Since ICM are excreted unchanged in the urine and are not metabolized, this iodine load will not be available to the thyroid. More important is that bottles of ICM contain small amounts of inorganic free iodide, depending on shelf-life and exposure to light, which might be directly available for thyroid uptake. Concentrations are in the range of 0,002-0,03 mgI/ml and as a result, an amount of approximately 0.1-4.5 mgI free iodide will be injected (0,001-0,007% of the amount of injected organically bound iodine) (Rendl, 2001; van der Molen, 2004). This amount is about 1-30 times the recommended daily allowance for iodine of 150 µg. A recent study, however, showed no increased levels of free iodide in the thyroid glands of ICM-treated animals (Hichri, 2020).

In a nested case-control study it was found that ICM exposure was associated with a risk of hyperthyroidism (defined as TSH < 0.1 mU/l; OR 2.50, 95%CI 1.06-5.93) and a risk of hypothyroidism (defined as TSH>10 mU/l; OR 3.05, 95%CI 1.07-8.72) (Rhee, 2012). In a recent meta-analysis, however, it was shown that the absolute risk of IIHT was very low with an estimated prevalence of 0.1% (95%CI 0.0-0.6%) (Bervini, 2021). IIHT develops when the normal response to excess iodine with acute inhibition of the organification of iodine (i.e., acute Wolff-Chaikoff effect), is impaired. Risk factors include nontoxic diffuse or nodular goiter, latent Graves' disease, and long-standing iodine deficiency.

The reported prevalence of overt iodine induced hypothyroidism ranges from 0-8.1% (Bednarczuk, 2021). It develops when the thyroid fails to escape from the acute Wolff-Chaikoff effect, which may occur in euthyroid patients with a wide variety of thyroid disorders such as previous Hashimoto's thyroiditis, Graves' disease, thyroiditis, or previous thyroid surgery (Lee, 2015). It should be noted that published studies on prevalence are highly heterogeneous with respect to background iodine intake, selection of patients with or without previous history of thyroid disease, sample size, type of radiological examination, definition of thyroid disease and follow-up period. There are several case reports of iodine-induced thyrotoxicosis describing complications such as atrial fibrillation, heart failure or even thyroid storm (See [Bednarczuk 2021, Table 2](#)).

The efficacy of prophylactic treatment for development of iodine-induced hyperthyroidism has not been convincingly demonstrated. The randomised study by Nolte (Nolte, 1996) did not show a reduction of IIHT in the prophylactic treatment group, but that study was clearly underpowered. The study by Fricke (Fricke, 2004) was not randomised and compared two different subpopulations which were selected to receive prophylactic treatment or not based on TSH level and <sup>99m</sup>Tc thyroid uptake. Despite prophylactic treatment, two patients developed iodine induced hyperthyroidism. It should be noted, however, that the study by Fricke (2004) did not contain a comparable control group without prophylactic treatment.

The European Thyroid Association (ETA) has recently issued a guideline for the management of iodine-based contrast media-induced thyroid dysfunction (Bednarczuk, 2021). In view of the lack of well-designed studies in this field and to prevent conflicting statements as much as possible, we decided to adopt several of the ETA guideline recommendations. In view of the low incidence of iodine-induced thyroid dysfunction, the usually mild symptoms and the self-limiting clinical course, routine testing of the thyroid function is not indicated before ICM administration. Baseline testing of thyroid function might be considered in patients at risk for development of iodine induced hyperthyroidism with a complicated clinical course, i.e., patients older than 65 years with clinically severe cardiovascular morbidity (Bednarczuk, 2021). Overt hyperthyroidism is generally considered an absolute contraindication to ICM administration, and alternative imaging, like MRI or ultrasound, is then recommended. In emergency cases, prophylactic treatment should be initiated. Subclinical hyperthyroidism is not a contra-indication for ICM administration. In patients older than 65 years with severe cardiovascular morbidity and subclinical hyperthyroidism, prophylactic treatment might be considered. A more conservative approach would be to measure thyroid function (TSH, FT4) 3-4 weeks after ICM administration. A commonly used prophylactic treatment protocol is thiamazole 30 mg once daily, started the day before ICM administration and continued for 14 days. It has been suggested that combination with potassium perchlorate (500mg twice a day) would be more effective. Treatment with thiamazole is usually well tolerated. Adverse effects are predominantly skin allergy (maculopapular rash, urticaria) and arthralgias. The most important adverse effect of potassium/sodium perchlorate is agranulocytosis, but this is a rare event (about 1 in 275 patients) and occurs predominantly at daily dosages above 1000mg given for several months.

Baseline subclinical hypothyroidism and overt hypothyroidism are not a contraindication to ICM administration.

Yet another relevant question in clinical practice is the minimal interval required between ICM injection and isotope imaging of the thyroid or radioactive iodine (RAI) treatment. The administration of ICM is known to suppress thyroidal RAI uptake, lasting for several weeks (Nygaard, 1998). Some studies on urinary iodine secretion after ICM administration for outpatient CT scans indicate that 75% of patients' values returned to baseline within 5–6 weeks and 90% within 11 weeks (Lee 2015, Nimmons, 2013). A study performed in post-thyroidectomy patients requiring RAI treatment demonstrated that 1 month is sufficient for urinary iodine to return to its baseline value after the use of ICM (Padovani, 2012). These results may be used to guide the timing of RAI treatment as well as diagnostic scintigraphy with radioactive iodine or Tc-99m-pertechnetate following contrast exposure. The American Thyroid Association Management Guidelines for Adult Patients with Thyroid Nodules and Differentiated Thyroid Cancer (2015) state that concerns about iodine burden from IV contrast agents causing a clinically significant delay in subsequent whole-body scans or RAI treatment post-thyroidectomy is generally unfounded, as iodine is generally cleared within 4-8 weeks in most patients (Haugen, 2016). In doubtful situations, a spot or 24-h urinary iodine level may be checked before isotope studies. In line with the ETA guideline (Bednarczuk, 2021), we recommend postponing isotope imaging of the thyroid and RAI treatment for 4 to 8 weeks after ICM injection, or to withhold ICM administration 4 to 8 weeks before a planned RAI treatment.

### Recommendations

*In view of the low incidence of iodine induced thyroid dysfunction, the usually mild symptoms, and the self-limiting clinical course, routine testing of the thyroid function is not indicated before ICM administration. These recommendations are in line with the ETA guideline (Bednarczuk, 2021).*

Do not routinely measure the thyroid function before administration of iodine-based contrast media.

Consider measurement of thyroid function in high-risk patients for iodine-induced hyperthyroidism, especially in subjects older than 65 years and those with severe cardiovascular morbidity.

*In patients older than 65 years with severe cardiovascular morbidity and subclinical hyperthyroidism, prophylactic treatment might be considered. These recommendations are in line with the ETA guideline (Bednarczuk, 2021).*

Consider prophylactic treatment prescribed by an internal medicine specialist in selected patients with subclinical hyperthyroidism receiving iodine-based contrast media (e.g., patients older than 65 years or severe cardiovascular morbidity), starting one day before contrast administration and continuing for 14 days with thiamazole 30 mg once daily and possible addition of potassium perchlorate 500 mg twice daily.

*After ICM injection, the iodine uptake by the thyroid gland is temporarily suppressed. Therefore, isotope imaging of the thyroid or RAI should be postponed after ICM injection. These recommendations are in line with the ETA guideline (Bednarczuk, 2021).*

Avoid isotope imaging of the thyroid and/or radioactive iodine treatment for 4-8 weeks after iodine-based contrast media injection or withhold iodine-based contrast media administration for 4-8 weeks before planned isotope imaging of the thyroid or radioactive iodine treatment.

## Literature

- Bednarczuk T, Brix TH, Schima W, Zetting G, Kahaly GJ. 2021 European Thyroid Association guidelines for the management of iodine-based contrast media-induced thyroid dysfunction. *Eur Thyroid J.* 2021; 10(4): 269-284.
- Bervini S, Trelle S, Kopp P, Stettler C, Trepp R. Prevalence of iodine-induced hyperthyroidism after administration of iodinated contrast during radiographic procedures: A systematic review and meta-analysis of the literature. *Thyroid* 2021; 31: 1020-1029.
- Fricke E, Fricke H, Esdorn E, Kammeier A, Lindner O, Kleesiek K, Horstkotte D, Burchert W. Scintigraphy for risk stratification of iodine-induced thyrotoxicosis in patients receiving contrast agent for coronary angiography: a prospective study of patients with low thyrotropin. *J Clin Endocrinol Metab* 2004; 89(12): 6092-6096.
- Hichri M, Vassaux G, Guignon JM, Juhel T, Graslin F, Guglielmi J, et al. Proteomic analysis of iodinated contrast agent-induced perturbation of thyroid iodide uptake. *J Clin Med.* 2020; 9(2): 329.
- Lee SY, Rhee CM, Leung AM, Braverman LE, Brent GA, Pearce EN. A review: Radiographic iodinated contrast media-induced thyroid dysfunction. *J Clin Endocrinol Metab.* 2015; 100(2): 376-383.
- Nimmons GL, Funk GF, Graham MM, Pagedar NA. Urinary iodine excretion after contrast computed tomography scan: implications for radioactive iodine use. *JAMA Otolaryngol Head Neck Surg.* 2013; 139(5): 479-482.
- Nolte W, Müller R, Siggelkow H, Emrich D, Hüfner M. Prophylactic application of thyrostatic drugs during excessive iodine exposure in euthyroid patients with thyroid autonomy: a randomized study. *Eur J Endocrinol* 1996; 134(3): 337-341.
- Nygaard B, Nygaard T, Jensen LI, Court-Payen M, Sjøe-Jensen P, Nielsen KG, Fugl M, Hansen JM. Iohexol: effects on uptake of radioactive iodine in the thyroid and on thyroid function. *Acad Radiol.* 1998; 5(6): 409-414.
- Padovani RP, Kasamatsu TS, Nakabashi CC, Camacho CP, Andreoni DM, Malouf EZ, et al. One month is sufficient for urinary iodine to return to its baseline value after the use of water-soluble iodinated contrast agents in post-thyroidectomy patients requiring radioiodine therapy. *Thyroid.* 2012; 22(9): 926-930.
- Rendl J, Saller B. Schilddrüse und Röntgenkontrastmittel: Pathophysiologie, Häufigkeit und Prophylaxe der jodinduzierten Hyperthyreose. *Dt Arztebl* 2001; 98(7): A402-406.
- Rhee CM, Bhan I, Alexander EK, Brunelli SM. Association between iodinated contrast media exposure and incident hyperthyroidism and hypothyroidism. *Arch Intern Med* 2012; 172(2): 153-159.
- Van der Molen AJ, Thomsen HS, Morcos SK; Contrast Media Safety Committee, European Society of Urogenital Radiology (ESUR). Effect of iodinated contrast media on thyroid function in adults. *Eur Radiol* 2004; 14(5): 902-907.

## Chapter 2 Safe Use of Contrast Media during Pregnancy

### Clinical question

What is the safety profile of contrast media (iodine-based contrast media or gadolinium-based contrast agents) during pregnancy for mother and child?

### Introduction

Little is known about the safety of the use of contrast media (CM) in pregnant patients, both for the mother and the unborn child. Not only the caregiver but also the patients themselves have many questions about the safety of CM. The confusion about this safety can lead to avoidance of a potential crucial diagnostic test. Therefore, an updated search is highly needed.

### Search and select

A systematic review of the literature was performed to answer the following question: What are the effects of contrast media during pregnancy for mother and child regarding safety?

- P (Patients):** Pregnant women with indication for examination with contrast media.  
**I (Intervention):** Contrast media administration (iodine-based or gadolinium-based).  
**C (Comparison):** No contrast media administration or different contrast media administration.  
**O (Outcomes):** Foetal: congenital malformation (e.g., thyroid), maternal: adverse events.

### Relevant outcome measures

The guideline working group considered congenital malformations as a critical outcome measure for decision making.

A priori, the working group did not define the outcome measures listed above but used the definitions used in the studies.

The working group defined the presence of a congenital malformation as a minimal clinically (patient) important difference. Because of the severity of the outcome any statistically significant difference was considered as a clinically important difference between groups.

### Search and select (Methods)

The databases Medline (via OVID) and Embase (via Embase.com) were searched with relevant search terms from January 1<sup>st</sup>, 2000, until January 26<sup>th</sup>, 2021. The detailed search strategy is depicted under the tab Methods. The systematic literature search resulted in 507 hits. Studies were selected based on the following criteria:

- Original clinical studies or systematic reviews of original clinical studies; both randomized and observational studies were eligible
- Patient population consisted of pregnant patients
- The safety profile of contrast media administration regarding foetal congenital malformations was compared between women who received contrast media versus those who received no contrast media or a different contrast medium
- Iodine-based contrast media (ICM) or gadolinium-based contrast agent (GBCA)

Initially, thirty-one studies were selected based on title and abstract screening. After reading the full text, thirty studies were excluded (see Table of excluded studies in ‘Appendices to modules’) and one study was included.

### Results

One study (Rajaram, 2012) about iodine-based contrast media was included in the analysis of the literature. Important study characteristics and results are summarized in the evidence tables and the assessment of the risk of bias is summarized in the risk of bias tables (‘Appendices to modules’). Six studies were found that had the correct patient population and intervention group, but no control group, or no ICM or GBCA. These studies are briefly described in Table 2.1. Since the studies do not answer the search question, no quality of evidence analysis or evidence tables have been made for them.

### Description of studies

#### *Iodine-based contrast media*

Rajaram, 2012 performed a retrospective review of 115 pregnant patients investigated for suspected pulmonary embolism. The patient cohort consisted of two groups: Group A consisted of 73 pregnant females who received iodinated contrast agent for CT-pulmonary angiography (CTPA), and Group B (control group) consisted of 42 pregnant females who were investigated by perfusion imaging only. For group A, a maximum dose of 100 ml of non-ionic iodinated low-molecular-weight agent containing 300 mg/ml iopromide was used as a standard contrast agent. The gestational age at the time of contrast administration was in Group A (median 28 weeks, range 12-40) and Group B (median 29 weeks, range 7-38, p=0.30). The results of the neonatal thyroid function tests for the babies of the mothers in Groups A and B were compared. The blood samples for TSH levels were obtained from newborns by heel puncture test at the age of 5–8 days.

#### *Gadolinium-based contrast media*

No studies with a control group were found. Descriptive studies without control group can be found in Table 2.1.

### Results

#### *Iodine-based contrast media*

Rajaram (2012) reported that no significant difference was found in neonatal TSH values between the two groups (p=0.67). The average TSH value for group A, exposure to iodinated contrast agent, was 1.1 mIU/ml. The average TSH value for group B, no exposure to iodinated contrast agent, was 1.07 mIU/ml.

#### *Gadonium-based contrast media*

**Table 2.1: Brief description of studies that have the same patient population and intervention group as the search question, but no control group**

Study name	Patient population and number	Type of contrast medium	Results	Other remarks
Iodine-based contrast media				
Atwell, 2008	N=21 pregnant patients who underwent CT with iodinated IV contrast material	CT with iodinated IV contrast material (type was not further specified)	For all neonatal patients, serum TSH levels were normal. Mean serum TSH was 9.7	Author’s conclusion: Based on neonatal TSH measurements in a small number of patients, we found

	<p>between February 2000 and October 2006. Mean maternal age at the time of CT was 29 years (range, 19–41 years). Mean gestational age (based on last menstrual period) at the time of CT was 23 weeks (range, 8–37 weeks). Neonatal patients were born at a mean of 38 weeks of gestation (range, 24–41 weeks of gestation)</p>		<p>μIU/mL (range, 2.2–28.8 μIU/mL). No maternal patient reported thyroid problems in her child</p>	<p>no ill effect of iodinated contrast agents on neonatal thyroid function after in utero exposure.</p> <p>Retrospective observational study.</p>
Bourjelly, 2010	<p>N=344 All pregnant women who underwent multidetector pulmonary computed tomographic angiography because they were suspected of having pulmonary embolism between 2004 and 2008 and new-borns resulting from the index pregnancy were included. Mean gestational age at the time of administration of the contrast material was 27.8 weeks 6 7.4.</p>	<p>Iohexol. The mean dose of total iodine administered was 45 000 mg/L 6 7321.</p>	<p>All new-borns had a normal T 4 level at birth; only one new-born had a transiently abnormal TSH level at birth, which normalized at day 6 of life. This new-born was born to a mother who had many drug exposures during pregnancy.</p>	<p>Author’s conclusion: A single, high-dose in utero exposure to water-soluble, low-osmolar, iodinated intravenous products, such as iohexol, is unlikely to have a clinically important effect on thyroid function at birth.</p> <p>Retrospective observational study.</p>
Kochi, 2012	<p>N=61 (64 neonates) pregnant women receiving iodinated contrast during a CT scan procedure, and their neonates. The mean age of mothers in this group was 27.6 years at the time that they underwent a CT scan procedure. The mean GA at the time of the procedure was 25.6 weeks. The</p>	<p>Iodinated contrast The mean amount of non-ionic radioiodine contrast material used was 103.5 mL of Ultravist 300, which is approximately equal to 30 g of iodine. The range was between 21 and 46 g of iodine.</p>	<p>The TSH and T4 levels for all neonates, except one in this group, were within the reference range of 0.5 to 6.0 KIU/mL for TSH and 7 to 14 Kg/dL for T4. One neonate had a T4 level of less than 6 Kg/dL and a normal TSH level. This patient was a preterm infant being born at the 25th week of gestational age who also</p>	<p>Author’s conclusion: This study concludes that there is no significant adverse clinical risk of thyroid function abnormalities to the foetus after IV iodinated contrast material to their mothers.</p> <p>Retrospective observational study.</p>



	<p>earliest GA was 8 weeks and the latest was 37 weeks. The mean GA at delivery was 37.5 weeks. Eight women had hypothyroidism.</p> <p>a control group of 6 pregnant patients that received an CT scan without iodinated contrast was included. <i>(Since the control group contained &lt;10 patients, this study was excluded from the literature analysis.)</i></p>		<p>developed respiratory distress syndrome and sepsis.</p>	
Gadolinium-based contrast agents				
De Santis, 2007	<p>N=26 Pregnant women exposed to gadopentetate dimeglumine in the periconceptional and first trimester period who had undergone an MRI owing to other clinical indications. Age: 31 ± 4 years The mean menstrual age at exposure was 29.78 days and 24/26 exposures were in the postconceptional period.</p>	<p>gadopentetate dimeglumine</p>	<p>Two pregnancies, exposed at 15 and 18 days of menstrual age were complicated by low-birth-weight infants (LBW) but without any neonatal complications. One congenital anomaly at birth in a baby that had two haemangiomas born at 38 weeks to a woman exposed at 31 days of menstrual age through an MRI for a pituitary adenoma.</p>	<p>Author's conclusion: In this prospective cohort study, we found no maternal or neonatal complications and only one congenital anomaly at birth.</p> <p>Prospective observational study.</p>
Spencer, 2000	<p>N=11 Women with symptomatic hydronephrosis during pregnancy (1) clinical features of loin pain in pregnancy as assessed by an obstetrician and urologist; (2) ipsilateral dilatation of the renal pelvis shown by routine abdominal sonography; and (3) informed</p>	<p>IV bolus of 0.1 mmol/kg of gadopentetate dimeglumine</p>	<p>There were no adverse obstetric or infant outcomes.</p>	<p>Author's conclusion: MR excretory urography is a promising technique which affords equivalent functional and additional anatomical information to isotope renography.</p> <p>Prospective study.</p>

	consent of the patient. 19–34 weeks of gestation. Patient age not reported.			
Ray, 2016	N= 397 exposed to gadolinium MRI and N=1 418 451 not exposed. Women with first trimester exposure to MRI.	Gadolinium-enhanced MRI during first trimester	“There were 7 stillbirths or neonatal deaths (17.6 per 1000) following gadolinium-enhancedMRI exposure (cohort 2) vs 9844 events (6.9 per 1000) in nonexposed women, an adjusted RR of 3.70 (95% CI, 1.55-8.85) and an adjusted risk difference of 47.5 per 1000 (95% CI, 9.7-138.2)”	Author’s conclusion: “Exposure to gadoliniumenhanced MRI at any gestation was not associated with a greater risk of congenital anomalies. Although the NSF-like outcome was extremely rare, gadolinium-enhanced MRI was associated with an adjusted HR of 1.36 for any rheumatological, inflammatory or infiltrative skin condition up to age 4 years, and an adjusted RR of 3.70 for stillbirth or neonatal death, albeit with just 7 events in the gadolinium MRI group.”

Level of evidence of the literature

*Iodine-based contrast media*

The level of evidence regarding the outcome measure thyroid function started as GRADE low due to the observational nature of the included study was downgraded by one level to very low due to the small number of included patients (imprecision).

*Gadolinium-based contrast agents*

No studies with a control group were found. Therefore, no evidence tables, risk of bias assessment and quality assessment were performed for the studies mentioned in Table 2.1.

**Conclusions**

*Iodine-based contrast media*

<b>Very low GRADE</b>	<p>Iodine-based contrast medium administration may have little to no effect on neonatal thyroid function when compared with no iodinated contrast medium administration in pregnant patients, but the evidence is very uncertain.</p> <p><i>Sources: Rajaram, 2012</i></p>
-----------------------	--

<b>No GRADE</b>	No evidence was found regarding the effect of iodine-based contrast medium administration on congenital defects other than thyroid function when compared with no iodine-based contrast medium administration in pregnant patients.
-----------------	---

#### *Gadolinium-based contrast agents*

<b>No GRADE</b>	No evidence was found regarding the effects of gadolinium-based contrast agent administration on congenital defects when compared with no contrast medium administration, or a different type of contrast medium administration in pregnant patients.
-----------------	---

#### **Justifications – evidence to decision**

The use of diagnostic imaging with contrast media (CM) in pregnant patients has always been a topic of debate. It is known that administered CM pass the placenta and enter the foetal circulation in small amounts, but due to lack of hard data on the possible side effects for the foetus, it is difficult to give a solid advice to pregnant patients. Several reviews and papers found in literature use the results of limited data and recommendations of other guidelines (Lin, 2007; Little, 2020; Puac, 2017; Tremblay, 2012; Wang, 2012).

So far, different animal studies reported no congenital malformations with the use of iodine-based contrast media (ICM) (Morisetti, 1994). There are some theoretical concerns that free iodide can cause damage to the foetal thyroid gland (Webb, 2005).

With our search, only one comparative study was included for ICM. In this study no evidence was found that the administration of ICM caused congenital abnormalities or influenced the neonatal thyroid function (Rajaram, 2012). Three other non-comparative studies which were excluded from our search because of missing control groups, but were described in table 2.1, also did not report any congenital abnormalities (Atwell, 2008; Bourjelly, 2010; Kochi, 2012). Based on these findings we found no evidence that ICM cause congenital abnormalities. However, the evidence is uncertain due to the limited data and design of the few studies. Recently, a systematic review (Van Welie, 2021) found the same results regarding ICM with CT. They conducted a systematic review regarding ICM and their effect in pre-conceptional and post-conceptional women and their new-borns. They found five retrospective cohort studies and one case report regarding ICM in CT which reported on 525 neonates. Based on these five cohort studies, they estimated the overall proportion of (transient) neonatal thyroid dysfunction after CT at 0.0% (95% CI: 0.0–0.02%  $I^2=0\%$ ).

Due to these limited data, other guidelines were also consulted:

Guidelines from the Contrast Media Safety Committee (CMSC) of the European Society of Urogenital Radiology (ESUR) state that ICM may be given to the pregnant patient and that neonatal thyroid function should be checked during the first week (ESUR, 2018).

The Manual on Contrast Media from the American College of Radiology (ACR) recommends not withholding the use of ICM in pregnant or potentially pregnant patients when it is needed for diagnostic purposes (ACR, 2022).

Guidelines on ICM of the Royal Australian and New Zealand College of Radiologists (RANZCR) state that infants born to women who received ICM while pregnant should have testing for neonatal hypothyroidism (RANZCR, 2021).

Guidelines from The American College of Obstetricians and Gynaecologists (ACOG) state that ICM should only be used if absolutely required to obtain additional diagnostic information that will affect the care of the foetus or woman during the pregnancy (ACOG, 2017).

With gadolinium-based contrast agents (GBCA), animal studies have reported teratogenic effects only when administered in high and repeated doses (Chen, 2008; Novak, 1993; Okuda, 1999). Free gadolinium is toxic, and it is presumed that in high and repeated doses, gadolinium dissociates from its chelation agent. In humans, it is uncertain what the exact risk of gadolinium can be due to the unknown duration of exposure. When CM pass the placenta, it enters the foetal circulation and amniotic fluid. There, it re-enters the circulation due to swallowing of the amniotic fluid by the foetus. Therefore, the exact duration of foetal exposure to gadolinium is not known. The longer it remains in the amniotic fluid, the higher the risk of dissociation and exposure to free gadolinium.

No comparative studies were included with the use of GBCA. Two non-comparative studies shown in table 2.1, reported no adverse outcomes with the use of GBCA (De Santis, 2007; Spencer, 2000). In addition, Ray et al. (Ray 2016), performed a large retrospective study, evaluating the long-term safety of MRI exposure in pregnancy. They identified all births after 20 weeks of gestation in Ontario, Canada, from 2003 to 2015. Women exposed during first trimester of pregnancy to MRI and women exposed later in pregnancy were separately analysed. These were compared to women that were not exposed to MRI and had also no indication for MRI. For this reason, the study was excluded from the literature analysis. Exposure to MRI during the first trimester of pregnancy (n=1.737), compared with non-exposure (n= 1.418.451), was not associated with increased risk of harm to the foetus. Stillbirths and neonatal deaths occurred among 7/397 (2%) MRI-exposed with gadolinium vs. 9844/1.418.451 (1%) unexposed pregnancies (adjusted RR, 3.70; 95% CI, 1.55 to 8.85) for an adjusted risk difference of 47.5 per 1000 pregnancies (95% CI, 9.7 to 138.2). They also found a significantly increased risk of a broad set of rheumatological, inflammatory, or infiltrative skin conditions. So far, this study is the only longitudinal cohort study with a significant sample size. However, limitations of this study for assessing the risk of gadolinium-based contrast agents are the unavailability of MRI indications of the exposed cohort, a bias towards linear GBCA, a low follow-up rate, no trimester subset analysis, and the lack of a comparable control group with indication for (non-contrast) MRI (Little, 2020; Lum, 2020).

In contrast, a very recent retrospective cohort study (published after our literature search) compared 782 pregnancies that were exposed to MRI with GBCA to 5,209 pregnancies that were exposed to MRI without GBCA out of a population of > 11 million Medicaid-covered pregnancies. The primary endpoint was foetal/neonatal death, and the second endpoint was the infant neonatal intensive care unit admission rate. In both groups the percentage of foetal/neonatal death was 1,4%, with an adjusted relative risk of 0.73 (95% CI 0.34-1.55). The percentage of infants with a neonatal intensive care unit admission was 7.7% in the GBCA and 8.8% in the non-GBCA group, with an adjusted relative risk of 1.03 (95% CI 0.76-1.39). These results were considered reassuring for fatal and severe acute effects of GBCA administration during pregnancy, but subacute effects were not studied (Winterstein, 2022).

We also consulted other guidelines for their recommendations concerning GBCA: Guidelines from the CMSC of ESUR state when there is a strong indication for CE MRI, the smallest possible dose of a macrocyclic GBCA may be given to a pregnant female (ESUR, 2018; Webb, 2005 and 2013).

Guidelines from the Royal College of Radiology (RCR) state that GBCA should not be used during pregnancy unless the clinical condition of the patient makes their use absolutely necessary (RCR, 2019).

Guidelines from the ACR state that because it is unclear how GBCA will affect the foetus, these agents should be used with caution to pregnant or potentially pregnant patients. GBCA should only be used if their usage is considered critical and the potential benefits justify the potential unknown risk to the foetus (ACR, 2022).

Guidelines from the ACOG state that the use of GBCA with MRI should be limited. It may be used as a contrast agent in a pregnant woman only if it significantly improves diagnostic performance and is expected to improve foetal or maternal outcome (ACOG, 2021).

Guidelines from the Canadian Association of Radiologists on MRI do not recommend GBCA administration unless absolutely necessary (Jabehdar Maralani, 2022).

Based on our search and the advice from other guidelines, we made recommendations for the use of ICM and GBCA separately. Regarding our second clinical question, no recommendations could be made. None of studies regarding ICM made a distinction in gestational age. For GBCA, only a few studies focussed on the first trimester or women who did not know they were pregnant (Bird, 2019; De Santis, 2007). Their recommendations are like the overall recommendations. The guidelines which are mentioned earlier, also do not have recommendations for specific trimesters. The ACR has a separate document about imaging in potentially pregnant patients, but this document does not address the use of CM. Therefore, a recommendation about a specific trimester cannot be made and our recommendations will be for pregnancy in general.

## Recommendations

*Our recommendation for the use of ICM is in line with the guidelines mentioned above. A discussion of the theoretical potential risks and benefits of the use of ICM should take place but a pregnant patient should not be denied a diagnostic test when it is needed. Because of the heel prick screening test, extra testing of the thyroid is not necessary.*

Do not withhold a pregnant patient from imaging with iodine-based contrast media when medically indicated.

*Although no adverse outcomes were reported in the two studies mentioned in table 2.1, our recommendation regarding the use of GBCA is in line with other guidelines. The recommendation is based on the study of Ray et al (2016) and the potential teratogenic risks found in animal data.*

Be cautious with gadolinium-based contrast agents due to potential risks to the foetus. Only use contrast agents when the benefits clearly outweigh the possible risks.

## Knowledge gaps

What is the safety profile of contrast media during pregnancy for mother and child (with subgroups for different trimesters)? For clear ethical reasons, only preclinical data is available.

## Literature

- American College of Radiology. ACR Manual on contrast media, v2022. Available at: [\[URL\]](#)  
Accessed: 17 April 2022.
- American College of Obstetricians and Gynecologists. Committee Opinion 723: ACOG Guidelines for diagnostic imaging during pregnancy and lactation, 2017. *Obstet Gynecol.* 2017; 130(4): e210-e216. Available at: [\[URL\]](#) Accessed: 17 April 2022.
- Atwell TD, Lteif AN, Brown DL, McCann M, Townsend JE, Leroy AJ. Neonatal thyroid function after administration of IV iodinated contrast agent to 21 pregnant patients. *AJR Am J Roentgenol.* 2008; 191(1): 268-271.
- Bird ST, Gelperin K, Sahin L, Bleich KB, Fazio-Eynullayeva E, Woods C, Radden E, Greene P, McCloskey C, Johnson T, Shinde M, Krefting I. First-trimester exposure to gadolinium-based contrast agents: a utilization study of 4.6 million U.S. pregnancies. *Radiology.* 2019; 293(1): 193-200.
- Bourjeily G, Chalhoub M, Phornphutkul C, Alleyne TC, Woodfield CA, Chen KK. Neonatal thyroid function: effect of a single exposure to iodinated contrast medium in utero. *Radiology.* 2010; 256(3): 744-750.
- Chen MM, Coakley FV, Kaimal A, Laros RK Jr. Guidelines for computed tomography and magnetic resonance imaging use during pregnancy and lactation. *Obstet Gynecol.* 2008; 112(2 Pt 1): 333-340.
- De Santis M, Straface G, Cavaliere AF, Carducci B, Caruso A. Gadolinium periconceptual exposure: pregnancy and neonatal outcome. *Acta Obstet Gynecol Scand.* 2007; 86(1): 99-101.
- European Society of Urogenital Radiology Contrast Media Safety Committee. ESUR Guidelines on contrast safety, v10. 2018. Available at: [\[URL\]](#) Accessed: 17 April 2022.
- Han BH, Lee KS, Han JY, Choi JS, Ahn HK, Ryu HM, Yang JH, Han HW, Nava-Ocampo AA. Pregnancy outcome after 1st-trimester inadvertent exposure to barium sulphate as a contrast media for upper gastrointestinal tract radiography. *J Obstet Gynaecol.* 2011; 31(7): 586-588.
- Jabehdar Maralani P, Kapadia A, Liu G, Moretti F, Ghandehari H, Clarke SE, Wiebe S, Garel J, Ertl-Wagner B, Hurrell C, Schieda N. Canadian Association of Radiologists recommendations for the safe use of MRI during pregnancy. *Can Assoc Radiol J.* 2022; 73(1): 56-67.
- Kochi MH, Kaloudis EV, Ahmed W, Moore WH. Effect of in utero exposure of iodinated intravenous contrast on neonatal thyroid function. *J Comput Assist Tomogr.* 2012; 36(2): 165-169.
- Lin SP, Brown JJ. MR contrast agents: physical and pharmacologic basics. *J Magn Reson Imaging.* 2007; 25(5): 884-899.
- Little JT, Bookwalter CA. Magnetic resonance safety: Pregnancy and lactation. *Magn Reson Imaging Clin N Am.* 2020; 28(4): 509-516.
- Lum M, Tsiouris AJ. MRI safety considerations during pregnancy. *Clin Imaging.* 2020; 62: 69-75.
- Morisetti A, Tirone P, Luzzani F, de Haën C. Toxicological safety assessment of iomeprol, a new X-ray contrast agent. *Eur J Radiol.* 1994; 18 (Suppl 1): S21-S31.
- Novak Z, Thurmond AS, Ross PL, Jones MK, Thornburg KL, Katzberg RW. Gadolinium-DTPA transplacental transfer and distribution in fetal tissue in rabbits. *Invest Radiol.* 1993; 28(9): 828-830.
- Okuda Y, Sagami F, Tirone P, Morisetti A, Bussi S, Masters RE. [Reproductive and developmental toxicity study of gadobenate dimeglumine formulation (E7155) (3)-- Study of embryo-fetal toxicity in rabbits by intravenous administration]. *J Toxicol Sci.* 1999; 24 (Suppl 1): 79-87.

- Puac P, Rodríguez A, Vallejo C, Zamora CA, Castillo M. Safety of contrast material use during pregnancy and lactation. *Magn Reson Imaging Clin N Am*. 2017; 25(4): 787-797.
- Rajaram S, Exley CE, Fairlie F, Matthews S. Effect of antenatal iodinated contrast agent on neonatal thyroid function. *Br J Radiol*. 2012; 85(1015): e238-e242.
- Royal Australian and New Zealand College of Radiologists. RANZCR Iodinated Contrast Guidelines, v2.3. 2018. Available at: [\[URL\]](#) Accessed: 17 April 2022.
- Ray JG, Vermeulen MJ, Bharatha A, Montanera WJ, Park AL. Association between MRI exposure during pregnancy and fetal and childhood outcomes. *JAMA*. 2016; 316(9): 952-961.
- Royal College of Radiologists. Guidance on gadolinium-based contrast agent administration to adult patients. April 2019. Available at: [\[URL\]](#). Accessed: 17 April 2022.
- Spencer JA, Tomlinson AJ, Weston MJ, Lloyd SN. Early report: comparison of breath-hold MR excretory urography, Doppler ultrasound, and isotope renography in evaluation of symptomatic hydronephrosis in pregnancy. *Clin Radiol*. 2000; 55(6): 446-453.
- Tremblay E, Therasse E, Thomassin N et al. Quality Initiatives Guidelines for use of medical imaging during pregnancy and lactation. *Radiographics*. 2012; 32: 897-911.
- Van Welie N, Portela M, Dreyer K, Schoonmade LJ, van Wely M, Mol BWJ, van Trotsenburg ASP, Lambalk CB, Mijatovic V, Finken MJJ. Iodine contrast prior to or during pregnancy and neonatal thyroid function: a systematic review. *Eur J Endocrinol*. 2021; 184(1): 189-198.
- Wang PI, Chong ST, Kielar AZ. Imaging of pregnant and lactating patients: Part 1. Evidence-based review and recommendations. *AJR Am J Roentgenol* 2012; 198:778-784.
- Webb JA, Thomsen HS, Morcos SK; Members of Contrast Media Safety Committee of European Society of Urogenital Radiology (ESUR). The use of iodinated and gadolinium contrast media during pregnancy and lactation. *Eur Radiol*. 2005; 15(6): 1234-1240.
- Webb JA, Thomsen HS. Gadolinium contrast media during pregnancy and lactation. *Acta Radiol*. 2013; 54: 599-600.
- Winterstein AG, Thai TN, Nduguba S, Smolinski NE, Wang X, Sahin L, et al. Risk of fetal/neonatal death or neonatal intensive care unit admission associated with gadolinium magnetic resonance imaging exposure during pregnancy. *Am J Obstet Gynecol*. 2022 Oct 11:S0002-9378(22)00809-2. doi: 10.1016/j.ajog.2022.10.005.

## Chapter 3 Safe Use of Contrast Media during Lactation

### Clinical question

What is the safety profile of contrast media (iodine-based contrast media or gadolinium-based contrast agents) during the lactation period for mother and child?

### Introduction

The same questions about the use of contrast media (CM) in pregnancy arise in the puerperium, especially when breastfeeding. Questions arise from mothers, who are administered CM, whether these substances are safe for the new-born during the lactation period. This chapter is intended to provide recommendations regarding this topic.

### Search and select

A systematic review of the literature was performed to answer the following question: What are the effects of contrast media during the lactation period for mother and new-born regarding safety?

- P (Patients):** Lactating women with indication for examination with contrast media.  
**I (Intervention):** Contrast media administration.  
**C (Comparison):** No contrast media administration or administration of a different contrast medium.  
**O (Outcomes):** Neonatal adverse effects: gastrointestinal effects, hypersensitivity reactions, thyroid effects, maternal effects: percentage of contrast medium in breast milk, transition into breast milk.

### Relevant outcome measures

The guideline working group considered neonatal adverse effects (hypersensitivity reactions, gastrointestinal effects, thyroid effects) of CM in breast milk as crucial outcome measures for decision making; and maternal effects (the percentage of contrast medium in breast milk) as an important outcome measure for decision making.

A priori, the working group did not define the outcome measures listed above but used the definitions used in the studies.

The working group defined the presence of any neonatal adverse effect as a minimal clinically (patient) important difference. Because of the severity of the outcome any statistically significant difference was considered as a clinically important difference between groups.

### Search and select (Methods)

The databases Medline (via OVID) and Embase (via Embase.com) were searched with relevant search terms from January 1<sup>st</sup>, 2000, until January 26<sup>th</sup>, 2021. The detailed search strategy is depicted under the tab Methods. The systematic literature search resulted in 507 hits.

Studies were selected based on the following criteria:

- Original clinical studies or systematic reviews of original clinical studies; both randomized and observational studies were eligible.



- Patient population consisted of patients who were breastfeeding.
- The safety profile of contrast media administration regarding neonates' effects and percentage of contrast medium in breast milk was compared between women who received contrast media versus those who received no contrast media or a different contrast medium.

Thirty-one studies were initially selected based on title and abstract screening. After reading the full text, all studies were excluded (see Table of excluded studies in 'Appendices to modules').

### Results

No studies were included in the analysis of the literature, and therefore no systematic literature analysis was performed.

### **Justifications – evidence to decision**

Data from studies evaluating the safety of the use of contrast media (CM) in the lactation period are very limited (Böhm, 2020). Our search did not find any studies regarding lactation. Therefore, a recommendation based on findings of comparative studies cannot be made. However, we can make a recommendation based on the pharmacokinetics of CM and recommendations of other guidelines. Several reviews found in literature use pharmacokinetics and the results of limited animal studies. Most of their recommendations are also found in other guidelines (Cova, 2014; Lin, 2007; Puac, 2017; Tremblay, 2012; Wang, 2012).

When assessing the risk of CM in the lactation period, information of the excretion of these CM into breast milk and the absorption from the gastrointestinal tract of the new-born is needed. Iodine-based contrast media (ICM) and gadolinium-based contrast agents (GBCA) are water-soluble and therefore excreted in small amounts in breast milk, found in limited animal studies (Bourrinet, 1995; Lorusso, 1994; Okazaki, 1996). Human studies have stated the same, but numbers of patients are also very limited. These studies mention the excretion and later absorption of CM by the newborn, which are also mentioned in the guidelines from The American College of Radiology (ACR) and The American College of Obstetricians and Gynecologists (ACOG). They state that for ICM less than 1% of the administered maternal dose is excreted into breast milk in the first 24 hours. The absorption from the gastrointestinal tract in the newborn is 1%, making the systemic dose less than 0,01%. For GBCA, 0,04% of the administered maternal dose is excreted into breast milk. Combined with the 1% absorption, the systemic dose is less than 0,0004% (Kubik-Huch, 2007; Nielsen, 1987; Schmiedl, 1990; Tremblay, 2012; Wang, 2012; Webb 2005). Due to the small dose of CM in breast milk, these studies state that it is safe for both mother and newborn to continue breastfeeding after receiving CM. The ACR also states that the decision should be left up to the mother herself. If discontinuation of breastfeeding is wanted, 12-24 hours is enough (ACR, 2022).

The Contrast Media Safety Committee (CMSC) of the European Society of Urogenital Radiology (ESUR) guideline states that breastfeeding may be continued normally with ICM and GBCA (ESUR, 2018; Webb 2005 and 2013).

The guideline regarding GBCA of the Royal College of Radiology (RCR) states that, while no special precaution or cessation of breastfeeding is required, the continuation or cessation of breastfeeding for 24 hours should be at the discretion of the lactating mother in consultation with the clinician (RCR, 2019).

The guideline regarding ICM of the Royal Australian and New Zealand College of Radiologists (RANZCR) states that cessation of breastfeeding or expression and discarding of breast milk after ICM administration are not required (RANZCR, 2018).

The guideline on MRI in the obstetric patient of the Society of Obstetricians and Gynaecologists of Canada states that it is safe to continue breastfeeding after receiving GBCA (Patenaude, 2014).

## Recommendations

*Our recommendation is in line with other guidelines and the few available data. Due to the limited amount of excretion of CM in breast milk, breastfeeding can be continued without interruption when imaging with CM is needed. If women wish to discontinue, a discontinuation of 24 hours should be enough.*

Due to the limited amount of excretion into breast milk, the guideline development group believes it is safe to continue breastfeeding after administration of contrast media.

If patients wish to discontinue breastfeeding (shared decision making), a discontinuation of 24 hours is sufficient.

## Literature

- American College of Radiology. ACR Manual on contrast media, v2022. Available at: [\[URL\]](#). Accessed: 17 April 2022.
- American College of Obstetricians and Gynecologists. Committee Opinion 723: ACOG Guidelines for diagnostic imaging during pregnancy and lactation, 2017. *Obstet Gynecol.* 2017; 130(4): e210-e216. Available at: [\[URL\]](#) Accessed: 17 April 2022.
- Böhm I, Hungerbühler M. Excretion of iodinated contrast media in human breast milk: surprising results. *Eur J Radiol* 2020; 128: 109045
- Bourrinet P, Dencausse A, Havard P, Violas X, Bonnemain B. Transplacental passage and milk excretion of iobitridol. *Invest Radiol* 1995; 30(3):156–158.
- Cova MA, Stacul F, Quaranta R, Guastalla P, Salvatori G, Banderali G, Fonda C, David V, Gregori M, Zuppa AA, Davanzo R. Radiological contrast media in the breastfeeding woman: a position paper of the Italian Society of Radiology (SIRM), the Italian Society of Paediatrics (SIP), the Italian Society of Neonatology (SIN) and the Task Force on Breastfeeding, Ministry of Health, Italy. *Eur Radiol.* 2014; 24(8):2012-2022.
- European Society of Urogenital Radiology Contrast Media Safety Committee. ESUR Guidelines on contrast safety, v10. 2018. Available at: [\[URL\]](#). Accessed: 17 April 2022.
- Kubik-Huch RA, Gottstein Alame NM, Frenzel T et al. Gadopentetate diglumine excretion into human breast milk during lactation. *Radiology* 2000; 216: 555-558.
- Lin SP, Brown JJ. MR contrast agents: physical and pharmacologic basics. *J Magn Reson Imaging.* 2007; 25(5): 884-899.
- Lorusso V, Luzzani F, Bertani F, Tirone P, de Haën C. Pharmacokinetics and tissue distribution of iomeprol in animals. *Eur J Radiol* 1994; 18 (Suppl 1): S13-S20.
- Nielsen ST, Matheson I, Rasmussen JN, Skinnemoen K, Andrew E, Hafsaahl G. Excretion of iohexol and metrizoate in human breast milk. *Acta Radiol.* 1987; 28(5): 523-526.

- Okazaki O, Murayama N, Masubuchi N, Nomura H, Hokusui H. Placental transfer and milk secretion of gadodiamide injection in rats. *Arzneimittelforschung*. 1996; 46(1): 83-86.
- Patenaude Y, Pugash D, Lim K, Morin L; Diagnostic Imaging Committee, Lim K, Bly S, Butt K, Cargill Y, Davies G, Denis N, Hazlitt G, Morin L, Naud K, Ouellet A, Salem S; Society of Obstetricians and Gynaecologists of Canada. The use of magnetic resonance imaging in the obstetric patient. *J Obstet Gynaecol Can*. 2014; 36(4): 349-363.
- Puac P, Rodríguez A, Vallejo C, Zamora CA, Castillo M. Safety of contrast material use during pregnancy and lactation. *Magn Reson Imaging Clin N Am*. 2017; 25(4): 787-797.
- Royal Australian and New Zealand College of Radiologists. RANZCR Iodinated Contrast Guidelines, v2.3. 2018. Available at: [\[URL\]](#). Accessed: 17 April 2022.
- Royal College of Radiologists. RCR Guidance on gadolinium-based contrast agent administration to adult patients. April 2019. Available at: [\[URL\]](#). Accessed: 17 April 2022.
- Schmiedl U, Maravilla KR, Gerlach R, Dowling CA. Excretion of gadopentetate dimeglumine in human breast milk. *AJR Am J Roentgenol*. 1990; 154(6): 1305-1306.
- Tremblay E, Therasse E, Thomassin N et al. Quality Initiatives: Guidelines for use of medical imaging during pregnancy and lactation. *Radiographics*. 2012; 32: 897-911.
- Wang PI, Chong ST, Kielar AZ. Imaging of pregnant and lactating patients: Part 1. Evidence-based review and recommendations. *AJR Am J Roentgenol* 2012; 198: 778-784.
- Webb JA, Thomsen HS, Morcos SK; Members of Contrast Media Safety Committee of European Society of Urogenital Radiology (ESUR). The use of iodinated and gadolinium contrast media during pregnancy and lactation. *Eur Radiol*. 2005; 15(6): 1234-1244.
- Webb JA, Thomsen HS. Gadolinium contrast media during pregnancy and lactation. *Acta Radiol* 2013; 54: 599-600.

## Chapter 4 Safe use of Contrast Media in Patients with Rare Diseases

### Module 4.1 Safe Use of Contrast Media in Patients with Multiple Myeloma

#### Clinical question

Which prevention strategies are effective to prevent contrast-associated acute kidney injury (CA-AKI) in patients with multiple myeloma?

#### Introduction

Multiple myeloma (MM) is a plasma cell neoplasm accounting for 1.0-1.8% of all cancers. It represents the second most common haematological malignancy with an incidence in Europe of 4.5-6.0/100,000/year (Dimopoulos, 2021; Sprangers, 2018). It has been suggested that patients with multiple myeloma are more prone to develop contrast-associated acute kidney injury (CA-AKI) (synonymous with post-contrast acute kidney injury (PC-AKI)) than would be expected based on their renal function (LeBlanc, 2002). The question arises whether multiple myeloma represents a risk factor for CA-AKI, necessitating additional preventive measurements irrespective of the renal function.

#### Search and select

A systematic review of the literature was performed to answer the following question: What is the risk of contrast-associated acute kidney injury (CA-AKI), existing kidney injury after one month or the need for dialysis in multiple myeloma patients following administration of contrast media compared to patients without multiple myeloma?

- P (Patients):** Patients with multiple myeloma.  
**I (Intervention):** Administration of contrast media.  
**C (Comparison):** Patients without multiple myeloma.  
**O (Outcomes):** Contrast-associated acute kidney injury (CA-AKI), existing acute kidney injury after 1 month, need for dialysis

#### Relevant outcome measures

The guideline development group considered existing kidney injury after 1 month and the need for dialysis as critical outcome measures for decision making; and CA-AKI as important outcome measures for decision making.

#### Search and select (Methods)

The databases Medline (via OVID) and Embase (via Embase.com) were searched with relevant search terms until February 17<sup>th</sup>, 2021. The detailed search strategy is depicted under the tab Methods. The systematic literature search resulted in 124 hits. Studies were selected based on the following criteria: (1) patients with multiple myeloma (2) examination with contrast media (3) comparison to patients without multiple myeloma (if possible) and (4) one of the previously described outcomes. Fifteen studies were initially selected based on title and abstract screening. After reading the full text, fifteen studies were excluded (see Table of excluded studies in 'Appendices to modules') and no studies were included. One systematic review by Stacul (2018) and one retrospective cohort study by Crowley (2018) were found. These papers could not be included in the literature analysis because of the limited quality of the included studies and the lack of a comparable control group without

multiple myeloma or reference values. These two publications, however, will be described in more detail in the justifications, as they represent the best available evidence.

## Results

No studies were included in the literature analysis, and therefore, no systematic literature analysis was performed.

## Justifications – evidence to decision

The discussion whether multiple myeloma per se is an independent risk factor for contrast-associated acute kidney injury (CA-AKI) goes back as far as the early 1990s (McCarthy, 1992; Pahade, 2011). CA-AKI is synonymous with post-contrast acute kidney injury (PC-AKI) used in [part 1](#) and [part 2](#) of this guideline, but CA-AKI is currently more frequently used than PC-AKI for this condition.

### Pros and cons of the intervention and quality of the evidence

The systematic review belonging to the ESUR guideline (Stacul, 2018) and the retrospective cohort study by Crowley (2018) were excluded from the literature analysis because of limited study quality and the lack of a control group without multiple myeloma. Results will be discussed descriptively.

The systematic review for the ESUR guideline (Stacul, 2018) reported on CA-AKI in patients with multiple myeloma and monoclonal gammopathies. CA-AKI was defined as cases in which kidney injury could not be explained by other causes than contrast medium administration. Twelve cohort studies and one case control study were included, the majority uncontrolled and of limited quality (Newcastle-Ottawa scores of 5-6 out of a scale until 9). Reference values of a control group without multiple myeloma were not reported. High osmolality contrast media were used in eleven studies, whereas low osmolality contrast media were used in the remaining two studies. Many important variables were not reported such as the multiple myeloma description (subtype, stage, disease load), baseline serum creatinine and calcium concentration, or number of examinations per patient. In addition, existing kidney injury after one month and the need for dialysis were not reported. A total of 642 patients and 824 iodine-based CM administrations were studied.

Crowley et al. (Crowley, 2018) reported on CA-AKI in patients with multiple myeloma. The study was retrospective and carried out in a university hospital in Ireland using a medical record database to retrieve information. CA-AKI was defined as a > 25% increase or a rise of more than 44.2 mmol/L (0.5 mg/dL) in serum creatinine level above baseline level after receiving IV contrast material within three days of administration of contrast media. In contrast to the ESUR guideline (Stacul, 2018), characteristics of the multiple myeloma patients (demographics, subtype, stage, disease load), baseline serum creatinine and calcium concentration were described. The study was uncontrolled and of limited study quality. The type of contrast medium used was not described, patients on dialysis were excluded, and information on infection, hydration status or use of nephrotoxic drugs was not available. The study, however, did report on existing kidney failure after one month. In total 94 patients with multiple myeloma, including 165 procedures with contrast media, were available for analysis.

The incidence of CA-AKI will be described separately because of the different definitions of CA-AKI, different inclusion criteria and the inclusion of monoclonal gammopathies patients besides multiple myeloma patients (Stacul, 2018).

### CA-AKI

The reported CA-AKI case incidence in the ESUR guideline (Stacul, 2018) was 12/824 procedures (1.6%) among 642 patients with multiple myeloma or monoclonal gammopathies. The two studies using low osmolality contrast media comprised 210 CT examinations in 76 patients, in whom CA-AKI was observed in 4/210 cases (1.9%). The reported CA-AKI incidence by Crowley (2018) was 17/165 procedures (10%) among 94 patients with multiple myeloma. The severity of the CA-AKI was not described. The 94 patients received on average two procedures with iodinated contrast ( $2.1 \pm 1.5$ ). In 47% of procedures (77 procedures) baseline creatinine was elevated and 4% of procedures (6 procedures) had elevated baseline calcium. In the whole group, there was no significant difference between the serum creatinine concentration before and after the contrast-enhanced procedure ( $p=0.08$ ).

### *Existing acute kidney injury after 1 month*

The cohort study by Crowley (2018) reported 10/17 CA-AKI cases (59%) demonstrated a normalised serum creatinine within one month of the procedure. This means that kidney function was not restored to normal in 7/17 (41%) of cases. However, the severity of renal function loss was not quantified. Moreover, it is not clear to which extent these 7 cases represented the same individuals who showed an elevated serum creatinine at baseline.

### From evidence to decision

About 50% of patients with multiple myeloma may develop acute or chronic renal failure in the course of the disease. Major causes of renal failure are light chain cast nephropathy and hypercalcemia. Other causes of renal failure in multiple myeloma are e.g., amyloidosis, nephrotoxic drugs, or hyperuricemia. The literature does not provide clear evidence that multiple myeloma per se predisposes to a higher risk for development of CA-AKI independent of the renal function. The available literature is, however, of limited quality. In general, administration of contrast media in patients with multiple myeloma seems to be safe. In view of the enhanced overall risk for renal failure, however, an alternative imaging technique that does not require iodine-containing CM should always be considered. When administration of iodine-containing CM is deemed necessary, special attention in these patients is required to provide optimal nephrology care as outlined in [Safe Use of Contrast Media part 1](#). In particular, to avoid dehydration and nephrotoxic stimuli and medications, and to provide intravenous prehydration in patients with  $eGFR < 30 \text{ ml/min/1.73m}^2$ . In selected patients with additional risk factors such as light chain cast nephropathy, hypercalcemia, or amyloidosis, close consultation between the haematologist and the imaging physician is recommended to assess the benefit-risk ratio of ICM administration and whether preventive measures or an alternative imaging technique are warranted.

Evidence from other contrast media is very scarce. In line with iodine-based contrast media, the use of gadolinium-based contrast agents does not seem to negatively affect renal function in myeloma patients (Hillengass, 2015).

### Costs

Although keeping a low threshold for application of volume expansion protocols may seem a safe strategy of prevention of CA-AKI, such protocols present a logistic and financial burden to the hospital system (Kooiman, 2013). Particularly the longer pre- and post-hydration schedules will require admission of patients that could otherwise have their CT performed in an outpatient setting. To admit all patients at increased risk for AKI in day-hospital wards for intravenous volume expansion is expensive, and the volume expansion itself may lead to

complications as well. Cost arguments differ for in-hospital patients if it does not lead to an extended hospital stay.

## Recommendations

*In general, administration of contrast media in patients with multiple myeloma seems to be safe. These patients, however, have an enhanced overall risk for renal failure as a result of several concomitant risk factors that might be present.*

Always consider the general principles of prevention of acute kidney injury that were outlined in [Safe Use of Contrast Media, Part 1](#):

- Optimal nephrology care should be the primary goal in all chronic kidney disease patients, with attention to hydration status and medication use.
- Aim for clinical euvolemia, using normal saline or Ringer's lactate, before administration of intravascular iodine-based contrast media, regardless of eGFR.
- Consider patients with an eGFR <30 ml/min/1.73m<sup>2</sup> at risk for CA-AKI.
- Consult a nephrologist/internist for patients with an eGFR <30 ml/min/1.73m<sup>2</sup>.

Determine in each patient with multiple myeloma whether administration of iodine-based contrast media is indicated or if an alternative imaging technique is possible.

- Apply the same precautions to prevent contrast-associated acute kidney injury (CA-AKI) in patients with multiple myeloma as in subjects without this disease, if there are no additional risk factors associated with multiple myeloma for development of acute renal insufficiency.
- For (euvoletic) patients with an eGFR <30 ml/min/1,73m<sup>2</sup> undergoing intravascular administration of iodine-based contrast media prehydrate with 3ml/kg/h NaHCO<sub>3</sub> 1.4% for 1h (or a total of 250ml) pre-CM administration.

In a minority of patients with multiple myeloma, several precipitating factors for acute kidney insufficiency might be present, necessitating consultation between the imaging physician and the treating haematologist.

In selected patients with additional risk factors associated with multiple myeloma for development of acute renal insufficiency (e.g., hypercalcemia, light chain cast nephropathy, amyloidosis), close consultation between the haematologist and imaging physician is needed to ensure an optimal risk-benefit balance, including whether administration of contrast media is warranted and if preventive measures are needed.

## Knowledge gaps

There is no convincing evidence that administration of contrast media to patients with multiple myeloma confers an additional risk for CA-AKI irrespective of renal function.

Prospective and well-controlled data in patients with various stages of multiple myeloma are needed to further explore this clinically relevant question.

## Literature

- Crowley MP, Prabhakaran VN, Gilligan OM. Incidence of contrast-induced nephropathy in patients with multiple myeloma undergoing contrast-enhanced procedures. *Pathol Oncol Res.* 2018; 24(4): 915-919.
- Dimopoulos MA, Moreau P, Terpos E, Mateos MV, Zweegman S, Cook G, et al.; EHA Guidelines Committee. Multiple myeloma: EHA-ESMO Clinical Practice Guidelines for diagnosis, treatment and follow-up. *Ann Oncol.* 2021; 32(3): 309-322.
- Hillengass J, Stoll J, Zechmann CM, Kunz C, Wagner B, Heiss C, et al. The application of gadopentate-dimeglumine has no impact on progression free and overall survival as well as renal function in patients with monoclonal plasma cell disorders if general precautions are taken. *Eur Radiol.* 2015; 25(3): 745-750.
- Kooiman J, van der Molen AJ, Cannegieter SC, Rabelink TJ. Prevention of contrast-induced nephropathy: time for nuance and a new guideline [in Dutch]. *Ned Tijdschr Geneeskd.* 2013; 157(12): A5475.
- LeBlanc R, Bergstrom DJ, Côté J, Kotb R, Louzada ML, Sutherland HJ. Management of myeloma manifestations and complications: The cornerstone of supportive care: Recommendation of the Canadian Myeloma Research Group (formerly Myeloma Canada Research Network) Consensus Guideline Consortium. *Clin Lymphoma Myeloma Leuk.* 2022; 22(1): e41-e56.
- McCarthy CS, Becker JA. Multiple myeloma and contrast media. *Radiology.* 1992; 183(2): 519-521.
- Pahade JK, LeBedis CA, Raptopoulos VD, Avigan DE, Yam CS, Kruskal JB, et al. Incidence of contrast-induced nephropathy in patients with multiple myeloma undergoing contrast-enhanced CT. *AJR Am J Roentgenol.* 2011; 196(5): 1094-1101.
- Sprangers B. Aetiology and management of acute kidney injury in multiple myeloma. *Nephrol Dial Transplant.* 2018; 33(5): 722-724.
- Stacul F, Bertolotto M, Thomsen HS, Pozzato G, Ugolini D, Bellin MF, Bongartz G, Clement O, Heinz-Peer G, van der Molen A, Reimer P, Webb JAW; ESUR Contrast Media Safety Committee. Iodine-based contrast media, multiple myeloma and monoclonal gammopathies: literature review and ESUR Contrast Media Safety Committee guidelines. *Eur Radiol.* 2018; 28(2): 683-691.



## Module 4.2 Safe Use of Contrast Media in Patients with Pheochromocytoma and Paragangliomas

### Clinical question

What safety strategy should be used for contrast media administration in patients with pheochromocytoma or paraganglioma (PPGL)?

This clinical question includes the following underlying question:  
How should intra-arterial and intravenous contrast administration be applied in patients with pheochromocytoma or paraganglioma?

### Introduction

It has been suggested in the past that intravascular administration of contrast media in PPGL patients may provoke a hypertensive crisis (Eisenhofer, 2007). This raises the question whether treatment with  $\alpha$ -adrenergic receptor blockers prior to administration of radiocontrast agents is required to prevent such a crisis.

### Search and select

A systematic review of the literature was performed to answer the following question:  
Which strategies are effective in preventing a hypertensive crisis in patients with pheochromocytoma?

- P (Patients):** Patients with pheochromocytoma or sympathetic paraganglioma and an indication for examination with contrast media.
- I (Intervention):** Contrast administration with  $\alpha$ -blockers,  $\beta$ -blockers, calcium channel blockers.
- C (Comparison):** Contrast administration without additional preventive strategy.
- O (Outcomes):** Cardiovascular complications, hypertensive crisis.

### Relevant outcome measures

The guideline development group considered cardiovascular complications as a critical outcome measure for decision making; and hypertensive crisis as an important outcome measure for decision making.

A priori, the working group did not define the outcome measures listed above but used the definitions used in the studies.

### Search and select (Methods)

The databases Medline (via OVID) and Embase (via Embase.com) were searched with relevant search terms until 22-2-2021. The detailed search strategy is depicted under the tab Methods. The systematic literature search resulted in 125 hits. Studies were selected based on the following criteria five studies were initially selected based on title and abstract screening. After reading the full text, five studies were excluded (see Table of excluded studies in 'Appendices to modules'), and no studies were included.

### Results

No studies were included in the analysis of the literature, and therefore, no systematic literature analysis was performed.

## Justifications – evidence to decision

Pheochromocytomas and paragangliomas (PPGL) are rare neuroendocrine tumours derived from chromaffin tissue of the adrenal medulla and the extra-adrenal sympathetic paraganglia in the thorax and abdomen, respectively (Nölting, 2022). The annual incidence of PPGL in The Netherlands is approximately 100 new cases, with about 80 cases presenting as a pheochromocytoma (Berends, 2018). PPGL have the capacity to produce and release excessive amounts of catecholamines into the circulation. Uncontrolled release of catecholamines can be provoked by several mechanical and pharmacological stimuli (e.g., intubation, tumour manipulation, various drugs), which may result in acute blood pressure elevation, tachyarrhythmias and life-threatening cardiovascular events (so-called pheochromocytoma crisis). To prevent these complications, pre-treatment with antihypertensive agents is usually started prior to surgery. Administration of  $\alpha$ -adrenergic receptor blockers is recommended as treatment of first choice. Tachycardia is treated with  $\beta$ -adrenergic receptor blockers but should only be given to a patient who is already receiving an  $\alpha$ -adrenergic receptor blocker for several days. Neglect of this basic treatment principle may result in a pheochromocytoma crisis with serious cardiovascular complications due to unopposed stimulation of  $\alpha$ -adrenergic receptors with ensuing severe peripheral vasoconstriction (Sibal, 2006).

There is only one small non-randomised prospective study (n=22) comparing the effect of treatment with adrenoceptor blocking agents prior to intravenous administration of low-osmolar CT contrast in patients with a PPGL. In this study, 11 patients received pre-treatment with an  $\alpha$ - and/or  $\beta$ -adrenergic receptor blocker, whereas 11 patients did not receive this premedication (Baid, 2009). Adverse events were not observed in any of these patients. In addition, plasma catecholamine levels within and between groups were not significantly different before and after intravenous administration of contrast medium. The absence of a change in plasma catecholamine levels after intravenous administration of nonionic contrast media in patients with PPGL was also demonstrated in a previous study (Mukherjee, 1997). Moreover, no adverse events were recorded in a retrospective study of 25 patients with PPGL receiving nonionic IV iodine-based contrast media without premedication (Bessell-Browne, 2007).

Based on these observations, intravenous administration of low-osmolar CT contrast is safe in patients with a PPGL without the need of prophylactic treatment with an  $\alpha$ - or  $\beta$ -adrenergic receptor blocker.

Patient series on intra-arterial administration of CT contrast are not available. A survey among six centres of expertise (i.e., five centres in the Netherlands plus the National Institute of Health, Bethesda, USA) demonstrated that five out of six centres would not start prophylactic treatment with an  $\alpha$ - or  $\beta$ -adrenergic receptor blocker in case of intra-arterial administration of CT contrast (personal communication).

There are no data on safety issues when using gadolinium-based or ultrasound contrast agents in PPGL patients.

## Recommendations

*There are no randomised studies evaluating the efficacy of prophylactic treatment in case of intravenous administration of radiocontrast medium in patients with PPGL. Limited data do not suggest that administration of radiocontrast medium provokes an uncontrolled release*

*of catecholamines into the circulation or is associated with adverse events in patients with PPGL. We therefore consider intravenous administration of low-osmolar CT contrast to be safe in patients with a PPGL without the need of prophylactic treatment with an  $\alpha$ - or  $\beta$ -adrenergic receptor blocker.*

Prophylactic treatment with an  $\alpha$ -adrenergic receptor blocker ( $\pm$   $\beta$ -adrenergic receptor blocker) is not indicated before intravenous administration of iodine-based contrast media in patients with pheochromocytoma or paraganglioma.

*There are no randomised studies or case series evaluating the efficacy of prophylactic treatment in case of intra-arterial administration of radiocontrast medium in patients with PPGL. This suggests that this route of administration is safe, which is also in agreement with the outcome of our brief survey among several centres of expertise. We therefore consider intra-arterial administration of low-osmolar CT contrast to be safe in patients with a PPGL without the need of prophylactic treatment with an  $\alpha$ - or  $\beta$ -adrenergic receptor blocker.*

Prophylactic treatment with an  $\alpha$ -adrenergic receptor blocker ( $\pm$   $\beta$ -adrenergic receptor blocker) is not indicated before intra-arterial administration of iodine-based contrast media in patients with pheochromocytoma or paraganglioma.

*There are no data on safety issues when using gadolinium-based or ultrasound contrast agents for imaging in PPGL patients.*

Gadolinium-based contrast agents and ultrasound contrast agents may be safely used in patients with pheochromocytoma or paraganglioma.

## Literature

- Baid SK, Lai EW, Wesley RA, Ling A, Timmers HJ, Adams KT, Kozupa A, Pacak K. Brief communication: radiographic contrast infusion and catecholamine release in patients with pheochromocytoma. *Ann Intern Med.* 2009; 150: 27-32.
- Berends AMA, Buitenwerf E, de Krijger RR, Veeger NJGM, van der Horst-Schrivers ANA, Links TP, Kerstens MN. Incidence of pheochromocytoma and sympathetic paraganglioma in the Netherlands: A nationwide study and systematic review. *Eur J Intern Med.* 2018; 51: 68-73.
- Bessell-Browne R, O'Malley ME. CT of Pheochromocytoma and paraganglioma: risk of adverse events with IV administration of nonionic contrast material. *AJR Am J Roentgenol.* 2007; 188: 970-974.
- Eisenhofer G, Rivers G, Rosas AL, Quezado Z, Manger WM, Pacak K. Adverse drug reactions in patients with pheochromocytoma: incidence, prevention and management. *Drug Saf* 2007; 30(11): 1031-1062.
- Mukherjee JJ, Peppercorn PD, Reznick RH, Patel V, Kaltsas G, Besser M, Grossman AB. Pheochromocytoma: effect of nonionic contrast medium in CT on circulating catecholamine levels. *Radiology* 1997; 202: 227-31.

- Nölting S, Bechmann N, Taieb D, Beuschlein F, Fassnacht M, Kroiss M, Eisenhofer G, Grossman A, Pacak K. Personalized management of pheochromocytoma and paraganglioma. *Endocr Rev.* 2022; 43: 199-239
- Sibal I, Jovanovic A, Agarwal SC, Peaston RT, James RA, Lennard TWJ, Bliss R, Batchelor A, Perros P. Pheochromocytomas presenting as acute crises after beta blockade therapy. *Clin Endocrinol (Oxf).* 2006; 65(2): 186-190.

## Module 4.3 Safe Use of Contrast Media in Patients with Myasthenia Gravis

### Clinical question

What is role of contrast media in patients with exacerbations of myasthenia gravis after contrast media administration?

### Introduction

It is unclear whether contrast media can cause exacerbation of myasthenia gravis (MG) symptomatology for which MG patients should be warned or premedicated.

### Search and select

A systematic review of the literature was performed to answer the following question:

- P (Patients):** Patients with myasthenia gravis and an indication for examination with contrast media.
- I (Intervention):** Contrast medium administration with or without preventive strategy (prednisolone, acetylcholine-reuptake inhibitors).
- C (Comparison):** No contrast medium administration, different contrast medium administration; contrast medium administration without preventive strategy.
- O (Outcomes):** Neurological exacerbations of myasthenia.

### Relevant outcome measures

The guideline development group considered neurological exacerbations of myasthenia as a critical outcome measure for decision making.

A priori, the working group did not define the outcome measures listed above but used the definitions used in the studies.

### Search and select (Methods)

The databases Medline (via OVID) and Embase (via Embase.com) were searched with relevant search terms from January 1<sup>st</sup>, 2000, until March 4<sup>th</sup>, 2021. The detailed search strategy is depicted under the tab Methods. The systematic literature search resulted in 84 hits. Studies were selected based on the following criteria: (1) patients with myasthenia gravis (2) indication for examination with contrast media (3) comparison to patients with no contrast medium administration, different contrast medium administration or contrast medium administration without preventive strategy and (4) the previously described outcome. Eleven studies were initially selected based on title and abstract screening. After reading the full text, nine studies were excluded (see Table of excluded studies in 'Appendices to modules'), and two studies were included. One study, mentioned in the justifications, was not included in our literature analysis (Mehrzi,2014). It did not meet our PICO criteria and was excluded because of the wrong population, including children, and the absence of a comparison group.

### Results

Two studies (Rath, 2017; Somashekar, 2013) were included in the analysis of the literature. Important study characteristics and results are summarized in the evidence tables. The assessment of the risk of bias is summarized in the risk of bias tables.

## Summary of literature

### Description of studies

Rath, et al. (2017) performed a retrospective cohort study, where the rate of acute adverse events as well as delayed clinical worsening up to 30 days was analysed. In 73 patients with confirmed MG who underwent contrast-enhanced CT studies with the administration of low osmolality iodinated contrast agents (ICAs) and compared to 52 patients who underwent unenhanced CT studies. Limitations of this study were (1) selection bias for the enhanced and unenhanced CT scans (2) the relatively low patient numbers (3) the retrospective nature of the investigation which entails the possibility that some adverse events might have been missed in some patients as they had to rely on electronic medical records. To minimize this effect, investigators only included patients with a sufficient clinical information available. Finally, the exact characteristics of the used contrast agents could not be extracted retrospectively from the available data in all patients; therefore, they could not compare the potential side effects of different ICAs with each other.

In a retrospective cohort study by Somashekar, et al. (2013), a computed tomography (CT) was performed in 267 paediatric and adult patients with clinically confirmed MG between January 1, 1995, and December 31, 2011. CT was performed without intravenous administration of contrast material in 155 patients and with intravenous administration of low-osmolality contrast material in 112 patients. Electronic medical records were searched to identify myasthenia gravis-related symptoms (i.e., bulbar, ocular, respiratory, or extremity weakness) before ( $\leq 14$  days) and after ( $\leq 45$  days) each CT examination. All contrast-enhanced CT examinations were performed with one of a variety of low-osmolality contrast media. A variety of baseline characteristics and risk factors were collected for each patient, with attention to (a) the disease status of the patient's myasthenia gravis immediately before CT (i.e. stable, worsening, or improving), (b) history of thymectomy, and (c) acute or chronic cardiac and/ or pulmonary and/or neuromuscular disease not related to myasthenia gravis. Limitations of this study were (1) retrospective nature of the study (2) selection bias between the control group and the experimental group, (3) some adverse events may not have been captured and (4) unable to determine the volume or type of contrast material administered in a large fraction of patients owing to incomplete documentation.

### Results

Rath, et al. (2017) found that 9 of 73 patients (12.3%) experienced a delayed worsening of myasthenic symptoms, i.e., they reached the primary endpoint of progressing by at least one grade in the MGFA classification within 30 days. The medical files of all 9 patients were reviewed and it was concluded that in none of these 9 patients the exacerbation was causally related to the contrast medium. The rate was higher in comparison with the control group of patients receiving CT scans without ICM (3.8%), but the difference did not reach statistical significance. In a subgroup analysis, six of these nine patients (8.2% of all patients) developed a severe deterioration, i.e., a myasthenic crisis, or died in comparison with none in the control group. The mean time to worsening within 30 days did not differ significantly between the two study groups and was 11.1 days for patients with contrast-enhanced CT studies and 13 days in the control group.

Somashekar, et al. (2013) demonstrated that intravenous administration of a low osmolality iodine-based contrast medium (ICM) is associated with a significant increase in the

frequency of disease-related symptoms within 1 day of administration (P=0.01) compared to no intravenous administration of contrast media. The exacerbation frequency is 5.7% above the baseline rate observed in unenhanced CT control group (6.3%- 0.6%). This implies that intravenous low-osmolality ICM is associated with a 5%–6% frequency of acute symptom exacerbation in patients with myasthenia gravis. No difference in symptom frequency at 2–7 days or 8–45 days after CT were detected, indicating that the association between intravenous low-osmolality ICM and symptom progression is a relatively acute association. The contrast-enhanced CT group was associated with a significant reduction in time to disease-related symptom progression following CT (median time to onset of symptom progression, 2.5 days with contrast-enhanced CT vs 14.0 days with unenhanced CT; P=0.05). Acute exacerbations were primarily respiratory (five patients with new-onset dyspnoea: four in contrast-enhanced CT group and one in unenhanced CT group, two patients with progressive dyspnoea: both in the contrast-enhanced CT group), and one patient with progressive weakness: in contrast-enhanced CT group.

Summary of study’s conclusions

Rath, et al. (2017) concluded that ICM administration for CT studies in MG patients should not be withheld if indicated, but patients particularly those with concomitant acute diseases should be carefully monitored for exacerbation of symptoms.

Somashekar, et al. (2013) concluded that intravenous administration of low-osmolality contrast media is significantly associated with exacerbation of myasthenia gravis–related symptoms. Exacerbations most commonly manifest as new or progressive acute respiratory compromise. Yet, review of the medical files showed no causative effect of the contrast medium.

Level of evidence of the literature

The level of evidence regarding the outcome measure **neurological exacerbations of myasthenia** started on a low GRADE due to the observational nature of the included studies and was downgraded by one level to a very low GRADE because of number of included patients.

**Conclusions**

<b>Very low GRADE</b>	<p>The evidence is very uncertain about the effect of contrast media on exacerbations in patients with myasthenia gravis.</p> <p><i>Sources: Rath, 2017, Somashekar, 2013</i></p>
<b>No GRADE</b>	<p>No literature was found regarding the risk of neurological exacerbations of myasthenia in MG patients with using contrast medium in comparison to MG patients with different contrast medium administration or contrast medium administration without preventive strategy.</p>

## Justifications – evidence to decision

Mehrizi, et al. (2014) found that in 81 CTs with contrast and in 23 MRIs with contrast no presence or absence of ADRs was reported. The study was not included in the systematic literature analysis because of severe methodological limitations. There were no cases of increasing myasthenic weakness. No immediate increased risk was noted about gadolinium-based contrast agents with regards to worsening myasthenic symptoms. There is no immediately increased risk for exacerbation of myasthenic weakness with the use of modern low-osmolar ICM. No weakness was reported in patients who received IV GBCA. The authors concluded that there is no immediately increased risk for exacerbation of myasthenic weakness with the use of modern low-osmolar radiologic contrast agents.

All three studies had significant methodological limitations. There seems to be only a very minimal risk of a myasthenic crisis following the administration of iodine-based contrast media. This does not justify withholding ICM for diagnostic studies.

There is no data on any risk after administration of other contrast media, such as gadolinium-based or ultrasound contrast agents.

## Recommendations

Do not withhold contrast media to patients with myasthenia gravis, as the risk of a contrast media-induced myasthenic exacerbation is very low.

## Knowledge gaps

What is the exact role of contrast media in exacerbations of myasthenia gravis (MG)?

What are effective prevention strategies for MG exacerbations?

## Literature

Mehrizi M, Pascuzzi RM. Complications of radiologic contrast in patients with myasthenia gravis. *Muscle Nerve* 2014; 50(3): 443-444.

Rath J, Mauritz M, Zulehner G, Hilger E, Cetin H, Kasprian G, et al. Iodinated contrast agents in patients with myasthenia gravis: a retrospective cohort study. *Journal of Neurology* 2017; 264(6): 1209-1217.

Somashekar DK, Davenport MS, Cohan RH, Dillman JR, Ellis JH. Effect of intravenous low-osmolality iodinated contrast media on patients with myasthenia gravis. *Radiology* 2013; 267(3): 727-734.



## Module 4.4 Safe Use of Contrast Media in Patients with Systemic Mastocytosis

### Clinical question

Which strategies are effective in preventing hypersensitivity reactions and anaphylactic shock in patients with systemic mastocytosis after contrast media administration?

### Introduction

It is unclear whether iodinated contrast media can cause hypersensitivity reactions in patients with systemic mastocytosis and whether prevention strategies should be employed.

### Search and select

A systematic review of the literature was performed to answer the following question: what is the efficacy of a preventive strategy with prednisone and/or antihistamines next to contrast administration compared to contrast administration without additional preventive strategy on the risk of developing anaphylactic shock, (drug) hypersensitivity reaction, anaphylactic allergic reaction in patients with systemic mastocytosis?

- P (Patients):** Patients with systemic mastocytosis and indication for examination with iodine-based contrast media.
- I (Intervention):** Contrast media administration with prednisone and/or antihistamine premedication.
- C (Comparison):** Contrast media administration without additional premedication or other preventive strategies.
- O (Outcomes):** Anaphylactic shock, (drug) hypersensitivity reaction, anaphylaxis, allergic reaction.

### Relevant outcome measures

The guideline development group considered anaphylactic shock and anaphylaxis as critical outcome measures for decision making; and (drug) hypersensitivity reaction and allergic reaction as an important outcome measure for decision making. A priori, the working group did not define the outcome measures listed above but used the definitions used in the studies.

### Search and select (Methods)

The databases Medline (via OVID) and Embase (via Embase.com) were searched with relevant search terms until March 5<sup>th</sup>, 2021. The detailed search strategy is depicted under the tab Methods. The systematic literature search resulted in twenty-one hits. Studies were selected based on the following criteria: (1) patients with systemic mastocytosis and an indication for examination with iodinated contrast media (2) comparing the adverse effects of contrast administration with prednisone and/or antihistamines administration with contrast administration without additional preventive strategy and (3) investigating one of the previously described outcomes. Five studies were initially selected based on title and abstract screening. After reading the full text, no studies could be included.

### Summary of literature

No studies could be included in the literature analysis. Therefore, no systematic literature analysis could be performed.

## **Justifications – evidence to decision**

### Pros and cons of the intervention and quality of the evidence

Clonal mast cell disorders are characterized by the uncontrolled expansion and accumulation of mast cells in one or multiple organs. The term cutaneous mastocytosis is reserved for patients with aberrant mast cell infiltration limited to the skin. Involvement of bone marrow with or without other affected organs (including skin, gastrointestinal tract) leads to the diagnosis of systemic mastocytosis (SM). Mast cells are proinflammatory innate immune cells that can be activated by various stimuli, including allergens, microbes, viruses, and toxins. Upon activation, mast cells degranulate and thereby release various proinflammatory substances and lipid mediators, including tryptase and histamine. These mast cell-derived mediators lead to allergic symptoms and, in case of severe mast cell degranulation, may induce anaphylactic shock. Since patients with mastocytosis have increased numbers of mast cells and the activation threshold for these mast cells is lower due to mutations in their constitutively expressed KIT receptor, patients with systemic mastocytosis are at increased risk of anaphylaxis.

Besides the previously mentioned stimuli, there are several drugs and substances with an (theoretically) increased risk for mast cell degranulation. Potential elicitors are NSAIDs, general anaesthesia, and iodine-based contrast media (ICM); gadolinium-based contrast agents (GBCA) do not impose an increased (theoretical) risk. Hence, they were avoided as much as possible in systemic mastocytosis, although this practice is gradually changing. If given, these drugs and substances are administered cautiously and mostly with concomitant use of anti-allergic premedication, consisting of antihistamines and corticosteroids. However, since the actual clinical risk has seldom been studied systematically under real world conditions due to practical and ethical concerns, it is to date unclear how often and relevant drug-induced mast cell degranulation are for this patient category. Moreover, recent studies suggested that the risk of drug-induced anaphylaxis has been overestimated. For example, a double-blind placebo-controlled challenge with acetylsalicylic acid in patients with mastocytosis (n=50) elicited a mild hypersensitivity reaction in only one subject (Hermans, 2018).

One narrative review reported on the management of invasive procedures in mastocytosis including administration of contrast media (Hermans, 2017). The review did not represent a systematic literature search and did not describe the search methodology and could therefore not be included in the literature analysis. However, Hermans (2017) provided an overview of the risk of adverse reactions including anaphylaxis in patients with mastocytosis after contrast media administration. In addition, the review reported on premedication.

Hermans (2017) reported on four cohort studies among 457 adults with systemic mastocytosis who received contrast media (Brockow, 2008; González de Olano, 2007; Gülen, 2016; Hermans, 2016). Serious radiocontrast-related hypersensitivity was reported in 3/457 patients (0.65%), including development of anaphylaxis in one patient (0.22%) (Hermans, 2017). The number of cases in which premedication was used was not described. The number of serious adverse reactions in the general population to intravenous contrast administration was reported 0.5 to 3% for mild immediate reactions and 0.01 to 0.04% for serious adverse events (Andreucci, 2014; Thong, 2011). Hermans (2017) concludes there is no rationale for avoidance of contrast media in patients with mastocytosis, although some patients can be at increased risk for developing anaphylaxis. This applies particularly to patients with previous mast cell mediator-related symptoms during procedure, previous history of anaphylaxis (regardless of trigger), atopic background, use of  $\beta$ -blockers, ACE inhibitors or NSAIDs or severe mastocyte infiltration of the skin. Not only drugs, but also

physical stimuli (temperature change, exercise, strong odours, pressure, friction) and emotional stress could potentially evoke non-IgE-mediated mechanisms that might cause mast cell degranulation. It is recommended to consider a patient-tailored risk assessment to assess which patients are indicated for premedication (Hermans, 2017).

A similar systematic literature search on the safety of contrast media was conducted in the soon to be published Dutch FMS guideline on mastocytosis 2022, which also did not yield any comparative studies on this subject. In that guideline it is cautiously suggested that iodinated contrast media can be safely applied in the majority of mastocytosis patients (Quality of evidence N/A; Hermans 2017). As a result, it is recommended to develop a personalized management plan for each mastocytosis patient after the diagnosis is made (FMS richtlijn Mastocytose, 2022).

Finally, Schwaab, et al. (2022) recently reported a retrospective analysis of 162 patients with indolent or advanced mastocytosis. Four of them (2.5%) reported a previous hypersensitivity reaction to iodinated contrast media. Hundred forty-eight (91%) of those patients underwent additional imaging, including 80 CT in 56 patients and 252 MRI in 127 patients. In 35 (24%) patients both types of scans were performed. Imaging without application of contrast media was obtained in 14 (9%) patients (CT, n=7; MRI, n=17). Daily anti-mediator therapy, including H1/H2 antihistamines and/or low dose prednisolone was continued. Additional prophylactic premedication (H1- and H2 antihistamine and 50mg methylprednisolone 30-60 minutes prior to the scan) was applied prior to 6 scans; 326/332 (98%) of the scans were performed without additional premedication. No contrast-mediated hypersensitivity reactions occurred. The authors conclude that in the absence of a previous contrast mediated hypersensitivity reaction, use of premedication prior to contrast enhanced imaging may be dispensable.

Systemic mastocytosis patients represent a heterogeneous group of patients and as a result, values and preferences of both patients and physicians may vary widely. Whether or not to use premedication may cause anxiety or medicalization depending on the patient's perspective.

For patients that have been diagnosed with systemic mastocytosis for a long time and have had uneventful iodinated contrast media administration under premedication (without premedication-related side effects), the adaptation of this protocol may cause unwarranted anxiety. In contrast, a newly diagnosed mastocytosis patient with no history of anaphylaxis may experience premedication as unnecessary medicalization, particularly if the patient has experienced side effects with these drugs in the past.

### Costs

The direct costs of applying anti-allergic premedication with prednisolone and/or antihistamines are negligible, as the price of these drugs is very low. Therefore, one should consider the potential indirect costs of additional logistic procedures, as well as the potential adverse effects. These are low for antihistamines (mostly drowsiness) but occur for prednisolone, particularly in weakened patients and upon repetitive exposure. Side effects include:

- risk of glucose dysregulation, particularly in patients with diabetes
- risk of osteoporosis, particularly upon repetitive exposure
- risk of immune suppression, particularly upon repetitive exposure
- risk of temporary cognitive effects such as delirium, particularly in weakened patients.

In severe cases, these side-effects may lead to hospitalization.

On the other hand, omitting premedication may potentially increase the risk of anaphylaxis, which will probably result in hospitalization with the associated costs.

Therefore, premedication should be recommended in high-risk patients, i.e., patients with previous mast cell mediator-related symptoms during medical procedures, history of anaphylaxis (regardless of trigger), atopic background, use of  $\beta$ -blockers, ACE inhibitors or NSAIDs or severe mastocyte infiltration of the skin,

#### Acceptability, feasibility, and implementation

Based on the abovementioned arguments, it is not feasible to make one standard recommendation for the entire group of systemic mastocytosis patients. Recommending premedication in all patients is not indicated as it would lead to unnecessary anxiety, medicalization, side effects and associated costs in a selection of patients. Complete discouragement of premedication however may lead to increased risk of anaphylaxis in a selection of patients. The treating physician should perform this risk assessment.

#### **Recommendations**

*It is important not to withhold iodinated contrast media from patients with systemic mastocytosis in case administration is necessary for optimal imaging. Despite the probably slightly increased risk of anaphylaxis (0.22% in mastocytosis versus the reported 0.01 to 0.04% for serious adverse events in the general population), the benefits of the imaging procedure should outweigh this small risk.*

Do not withhold iodine-based contrast media or gadolinium-based contrast agents in patients with systemic mastocytosis.

*Since there is no convincing evidence that use of anti-allergic premedication is beneficial for systemic mastocytosis patients prior to iodinated contrast administration, there is in general no need to apply this. However, systemic mastocytosis remains a heterogeneous disease with varying clinical symptoms and patients may suffer from comorbidities that should be considered. As a result, it is recommended that their treating physician with knowledge of both the disease and this specific patient should assess whether premedication should be employed. Patient with previous anaphylaxis, extensive skin involvement, use of  $\beta$ -blockers, ACE inhibitors or NSAIDs may be at increased risk of developing anaphylaxis and additional premedication could be considered. Many mastocytosis patients already use H1-antihistamines (up to 4x the recommended daily dose) as part of their regular medication and these drugs should be continued.*

*Preferably, the decision is shared by the patient and the physician and made timely before the patient needs iodine-based contrast media. The recommendation should be clearly reported in the electronic patient records.*

*Comparable to other patient populations, it is possible that systemic mastocytosis patients develop an IgE-mediated allergy for a specific type of contrast. Therefore, in case a hypersensitivity reaction occurs, patients should be referred to a drug allergy specialist for further analysis.*

Recommendation for administration of contrast media in patients with systemic mastocytosis:

- Continue maintenance anti- allergic medication (e.g., H1-/H2-antihistamines)

- Be vigilant to react to a possible hypersensitivity reaction
- Observe the patient  $\geq 30$  min with IV in place
- In case of an allergic reaction, refer to a drug allergy specialist

## Literature

- Andreucci M, Solomon R, Tasanarong A. Side effects of radiographic contrast media: pathogenesis, risk factors, and prevention. *Biomed Res Int.* 2014; 2014: 741018.
- Brockow K, Jofer C, Behrendt H, Ring J. Anaphylaxis in patients with mastocytosis: a study on history, clinical features and risk factors in 120 patients. *Allergy.* 2008; 63(2): 226-232.
- FMS guideline Mastocytosis, 2022. The Dutch Society of Allergology and Clinical Immunology/ Nederlandse Vereniging voor Allergologie en Klinische Immunologie. Available at: [\[URL\]](#). Accessed: 24. June, 2022.
- González de Olano D, de la Hoz Caballer B, Núñez López R, Sánchez Muñoz L, Cuevas Agustín M, Diéguez MC, et al. Prevalence of allergy and anaphylactic symptoms in 210 adult and paediatric patients with mastocytosis in Spain: a study of the Spanish network on mastocytosis (REMA). *Clin Exp Allergy.* 2007; 37(10): 1547-1555.
- Gülen T, Häggglund H, Dahlén B, Nilsson G. High prevalence of anaphylaxis in patients with systemic mastocytosis - a single-centre experience. *Clin Exp Allergy.* 2014; 44(1): 121-129.
- Hermans MAW, Arends NJT, Gerth van Wijk R, van Hagen PM, Kluin-Nelemans HC, Oude Elberink HNG, et al. Management around invasive procedures in mastocytosis: An update. *Ann Allergy Asthma Immunol.* 2017; 119(4): 304-309.
- Hermans MAW, Rietveld MJA, van Laar JAM, Dalm VASH, Verburg M, Pasmans SGMA, et al. Systemic mastocytosis: A cohort study on clinical characteristics of 136 patients in a large tertiary centre. *Eur J Intern Med.* 2016; 30: 25-30.
- Hermans MAW, van der Vet SQA, van Hagen PM, van Wijk RG, van Daele PLA. Low frequency of acetylsalicylic acid hypersensitivity in mastocytosis: The results of a double-blind, placebo-controlled challenge study. *Allergy.* 2018; 73(10): 2055-2062.
- Schwaab J, Brockow K, Riffel P, Lübke J, Naumann N, Jawhar M, et al. Low risk of contrast media-induced hypersensitivity reactions in all subtypes of systemic mastocytosis. *Ann Allergy Asthma Immunol.* 2022; 128(3): 314-318.
- Thong BY, Tan TC. Epidemiology and risk factors for drug allergy. *Br J Clin Pharmacol.* 2011; 71(5): 684-700.

## Chapter 5 Safe Time Intervals between Contrast-Enhanced Studies

### Module 5 Multiple Examinations with Contrast Media in Patients with Normal or Reduced Renal Function

#### Clinical question

What is a safe time interval in patients with normal and reduced renal function between two radiological examinations with contrast media?

What is a safe time interval in patients with reduced renal function between:

- 1 Two radiological examinations using enhanced imaging with iodine-based contrast media?
- 2 Two radiological examinations using enhanced imaging with gadolinium-based contrast agents?
- 3 Two radiological examinations using enhanced imaging with an iodine-based contrast medium and a gadolinium-based contrast agent?

This question contains the following subgroups:

- Elective CT/Angiography/MRI in patients with normal renal function (eGFR >60 ml/min/1.73m<sup>2</sup>)
- Elective CT/Angiography/MRI in patients with moderately reduced renal function (eGFR 30-60 ml/min/1.73m<sup>2</sup>)
- Elective CT/Angiography/MRI in patients with severely reduced renal function (eGFR < 30 ml/min/1.73m<sup>2</sup>)
- CT/Angiography/MRI in emergency or life-threatening situations

#### Introduction

The pharmacokinetics of contrast media (CM) will dictate how waiting times between CT or MRI examinations should be scheduled. There are few dedicated studies about the optimal time between successive doses of CM in repeated contrast-enhanced studies (Kwon, 2021) or when contrast-enhanced CT or (coronary) angiography and contrast-enhanced MRI studies are done in succession.

#### Search and select

For this chapter it was decided not to perform a systematic literature analysis, and therefore no search question with PICO was formulated.

#### Search and select (Methods)

The guideline authors decided to perform an explorative search. The explorative search was performed in the databases Medline (via OVID) and Embase (via Embase.com) were searched with relevant search terms until April 13<sup>th</sup>, 2021. The detailed search strategy is depicted under the tab Methods. The systematic literature search resulted in 441 hits. Studies were selected based on the following criteria: any contrast medium (IBM, GBCA or other), study reported on pharmacokinetics or biodistribution parameters, and any study design (clinical, preclinical, in vitro etc.). The authors also added pharmacokinetics studies from their own database and articles found through cross-referencing.

No systematic literature analysis was performed. Instead, the authors made an overview of all available literature. A narrative literature analysis can be found below.

## Results

### **Systematic literature analysis**

For this chapter it was decided not to perform a systematic literature analysis.

### **Narrative literature analysis**

Results will be discussed separately for the previously described subgroups:

1. Pharmacokinetics and Elimination of Iodine-based CM
2. Pharmacokinetics and Elimination of Gadolinium-based CM
3. Combined CT and MRI Examinations with ICM and GBCA

#### ***1. Pharmacokinetics and Elimination of Iodine-based CM***

Most studies on iodine-based CM (ICM) have employed an open, 2-compartment model for pharmacokinetic analyses. The first compartment is the plasma in which the molecules are being diluted and the second compartment is the extravascular extracellular space of the tissues where there is an effective capillary permeability, i.e., outside the brain. In this classical model the plasma concentration decays by distribution of the CM from plasma to the extracellular volume (distribution phase, slope  $\alpha$ ), and by elimination of the CM from plasma to urine by renal excretion (elimination phase, slope  $\beta$ ).

The elimination phase is of interest as it defines the time when a second administration of the same product can be performed safely, with no risk of accumulation and potential toxicity (such as contrast-associated acute kidney injury). In theory, near-complete elimination to 1,5% of the original concentration is achieved within 6 elimination half-lives ( $T_{1/2} \beta$ ) (Bourin, 1997; Dean, 1993).

#### ***Results in Animal Studies***

In most animal studies the open, 2-compartment model describes the pharmacokinetics of ICM well. All ICM behave similarly in early distribution and excretion. In animal studies distribution volumes ranged 180-250 ml/kg, or between 21-25% of body weight. This indicates distribution within the extracellular fluid only. Renal excretion is species dependent, and is higher for rats, rabbits, and dogs, compared to monkeys and humans due to their higher weight normalized GFR. Elimination half-life times in rat studies range 20-25 minutes, in dogs 50-62 minutes, and in monkeys 71-83 minutes (Bourrinet, 1994; Coveney, 1989; Dencausse, 1996; Gardeur, 1980; Heglund, 1995; Lorusso, 1994; Morin, 1988; Mützel, 1980; Mützel, 1983).

The excretion in urine within 4h is 60-85% and within 24h is 86-95%, depending on the animal species. The urinary excretion is complete within 48h. Excretion in faeces is species-dependent, less than 1% for dogs and up to 7% for rats (Bourrinet, 1994; Coveney, 1989; Dencausse, 1996; Gardeur, 1980; Heglund, 1995; Lorusso, 1994; Morin, 1988; Mützel, 1980; Mützel, 1983).

After oral ingestion, 1-2% of the ICM reaches the systemic circulation and is eliminated rapidly via the kidneys. The rest is eliminated in unchanged form with the faeces (Bourrinet, 1994; Mützel, 1983).

#### ***Results in Human Studies – Normal Renal Function***

Pharmacokinetics in humans also worked well using an open 2-compartment model. The distribution volumes in healthy volunteers and young patients were between 165-280 ml/kg, indicating a distribution in the extracellular volume. Distribution half-lives are rapid, in the range of 15-22 minutes. For currently available nonionic ICM, the elimination half-value times range 1.8-2.3 hours (Bourin, 1997; Edelson, 1984; Fontaine, 1996; Krause, 1994; Lorusso, 2001; McKinstry, 1984; Olsson, 1983; Spencer, 1996; Svaland, 1992; Wilkins, 1989), but may already increase to 3.25-4h in volunteers and patients of older age (Hartwig, 1989).

Excretion in urine is quick and independent of dose. About 80% of the dose will be eliminated within 4h, and 93-98% is excreted in 24h. There is limited faecal excretion, usually < 2-4%. Nonionic ICM are not metabolized, and there is no binding to plasma proteins.

The elimination half-lives for older ionic high-osmolar ICM that are still in use as oral ICM for fluoroscopy or CT are shorter than for current nonionic low-osmolar CM used for intravascular administration, in the range of 1.3-1.8h (Difazio, 1978; Feldman, 1984; Gardeur, 1980).

#### *Results in Human Studies – Renal Insufficiency*

In patients with renal impairment the half-lives of the ICM increase progressively. The literature on pharmacokinetics of currently available ICM in patients with renal insufficiency is scarce and patient categories vary. In moderate renal insufficiency (eGFR 30-60 ml/min/1.73m<sup>2</sup>) the elimination half-lives increase up to 6.9h, and in severe renal insufficiency (eGFR < 30 ml/min/1.73m<sup>2</sup>) the half-lives vary for several ICM from 10.0h to 27.0h, depending on the degree of insufficiency. When renal function is impaired, biliary excretion will increase somewhat (Corradi, 1990; Lorusso, 2001; Nossen, 1995).

The summarized data are largely dependent on the study populations and settings and should be taken as a relative indication.

#### **From evidence to decision**

The physicochemical data of currently used ICM have been summarized in [Supplemental Table S1](#) at the end of this guideline.

For ICM the use of an open, 2-compartment model is justified. No third compartment for storage can be identified. In patients with normal renal function the renal elimination half-value times are between 1.8 and 2.3 h (average 2.0h) Almost all the administered contrast medium will be cleared in 6 half-lives, or 12 h, and already over 75% will be cleared in 2 half-lives, or 4 h.

In patients with moderate renal impairment (eGFR 30-60 ml/min/1,73m<sup>2</sup>), the renal elimination half-lives increase to 7 h, so it will need a maximum 42 h for near-complete clearance, and about 14 h for 75% clearance. In severe renal impairment (eGFR < 30 ml/min/1,73m<sup>2</sup>) renal elimination half-lives vary widely between 10-27 h, so in the worst case it will need a maximum 162 h (6,75 days) for near-complete clearance, and about 55 h (2,3 days) for 75% clearance (Table 5.1).



**Table 5.1 Renal Excretion of Iodine-Based Contrast Media**

Name	Structure	Ionicity	Renal Excretion (Elimination $T_{1/2}$ ; hours - Near complete elimination in $6 \times T_{1/2}$ )		
			Normal Renal Function (eGFR > 60 ml/min)	Moderately Reduced RF (eGFR 30-60 ml/min)	Severely Reduced RF (eGFR < 30 ml/min)
iohexol	Monomeric	Nonionic	2.0	NA	27.2
iopromide	Monomeric	Nonionic	1.8	NA	NA
iomeprol	Monomeric	Nonionic	2.3	6.9	15.1
ioversol	Monomeric	Nonionic	2.1	NA	NA
iobitridol	Monomeric	Nonionic	NA	NA	NA
iodixanol	Dimeric	Nonionic	2.2	NA	23.0

Sources: See references in text above

## 2. Pharmacokinetics and Elimination of Gadolinium-based CM

Most of the early elimination of extracellular GBCA is via renal excretion, and for the hepatobiliary GBCA (gadobenate or gadoxetate) there is additional biliary excretion.

The elimination phase is of interest as it defines the time when a second administration of the same or another GBCA can be performed safely, with lower risk of accumulation and potential toxicity (such as nephrogenic systemic fibrosis or gadolinium deposition). In theory, near-complete elimination to 1,5% of the original concentration is achieved within 6 elimination half-lives ( $T_{1/2} \beta$ ) (Bourin, 1997; Dean, 1993).

### Results in Animal Studies – Normal renal and biliary function

All extracellular GBCA behave similarly in early distribution and excretion, except for brain. Elimination half-lives in rat studies range 16-23 min and in rabbit and dog studies 45-60 min for all clinically administered GBCA doses (Allard, 1988; Harpur, 1993; Lorusso, 1999; Robic, 2019; Tombach, 2002; Tweedle, 1988; Vittadini, 1988; Vogler, 1995), with decreases in elimination with increasing age or presence of diabetes of rats (Michel, 1992). The decrease is first rapid and then progressively slower. Steady-state distribution volumes range 210-230 ml/kg, indicating distribution in the extracellular fluid (Allard, 1988; Harpur, 1993; Lorusso, 1999; Robic, 2019; Tombach, 2002; Tweedle, 1988; Vittadini, 1988; Vogler, 1995). More than 95% of the contrast is recovered in urine within 24h after administration. Only small fractions are excreted with bile into the faeces, usually < 4% within 24h.

For the hepatobiliary GBCA gadobenate and gadoxetate, there is additional biliary excretion. Like the renal elimination, this is species-dependent, and is high for rats and rabbits. The administration of these CM is associated with a choleric effect. About 30-35% is eliminated with bile into faeces for gadobenate (Lorusso, 1999; Vittadini, 1988), and 63-68% for gadoxetate (Schuhmann-Gampieri, 1997). Biliary excretion has a capacity-limiting step with increasing doses, and maximum excretion is about 5  $\mu\text{mol}/\text{min} \cdot \text{kg}$ .

Clearance of macrocyclic GBCA from the brain is a slow process, both for cerebrum and cerebellum. Half-lives for elimination were 1.8-2.0 weeks in the first 6 weeks, and 6.3-8.3 weeks thereafter, slightly slower in cerebellum than in cerebrum (Frenzel, 2021).

#### *Results in Animal Studies – Renal and Hepatobiliary Insufficiency*

Only few studies with hepatobiliary GBCA have been done in rats with combinations of reduced renal and biliary function. With reduced biliary elimination there will be an increased renal elimination and vice versa. Injection of bromosulfophthalein (BSP) or bile duct ligation can reduce biliary excretion of gadobenate to 1-5%, with concomitant increase in urinary excretion of 66-83% (De Haën, 1995). Renal artery or bile duct ligation reduced elimination half value times of gadoxetate, but significantly more after renal artery ligation. Between 1-3% of CM remained in the body in these animals (Mühler, 1994 and 1995).

#### *Results in Human Studies – Normal Renal and Biliary Function*

Pharmacokinetic analyses of extracellular GBCA in volunteers showed renal clearances matching the glomerular filtration rate. The reported excretion half-lives range from 1.3 to 1.8h. Steady state distribution volumes are in range of 180-250 ml/kg. Clearance from plasma is rapid with 75-85% of the CM cleared within 4h, and 94-98% cleared within 24h (Hao, 2019; Le Mignon, 1990; McLachlan, 1992; Staks, 1994; Tombach, 2002 Van Wagoner 1993, Weinmann, 1984).

For the hepatobiliary gadoxetate the terminal half-lives ranged from 1.0h for young to 1.8h for older volunteers, with a balanced renal and biliary excretion. The biliary excretion is only saturated for high doses, not used in clinical practice (Gschwend, 2011; Hamm, 1995; Schuhmann-Gampieri, 1992). Due to the lower biliary excretion, gadobenate has a profile that is more like the extracellular GBCA. The half-value times were 1.2h for clinically used doses with distribution volumes of 170-218 ml/kg (Spinazzi, 1999).

#### *Results in Human Studies – Renal and Hepatobiliary Insufficiency*

In patients with renal impairment the half-lives of the extracellular GBCA increase progressively. However, the summarized data are dependent on the study populations and settings and should be taken as a relative indication.

In patients with mild renal insufficiency (eGFR 60-90 ml/min/1.73m<sup>2</sup>) the half-life for the new GBCA gadopidlenol increased to 3.2h (Bradú, 2021). In moderate renal insufficiency (eGFR 30-60 ml/min/1.73m<sup>2</sup>) the increase in half-lives was between 3.8 and 6.9h, depending on the amount of renal impairment, with higher values for lower eGFR. This is equivalent with a factor of 2.5-3.5x that of volunteers with normal renal function. In severe renal insufficiency (eGFR < 30 ml/min/1.73m<sup>2</sup>), excluding dialysis, half-lives are between 9.5-30h, equivalent to 6-18x the value of volunteers with normal renal function (Bradú, 2021,

Chachuat, 1992; Joffe, 1998; Schuhmann-Gampieri, 1991; Swan, 1999; Tombach, 2000 and 2001, Yoshikawa, 1997).

In the hepatobiliary GBCA, a combination of renal and hepatic impairment has been studied, as bile duct excretion is able to compensate for some renal function deterioration. Moderate hepatic impairment did not change the plasma half-life, but severe hepatic impairment (like Child-Pugh C cirrhosis) led to slight increases of 2.6h for gadoxetate and 2.2h for gadobenate (Davies, 2002; Gschwend, 2011). For gadoxetate, moderate renal impairment could be compensated with a half-life of only 2.2h, but severe renal impairment led to a half-value time of 20h (Gschwend, 2011). In gadobenate moderate renal impairment increased the half-life to 5.6h and severe impairment to 9.2h. This is much more like the other extracellular GBCA (Swan, 1999).

### *Results in Systematic Reviews*

Already in the late 1980s, biodistribution studies suggested that an open 3-compartment model may better fit the pharmacokinetic data of GBCA than the 2-compartment model. The first compartment is the plasma and the second and third compartments are the extravascular extracellular space of the tissues where there is an effective capillary permeability. The second and third compartments of the model are related to rapidly and slowly equilibrating tissues (storage compartment) (Wedeking, 1988 and 1990).

In a large systematic review of pharmacokinetic data, the 3-compartment, open model better fitted the data, with 3 phases of GBCA decay from plasma. Apart from the distribution phase ( $\alpha$ ) and rapid (renal) elimination phase ( $\beta$ ), there is a slow residual excretion phase ( $\gamma$ ). After IV administration of GBCA, plasma levels of gadolinium fall rapidly, indicating a short distribution phase with an average half-life of  $0.2 \pm 0.1$  h. Then, levels will decrease slower as renal elimination prevails, with half-lives  $1.7 \pm 0.5$  h when measured in plasma and  $2.6 \pm 0.6$  h in urine (Lancelot, 2016).

The third phase of decay from the storage compartment can only be demonstrated in urine at a time when concentrations in plasma have become undetectable. Calculated rate constant  $\gamma$  values are 0.107/h for gadoterate, and 0.012/h for gadobenate, and 0.029/h for gadoxetate. The half-life for this residual excretion phase is about 5-8 times longer for currently approved linear GBCA (approximately 25 h) compared to a macrocyclic GBCA (6 h), with risk of dechelation or transmetallation. This residual phase is species-independent and its rate constant  $\gamma$  is closely related to the thermodynamic stability of the GBCA molecule. The relative contribution of this slow elimination is not insignificant, being 21-35% for linear GBCA vs. 10% for macrocyclic GBCA. The exact locations of this third compartment are not completely clear, but Gd retention/deposition can be found in the brain, spleen, liver, kidney, skin, and bones (Lancelot, 2016).

### **From evidence to decision**

The physicochemical data of currently available GBCA have been summarized in [Supplemental Table S2](#) at the end of this guideline.

For general MRI, currently only stable macrocyclic GBCA are allowed. Using the optimized open 3-compartment model, in patients with normal renal function the renal elimination half-lives are between 1.3 and 1.8 h (average 1.6h) and the residual excretion time will be in

the order of 6 h. Almost all the administered contrast medium will be cleared in 6 half-lives, or 10-12 h, and already over 75% will be cleared in a little more than 2 half-lives, or 4 h.

In patients with moderate renal impairment (eGFR 30-60 ml/min/1,73m<sup>2</sup>), the renal elimination half-lives increase to 4-7 h, so it will need a maximum 42 h for near-complete clearance, and about 14 h for 75% clearance. As the residual excretion depends on thermodynamic stability, it will not be significantly prolonged in these patients.

The situation is worse for patients with severe renal impairment (eGFR < 30 ml/min/1,73m<sup>2</sup>). Renal elimination half-lives are between 10-30 h, so it will need a maximum 180 h (7,5 days) for near-complete clearance, and about 60 h (2,5 days) for 75% clearance. It is thus far unclear if the residual excretion is prolonged in these patients (Table 5.2).

**Table 5.2 Renal Excretion of Gadolinium-Based Contrast Agents**

<i>Name</i>	<i>Ligand</i>	<i>Structure</i>	<i>Ionicity</i>	<i>Renal Excretion</i> (Elimination T <sub>1/2</sub> ; hours – Near complete elimination in 6 x T <sub>1/2</sub> )		
				Normal RF (eGFR > 60 ml/min)	Moderately Reduced RF (eGFR 30-60 ml/min)	Severely Reduced RF (eGFR < 30 ml/min)
Gadopentetate	DTPA	Linear	Ionic	1.6	4.0	30.0
Gadobenate	BOPTA	Linear	Ionic	1.2-2.0	5.6	9.2
Gadoxetate	EOB-DTPA	Linear	Ionic	1.0	2.2	20.0
Gadoteridol	HP-DO3A	Macrocyclic	Nonionic	1.6	6.9	9.5
Gadobutrol	BT-DO3A	Macrocyclic	Nonionic	1.8	5.8	17.6
Gadoterate	DOTA	Macrocyclic	Ionic	1.6	5.1	13.9
Gadopiclenol	NA	Macrocyclic	Nonionic	1.6-1.9	3.8	11.7

Sources: from references in text above

For approved linear hepatobiliary GBCA, moderate renal impairment leads to an increase in renal elimination half-value times of 2-5 h, corresponding to a maximum 30h for near-complete and 10h for 75% clearance. Severe renal impairment leads to an increase in renal elimination half-value times of 10-20 h, corresponding to 60-120 h for near-complete and 20-40 h for 75% clearance. Residual excretion half-lives are in the order of 30-48h.

### **3. Combined Enhanced imaging with an ICM and a GBCA**

In oncology diagnosis and follow-up, contrast-enhanced MRI examinations with GBCA and contrast-enhanced CT examinations with ICM are often combined, sometimes on the same day. The presence of ICM will influence the (results of) MRI examination and the presence of GBCA will influence the (results of) CT examination. The degree of these effects will determine the optimal order of examinations. The pharmacokinetics of both types of CM will dictate how waiting times between examinations should be scheduled.

#### *Combining CT and MRI: Effects of GBCA on CT studies*

Multiple in vitro studies have demonstrated the effect of GBCA in CT. At equal mass concentration, GBCA will have a higher CT attenuation than ICM due to the higher atomic number of Gadolinium (64) compared to iodine (53) (Bloem, 1989; Engelbrecht, 1996; Gierada, 1999; Kim, 2003; Quinn, 1994; Schmitz, 1995; Schmitz, 1997; Zwicker, 1991).

Yet, in clinical practice the molar concentration used for ICM is much higher than for GBCA. For instance, iopromide 300 mg/ml equals 2,94 mmol/ml, compared to GBCA with 0.5-1.0 mmol/ml. Excellent detailed phantom studies from Sweden focusing on equal attenuation have shown that in CT at 80-140kVp a solution of 0.5M GBCA is iso-attenuating to a solution of ICM with 91-116 mg I/mL for a chest phantom, and to 104- 125 mg I/mL for an abdominal phantom. Due to a different X-ray tube filtration, in DSA at 80-120 kVp a solution of 0.5M GBCA is iso-attenuating to 73-92 mg I/mL (Nyman, 2002 and 2011).

Many clinical studies have used GBCA for CT or angiography in renal insufficiency patients or in patients with (severe) hypersensitivity reactions to ICM. The GBCA injection frequently needs high doses of 0.3-0.5 mmol/kg for good vascular enhancement (Kaufman 1996), which is relatively short-lived. Such doses may be useful for vascular imaging or interventions but are usually not suitable for optimal imaging of the abdominal organs. Good overviews of the results can be found in multiple reviews (Spinosa, 2002; Strunk, 2004).

Nowadays, such high doses cannot be used anymore. Animal studies have shown that for equal attenuation, GBCA are more nephrotoxic and more costly than low-dose or diluted ICM (Elmsthål, 2006; Nyman, 2011). In addition to the risk of NSF and Gadolinium deposition, these are the major reasons that current ESUR guidelines strongly discourage the use of GBCA for radiographic examinations (Thomsen, 2002).

Due to the short-lived effect of GBCA injection in CT, this vascular enhancement is less cumbersome in clinical practice when combining contrast-enhanced CT and MRI examinations on the same day. One exception is that the kidneys will concentrate the gadolinium, so that the renal collecting systems, ureters, and bladder will show CT enhancement for a significant period.

#### *Combining CT and MRI: Effects of ICM on MRI studies*

In vitro experiments in MR Arthrography may serve as a model of these effects. Mixing of ICM with GBCA will lead to some shortening of the T1 (spin-lattice) relaxation time, and a more profound shortening of the T2 (spin-spin) relaxation time. This results in an increase in T1w signal and a decrease in T2w signal. The magnitude of the effect is greater for higher GBCA concentrations. The presence of ICM shifts the peak SI towards lower GBCA concentrations. Overall, in small joint spaces the enhancement was decreased (Andreisek, 2008; Choi, 2008; Ganguly, 2007; Kopka, 1994; Montgomery, 2002).

Similar effects can also be seen in routine MRI examinations, but to a lesser degree. The shortening effect on T1 and T2 times, with increase in T1w signal and a decrease in T2w signal, depends on the concentration of the ICM and on the side chains in the molecular structure of the specific ICM that is used (effect is for ioxithalamate > iotrolan > iopamidol > iodixanol, iohexol or iomeprol) (Hergan, 1995; Jinkins, 1992; Kopka, 1994; Morales, 2016). Very recently it was shown that adding an overdose of ICM to macrocyclic GBCA led to a significant increase in R1 relaxation and the combination was excreted more slowly, possibly because of the formation of chemical adducts between the lipophilic three-iodo-benzene rings of the ICM and the tetra-aza-cycle of the macrocyclic GBCA (DiGregorio, 2022). Increasing concentrations of ICM will also influence diffusion weighted imaging, with increased signal and decreased ADC values (Ogura, 2009), and on functional imaging with shortening of the T2\* times used in BOLD MRI (Wang, 2014).

The effects of ICM in MRI can be longer-lasting and will be more disturbing on subsequent contrast-enhanced MRI.

## Recommendations

### 1. Safe time intervals in enhanced imaging with iodine-based contrast media

*Based on the following, the Committee can recommend the following waiting times between successive administrations of iodine-based contrast media in contrast-enhanced CT (or (coronary) angiography) to avoid accumulation of iodine-based contrast media with potential safety issues:*

Consider a waiting time between **elective** contrast-enhanced CT or (coronary) angiography with successive iodine-based contrast media administrations in patients with **normal renal function** (eGFR >60 ml/min/1.73m<sup>2</sup>) of:

- Optimally 12 hours (near complete clearance of the previously administered iodine-based contrast media)
- Minimally 4 hours (if clinical indication requires rapid follow-up)

Consider a waiting time between **elective** contrast-enhanced CT or (coronary) angiography with successive iodine-based contrast media administrations in patients with **moderately reduced renal function** (eGFR 30-60 ml/min/1.73m<sup>2</sup>) of:

- Optimally 48 hours (near complete clearance of the previously administered iodine-based contrast media)
- Minimally 16 hours (if clinical indication requires rapid follow-up)

Consider a waiting time between **elective** contrast-enhanced CT or (coronary) angiography with successive iodine-based contrast media administrations in patients with **severely reduced renal function** (eGFR < 30 ml/min/1.73m<sup>2</sup>) of:

- Optimally 168 hours (near complete clearance of the previously administered iodine-based contrast media)
- Minimally 60 hours (if clinical indication requires rapid follow-up)

In **emergency or life-threatening situations**, employ less waiting time between contrast-enhanced CT (or coronary angiography) with successive iodine-based contrast media administrations.

## 2. Safe time intervals in enhanced imaging with gadolinium-based contrast agents

*Based on the review above, the Committee recommends the following waiting times between contrast-enhanced MRI with successive administrations of gadolinium-based contrast agents, to avoid accumulation of gadolinium-based contrast agents with potential safety issues:*

Consider a waiting time between **elective** contrast-enhanced MRI with successive gadolinium-based contrast agent administrations in patients with **normal renal function** (eGFR >60 ml/min/1.73m<sup>2</sup>) of:

- Optimally 12 hours (near complete clearance of the previously administered gadolinium-based contrast agent)
- Minimally 4 hours (if clinical indications require rapid follow-up)

Consider a waiting time between **elective** contrast-enhanced MRI with successive gadolinium-based contrast agent administrations in patients with **moderately reduced renal function** (eGFR 30-60 ml/min/1.73m<sup>2</sup>) of:

- Optimally 48 hours (near complete clearance of the previously administered gadolinium-based contrast agent)
- Minimally 16 hours (if clinical indications require rapid follow-up)

Consider a waiting time between **elective** contrast-enhanced MRI with successive gadolinium-based contrast agent administrations in patients with **severely reduced renal function** (eGFR < 30 ml/min/1.73m<sup>2</sup>) of:

- Optimally 168 hours (near complete clearance of the previously administered gadolinium-based contrast agent)
- Minimally 60 hours (if clinical indications require rapid follow-up)

In **emergency or life-threatening situations**, employ less waiting time between contrast-enhanced MRI with successive gadolinium-based contrast agent administrations.

## 3. Safe time intervals in combined enhanced imaging with an iodine-based contrast medium and a gadolinium-based contrast agent

*Based on the review above, the Committee recommends the following waiting times between contrast-enhanced MRI and contrast-enhanced CT or (coronary) angiography, to avoid interference of the contrast medium used in the first contrast-enhanced examination on the other contrast-enhanced examination, and to avoid accumulation of contrast media with potential safety issues:*

When combining contrast-enhanced CT or (coronary) angiography with an iodine-based contrast medium and contrast-enhanced MRI with a gadolinium-based contrast agent on the same day in **elective** situations, it is better to start with the MRI examination, unless the CT examination is intended for the kidneys, ureters, or bladder (CT Urography).

*In patients with normal renal function the interference of the contrast medium used in the first contrast-enhanced examination on the second contrast-enhanced examination will predominantly determine the suggested waiting times.*

Consider a waiting time between **elective** contrast-enhanced MRI with a gadolinium-based contrast agent and contrast-enhanced CT or (coronary) angiography with an iodine-based contrast medium in patients with **normal renal function** (eGFR >60 ml/min/1.73m<sup>2</sup>) of:

- Optimally 6 hours (near complete clearance of the effects of the previously administered gadolinium-based contrast agent)
- Minimally 2 hours (if the clinical indication requires rapid follow-up)

*In patients with reduced renal function the avoidance of accumulation of contrast media with potential safety issues will predominantly determine the suggested waiting times (as in sections 1 and 2 above).*

Consider a waiting time between **elective** contrast-enhanced MRI with a gadolinium-based contrast agent and contrast-enhanced CT or (coronary) angiography with an iodine-based contrast medium in patients with **moderately reduced renal function** (eGFR 30-60 ml/min/1.73m<sup>2</sup>) of:

- Optimally 48 hours (near complete clearance of the previously administered gadolinium-based contrast agent)
- Minimally 16 hours (if the clinical indication requires rapid follow-up)

Consider a waiting time between **elective** contrast-enhanced MRI with a gadolinium-based contrast agent and contrast-enhanced CT or (coronary) angiography with an iodine-based contrast medium in patients with **severely reduced renal function** (eGFR < 30 ml/min/1.73m<sup>2</sup>) of:

- Optimally 168 hours (near complete clearance of the previously administered gadolinium-based contrast agent)
- Minimally 60 hours (if the clinical indication requires rapid follow-up)

When combining contrast-enhanced CT or (coronary) angiography with an iodine-based contrast medium and contrast-enhanced MRI with a gadolinium-based contrast agent on the same day in **emergency or life-threatening situations**, employ no waiting time and perform back-to-back examinations.



## Literature

- Allard M, Doucet D, Kien P, Bonnemain B, Caillé JM. Experimental study of DOTA-gadolinium. Pharmacokinetics and pharmacologic properties. *Invest Radiol* 1988; 23 (Suppl 1): S271-S274.
- Andreisek G, Froehlich JM, Hodler J, et al. Direct MR arthrography at 1.5 and 3.0 T: signal dependence on gadolinium and iodine concentrations--phantom study. *Radiology* 2008; 247: 706-716.
- Bloem JL, Wondergem J. Gd-DTPA as a contrast agent in CT. *Radiology* 1989; 171: 578-579.
- Bourin M, Jolliet P, Ballereau F. An overview of the clinical pharmacokinetics of X-ray contrast media. *Clin Pharmacokin* 1997; 32: 180-193.
- Bourrinet P, Dencausse A, Cochet P, Bromet-Petit M, Chambon C. Whole body quantitative autoradiographic study of the biodistribution of iobitridol in rats. *Invest Radiol* 1994; 29: 1057-1060.
- Bradu A, Penescu M, Pitrou C, et al. Pharmacokinetics, dialysability and safety of gadopiclesol, a new gadolinium-based contrast agent, in patients with impaired renal function. *Invest Radiol* 2021; 56: 486-493.
- Chachuat A, Molinier P, Bonnemain B, et al. Pharmacokinetics and tolerance of Gd-DOTA (DOTAREM) in healthy volunteers and in patients with chronic renal failure. *Eur Radiol* 1992; 2: 326-329.
- Choi JY, Kang HS, Hong SH, et al. Optimization of the contrast mixture ratio for simultaneous direct MR and CT arthrography: an in vitro study. *Korean J Radiol* 2008; 9: 520-525.
- Corradi A, Menta R, Cambi V, Maccarini P, Cerutti R. Pharmacokinetics of iopamidol in adults with renal failure. *Arzneimittelforschung* 1990; 40: 830-832.
- Coveney JR, Robbins MS. Biodistribution and excretion of <sup>125</sup>I ioversol in conscious dogs. *Invest Radiol* 1989; 24 (Suppl 1): S23-S27.
- Davies BE, Kirchin MA, Bensek K, Lorusso V, Davies A, Parker JR, LaFrance ND. Pharmacokinetics and safety of gadobenate dimeglumine (Multihance) in subjects with impaired liver function. *Invest Radiol* 2002; 37: 299-308..
- Dean PB, Kivisaari L, Korman M. Contrast enhancement pharmacokinetics of six ionic and nonionic contrast media. *Invest Radiol* 1983; 18: 368-374.
- De Haën C, Lorusso V, Luzzani F, Tirone P. Hepatic transport of the magnetic resonance imaging contrast agent gadobenate dimeglumine in the rat. *Acad Radiol* 1995; 2: 232-238.
- Dencausse A, Violas X, Feldman H, Havard P, Chambon C. Pharmacokinetic profile of iobitridol. *Acta Radiol Suppl* 1996; 400: 25-34.
- DiFazio LT, Singhvi SM, Heald AF, et al. Pharmacokinetics of iodamide in normal subjects and in patients with renal impairment. *J Clin Pharmacol* 1978; 18: 35-41.
- Di Gregorio E, Arena F, Gianolio E, Ferrauto G, Aime S. The interaction between iodinated X-ray contrast agents and macrocyclic GBCAs provides a signal enhancement in T1-weighted MR images: Insights into the renal excretion pathways of Gd-HPDO3A and iodixanol in healthy mice. *Magn Reson Med*. 2022; 88(1): 357-364.
- Edelson J, Shaw D, Palace G. Pharmacokinetics of iohexol, a new nonionic radiocontrast agent, in humans. *J Pharm Sci* 1984; 73(7): 993-995.
- Elmståhl B. Are gadolinium contrast media really less nephrotoxic than iodine agents in radiographic examinations? A comparison in relation to their ability to attenuate X-rays in a pig model. Lund University Faculty of Medicine: Doctoral Dissertation Series 2006:9.

- Engelbrecht V, Koch JA, Rassek M, Mödder U. Gadodiamide and gadolinium-DTPA as intravenous media in computed tomography. *RöFo Fortschr Roentgenstr* 1996; 165: 24-28.
- Feldman S, Hayman LA, Hulse M. Pharmacokinetics of low- and high-dose intravenous diatrizoate contrast media administration. *Invest Radiol* 1984; 19: 54-57
- Fontaine H, Harnish P, Andrew E, Grynne B. Safety, tolerance, and pharmacokinetics of iodixanol injection, a nonionic, isosmolar, hexa-iodinated contrast agent. *Acad Radiol* 1996; 3 (Suppl 3): S475-S484.
- Frenzel T, Ulbrich HF, Pietsch H. The macrocyclic gadolinium-based contrast agents gadobutrol and gadoteridol show similar elimination kinetics from the brain after repeated intravenous injections in rabbits. *Invest Radiol* 2021; 56: 341-347.
- Ganguly A, Gold GE, Butts Pauly K, et al. Quantitative evaluation of the relaxivity effects of iodine on GD-DTPA enhanced MR arthrography. *J Magn Reson Imaging* 2007; 25: 1219-1225.
- Gardeur D, Lautrou J, Millard JC, Berger N, Metzger J. Pharmacokinetics of contrast media: experimental results in dog and man with CT implications. *J Comput Assist Tomogr* 1980; 4: 178-185.
- Gierada DS, Bae KT. Gadolinium as a CT contrast agent: assessment in a porcine model. *Radiology* 1999; 210: 829-834.
- Gschwend S, Ebert W, Schultze-Mosgau M, Breuer J. Pharmacokinetics and imaging properties of Gd-EOB-DTPA in patients with hepatic and renal impairment. *Invest Radiol* 2011; 46: 556-566
- Hamm B, Staks T, Mühler A, Bollow M, Taupitz M, Frenzel T, Wolf KJ, Weinmann HJ, Lange L. Phase I clinical evaluation of Gd-EOB-DTPA as a hepatobiliary MR contrast agent: safety, pharmacokinetics, and MR imaging. *Radiology* 1995; 195: 785-792.
- Hao J, Bourrinet P, Desché P. Assessment of pharmacokinetic, pharmacodynamic profile, and tolerance of gadopiclesol, a new high relaxivity GBCA, in healthy subjects and patients with brain lesions (phase I/IIa study). *Invest Radiol* 2019; 54: 396-402.
- Harpur ES, Worah D, Hals PA, Holtz E, Furuhashi K, Nomura H. Preclinical safety assessment and pharmacokinetics of gadodiamide injection, a new magnetic resonance imaging contrast agent. *Invest Radiol* 1993; 28 (Suppl 1): S28-S43.
- Hartwig P, Mützel W, Tänzler V. Pharmacokinetics of iohexol, iopamidol, iopromide, and iosimide compared with meglumine diatrizoate. *Fortschr Geb Rontgenstrahlen Nuklearmed Ergänzungsbd* 1989; 128: 220-223.
- Heglund IF, Michelet AA, Blazak WF, Furuhashi K, Holtz E. Preclinical pharmacokinetics and general toxicology of iodixanol. *Acta Radiol Suppl* 1995; 399: 69-82.
- Hergan K, Doring W, Längle M, Oser W. Effects of iodinated contrast agents in MR imaging. *Eur J Radiol* 1995; 21: 11-17.
- Jenkins JR, Robinson JW, Sisk L, Fullerton GD, Williams RF. Proton relaxation enhancement associated with iodinated contrast agents in MR imaging of the CNS. *AJNR Am J Neuroradiol* 1992; 13: 19-27.
- Joffe P, Thomsen HS, Meusel M. Pharmacokinetics of gadodiamide injection in patients with severe renal insufficiency and patients undergoing hemodialysis or continuous ambulatory peritoneal dialysis. *Acad Radiol* 1998; 5: 491-502.
- Kaufman JA, Geller SC, Waltman AC. Renal insufficiency: gadopentetate dimeglumine as a radiographic contrast agent during peripheral vascular interventional procedures. *Radiology* 1996; 198: 579-581.
- Kim MD, Kim H. Gadolinium dimeglumine as a contrast agent for digital subtraction angiography: in vitro Hounsfield unit measurement and clinical efficacy. *Yonsei Med J* 2003; 44: 138-142.

- Kopka L, Funke M, Fischer U, Vosschenrich R, Schröder M, Grabbe E. Signal characteristics of X-ray contrast media and their interaction with gadolinium-DTPA in MRT. *Fortschr Geb Röntgenstrahlen Nuklearmed* 1994; 160: 349-352.
- Krause W, Schuhmann-Giampieri G, Staks T, Kaufmann J. Dose proportionality of iopromide pharmacokinetics and tolerability after i.v. injection in healthy volunteers. *Eur J Clin Pharmacol* 1994; 46: 339-343.
- Krestin GP, Schuhmann-Giampieri G, Haustein J, et al. Functional dynamic MRI, pharmacokinetics and safety of Gd-DTPA in patients with impaired renal function. *Eur Radiol* 1992; 2: 16–23.
- Kwon C, Kang KM, Choi YH, Yoo RE, Sohn CH, Han SS, Yoon SH. Renal safety of repeated intravascular administrations of iodinated or gadolinium-based contrast media within a short interval. *Korean J Radiol* 2021; 22: 1547-1554.
- LaFrance ND, Parked JR, Lucas TR, et al. Clinical investigation of the safety and pharmacokinetics of gadoteridol injection in renally-impaired patients or patients requiring hemodialysis. *Proc Int Soc Magn Reson Med.* 1995; 1995: 251–300.
- Lancelot E. Revisiting the pharmacokinetic profiles of gadolinium-based contrast agents: Differences in long-term biodistribution and excretion. *Invest Radiol* 2016; 51: 691-700.
- Le Mignon MM, Chambon C, Warrington S, et al. Gd-DOTA. Pharmacokinetics and tolerability after intravenous injection into healthy volunteers. *Invest Radiol* 1990; 25: 933–937.
- Lorusso V, Luzzani F, Bertani F, Tirone P, de Haën C. Pharmacokinetics and tissue distribution of iomeprol in animals. *Eur J Radiol* 1994; 18 (Suppl 1): S13-S20.
- Lorusso V, Arbughi T, Tirone P, de Haën C. Pharmacokinetics and tissue distribution in animals of gadobenate ion, the magnetic resonance imaging contrast enhancing component of gadobenate dimeglumine 0.5 M solution for injection (MultiHance). *J Comput Assist Tomogr.* 1999; 23 (Suppl 1): S181-S189.
- Lorusso V, Taroni P, Alvino S, Spinazzi A. Pharmacokinetics and safety of iomeprol in healthy volunteers and in patients with renal impairment or end-stage renal disease requiring hemodialysis. *Invest Radiol* 2001; 36: 309-316.
- McKinstry DN, Rommel AJ, Sugerman AA. Pharmacokinetics, metabolism, and excretion of iopamidol in healthy subjects. *Invest Radiol* 1984; 19 (Suppl 5): S171-S174.
- McLachlan SJ, Eaton S, De Simone DN. Pharmacokinetic behaviour of gadoteridol injection. *Invest Radiol* 1992; 27 (Suppl 1): S12-S15.
- Michel A, Bonnet PA, Fernandez JP, Chambon C, Doucet D. Pharmacokinetic study of gadolinium-DOTA in control and streptozocin diabetic rats. *J Pharm Pharmacol* 1992; 44: 902-906.
- Montgomery DD, Morrison WB, Schweitzer ME, Weishaupt D, Dougherty L. Effects of iodinated contrast and field strength on gadolinium enhancement: implications for direct MR arthrography. *J Magn Reson Imaging* 2002; 15: 334-343.
- Morales H, Lemen L, Samaritunga R, Nguyen P, Tomsick T. Effects of iodinated contrast on various magnetic resonance imaging sequences and field strength: Implications for characterization of hemorrhagic transformation in acute stroke therapy. *World J Radiol* 2016; 8: 588-593.
- Morin JP, Boutelet I, Toutain H, Fillastre JP. Pharmacokinetics and renal accumulation of three iodinated contrast agents. A comparative study of Telebrix, Hexabrix and Omnipaque in the rabbit. *Drugs Exp Clin Res* 1988; 14: 679-686.
- Mühler A, Heinzelmann I, Weinmann HJ. Elimination of gadolinium-ethoxybenzyl-DTPA in a rat model of severely impaired liver and kidney excretory function. An experimental study in rats. *Invest Radiol* 1994; 29: 213-216.

- Mühler A, Weinmann HJ. Biodistribution and excretion of <sup>153</sup>Gd-labeled gadolinium ethoxybenzyl diethylenetriamine pentaacetic acid following repeated intravenous administration to rats. *Acad Radiol* 1995; 2: 313-318.
- Mützel W, Speck U. Pharmacokinetics and biotransformation of iohexol in the rat and the dog. *Acta Radiol Suppl* 1980; 362: 87-92.
- Mützel W, Speck U, Weinmann HJ. Pharmacokinetics of iopromide in rat and dog. *Fortschr Geb Röntgenstrahlen Nuklearmed Ergänzungsbd* 1983; 118: 85-90.
- Nossen JO, Jakobsen JA, Kjaersgaard P, Andrew E, Jacobsen PB, Berg KJ. Elimination of the non-ionic X-ray contrast media iodixanol and iohexol in patients with severely impaired renal function. *Scand J Clin Lab Invest* 1995; 55: 341-350.
- Nyman U, Elmståhl B, Leander P, Nilsson M, Golman K, Almén T. Are gadolinium-based contrast media really safer than iodinated media for digital subtraction angiography in patients with azotemia? *Radiology* 2002; 223: 311-318; discussion 328-329.
- Nyman U, Elmståhl B, Geijer H, Leander P, Almén T, Nilsson M. Iodine contrast iso-attenuating with diagnostic gadolinium doses in CTA and angiography results in ultra-low iodine doses. A way to avoid both CIN and NSF in azotemic patients? *Eur Radiol* 2011; 21: 326-336.
- Ogura A, Hayakawa K, Miyati T, Maeda F. Effects of iodinated contrast agent on diffusion weighted magnetic resonance imaging. *Acad Radiol* 2009; 16: 1196-1200.
- Olsson B, Aulie A, Sveen K, Andrew E. Human pharmacokinetics of iohexol. A new nonionic contrast medium. *Invest Radiol* 1983; 18: 177-182.
- Quinn AD, O'Hare NJ, Wallis FJ, Wilson GF. Gd-DTPA: an alternative contrast medium for CT. *J Comput Assist Tomogr* 1994; 18: 634-636.
- Reinton V, Berg KJ, Svaland MG, et al. Pharmacokinetics of gadodiamide injection in patients with moderately impaired renal function. *Acad Radiol* 1994; 1 (Suppl 1): S56-S61.
- Robic C, Port M, Rousseaux O, et al. Physicochemical and pharmacokinetic profiles of gadopicles: a new macrocyclic gadolinium chelate with high T1 relaxivity. *Invest Radiol* 2019; 54: 475-484.
- Schmitz SA, Wagner S, Schuhmann-Giampieri G, Wolf KJ. Evaluation of gadobutrol in a rabbit model as a new lanthanide contrast agent for computed tomography. *Invest Radiol* 1995; 30: 644-649.
- Schmitz SA, Wagner S, Schuhmann-Giampieri G, Krause W, Bollow M, Wolf KJ. Gd-EOB-DTPA and Yb-EOB-DTPA: two prototypic contrast media for CT detection of liver lesions in dogs. *Radiology* 1997; 205: 361-366.
- Schuhmann-Giampieri G, Krestin G. Pharmacokinetics of Gd-DTPA in patients with chronic renal failure. *Invest Radiol* 1991; 26: 975-979.
- Schuhmann-Giampieri G, Schmitt-Willich H, Press WR, Negishi C, Weinmann HJ, Speck U. Preclinical evaluation of Gd-EOB-DTPA as a contrast agent in MR imaging of the hepatobiliary system. *Radiology* 1992; 183: 59-64.
- Schuhmann-Giampieri G, Mahler M, Röhl G, Maibauer R, Schmitz S. Pharmacokinetics of the liver-specific contrast agent Gd-EOB-DTPA in relation to contrast-enhanced liver imaging in humans. *J Clin Pharmacol* 1997; 37: 587-596.
- Spencer CM, Goa KL. Iodixanol: A review of its pharmacodynamic and pharmacokinetic properties and diagnostic use as an X-ray contrast medium. *Drugs* 1996; 52: 899-927.
- Spinazzi A, Lorusso V, Pirovano G, Kirchin M. Safety, tolerance, biodistribution, and MR imaging enhancement of the liver with gadobenate dimeglumine: results of clinical pharmacologic and pilot imaging studies in nonpatient and patient volunteers. *Acad Radiol* 1999; 6: 282-291.
- Spinosa DJ, Angle JF, Hartwell GD, Hagspiel KD, Leung DA, Matsumoto AH. Gadolinium-based contrast agents in angiography and interventional radiology. *Radiol Clin North Am* 2002; 40: 693-710.

- Staks T, Schuhmann-Giampieri G, Frenzel T, et al. Pharmacokinetics, dose proportionality, and tolerability of gadobutrol after single intravenous injection in healthy volunteers. *Invest Radiol* 1994; 29: 709–715.
- Strunk HM, Schild H. Actual clinical use of gadolinium-chelates for non-MRI applications. *Eur Radiol* 2004; 14: 1055-1062.
- Svaland MG, Haider T, Langseth-Manrique K, Andrew E, Hals PA. Human pharmacokinetics of iodixanol. *Invest Radiol* 1992; 27: 130-133.
- Swan SK, Lambrecht LJ, Townsend R, et al. Safety and pharmacokinetic profile of gadobenate dimeglumine in subjects with renal impairment. *Invest Radiol* 1999; 34: 443–448.
- Thomsen HS, Almèn T, Morcos SK; Contrast Media Safety Committee Of The European Society Of Urogenital Radiology (ESUR). Gadolinium-containing contrast media for radiographic examinations: a position paper. *Eur Radiol* 2002; 12: 2600-2605.
- Tombach B, Bremer C, Reimer P, et al. Pharmacokinetics of 1M gadobutrol in patients with chronic renal failure. *Invest Radiol* 2000; 35: 35–40.
- Tombach B, Bremer C, Reimer P, Kisters K, Schaefer RM, Geens V, Heindel W. Renal tolerance of a neutral gadolinium chelate (gadobutrol) in patients with chronic renal failure: results of a randomized study. *Radiology* 2001; 218: 651-657.
- Tombach B, Heindel W. Value of 1.0- M gadolinium chelates: review of preclinical and clinical data on gadobutrol. *Eur Radiol* 2002; 12: 1550-1556.
- Tweedle MF, Eaton SM, Eckelman WC, Gaughan GT, Hagan JJ, Wedeking PW, Yost FJ. Comparative chemical structure and pharmacokinetics of MRI contrast agents. *Invest Radiol* 1988; 23 (Suppl 1): S236-S239.
- Van Wagoner M, O'Toole M, Worah D, Leese PT, Quay SC. A phase I clinical trial with gadodiamide injection, a nonionic magnetic resonance imaging enhancement agent. *Invest Radiol* 1991; 26: 980-986.
- Van Wagoner M, Worah D. Gadodiamide injection: first human experience with the nonionic magnetic resonance imaging enhancement agent. *Invest Radiol* 1993; 28 (Suppl 1): S44-S48.
- Vittadini G, Felder E, Tirone P, Lorusso V. B-19036, a potential new hepatobiliary contrast agent for MR proton imaging. *Invest Radiol* 1988; 23 (Suppl 1): S246-S248.
- Vogler H, Platzek J, Schuhmann-Giampieri G, Frenzel T, Weinmann HJ, Raduchel B, Press WR. Preclinical evaluation of gadobutrol: a new, neutral, extracellular contrast agent for magnetic resonance imaging. *Eur J Radiol* 1995; 21: 1-10.
- Wang JH, Ren K, Sun WG, Zhao L, Zhong HS, Xu K. Effects of iodinated contrast agents on renal oxygenation level determined by blood oxygenation level dependent magnetic resonance imaging in rabbit models of type 1 and type 2 diabetic nephropathy. *BMC Nephrol*. 2014; 15: 140.
- Wedeking P, Tweedle MF. Comparison of the biodistribution of  $^{153}\text{Gd}$ -labeled  $\text{Gd}(\text{DTPA})^{2-}$ ,  $\text{Gd}(\text{DOTA})$ , and  $\text{Gd}(\text{acetate})^n$  in mice. *Int J Rad Appl Instrum B* 1988; 15: 395-402.
- Wedeking P, Eaton S, Covell DG, Nair S, Tweedle MF, Eckelman WC. Pharmacokinetic analysis of blood distribution of intravenously administered  $^{153}\text{Gd}$ -labeled  $\text{Gd}(\text{DTPA})^{2-}$  and  $^{99\text{m}}\text{Tc}(\text{DTPA})$  in rats. *Magn Reson Imaging* 1990; 8: 567-575.
- Weinmann HJ, Laniado M, Mützel W. Pharmacokinetics of  $\text{GdDTPA}/\text{dimeglumine}$  after intravenous injection into healthy volunteers. *Physiol Chem Phys Med NMR* 1984; 16: 167-172.
- Wilkins RA, Whittington JR, Brigden GS, Lahiri A, Heber ME, Hughes LO. Safety and pharmacokinetics of ioversol in healthy volunteers. *Invest Radiol* 1989; 24: 781-788.
- Yoshikawa K, Davies A. Safety of Prohance in special populations. *Eur Radiol* 1997; 7 (Suppl 5): S246-S250.

Zwicker C, Langer M, Langer R, Keske U. Comparison of iodinated and noniodinated contrast media in computed tomography. Invest Radiol. 1991; 26 (Suppl 1): S162-S164; discussion S165-S166.

## Chapter 6 Prevention of Contrast-Induced Encephalopathy

### Clinical question

Which strategies are effective for prevention of Contrast-Induced Encephalopathy (CIE)?

### Introduction

Contrast-induced encephalopathy is a rare complication of the use of iodine-based contrast media (ICM), affecting the central nervous system. It has been associated with the administration of large volumes of ICM during endovascular interventions. This module aims to report on the optimal management of this complication as well as on strategies to prevent CIE.

### Search and select

A systematic review of the literature was performed to answer the following question: Which strategies are effective for prevention of Contrast-Induced Encephalopathy (CIE)?

- P (Patients):** Adult (>18 years) patients, with an indication for examination with intravenous or ICM administration.
- I (Intervention):** Prevention strategy - ICM administration with one type or volume of contrast medium.
- C (Comparison):** No prevention strategy (care as usual) - ICM administration with another type or volume of ICM.
- O (Outcome):** Contrast-induced encephalopathy, severity of CIE, neurotoxicity.

### Relevant outcome measures

The guideline development group considered contrast-induced encephalopathy as a critical outcome measure for decision making; and severity of CIE, neurotoxicity as important outcome measures for decision making.

The working group defined the outcome measure contrast induced encephalopathy as follows: a complication of intravenous or intra-arterial contrast administration resulting in a clinical deterioration, not caused by stroke, seizures, and other metabolic abnormalities, with oedematous changes on brain imaging, usually accompanied with contrast staining (Chu, 2020; Quintas-Neves, 2020).

### Search and select (Methods)

The databases Medline (via OVID) and Embase (via Embase.com) were searched with relevant search terms until July 20<sup>th</sup>, 2021. The detailed search strategy is depicted under the tab Methods. The systematic literature search resulted in 419 hits. Studies were selected based on the following criteria: the description of contrast induced encephalopathy or neurotoxicity after administration of contrast media and the comparison of one preventive strategy to another strategy. Nineteen studies were initially selected based on title and abstract screening. After reading the full text, no studies were included.

### Results

No studies were included in the analysis of the literature. Therefore, no systematic literature analysis could be performed.

### **Justifications – evidence to decision**

Contrast-induced encephalopathy is a complication of iodine-based contrast media (ICM) affecting the central nervous system. Usually, CIE is associated with intra-arterial administration of ICM during cardiac catheterization (Spina, 2017) or neuro-interventional procedures (Quintas-Neves, 2020), however, it can also occur after intravenous administration (Hinsenveld, 2017; Law, 2012). It can be challenging to distinguish CIE from thromboembolic stroke after endovascular procedures, of which the latter is a far more common complication. Patients may therefore be misdiagnosed and not adequately treated.

Symptoms arise within 24h after administration of ICM and include an altered mental status, focal neurological deficits, seizures, aphasia, and transient cortical blindness (Allison, 2021; Chu, 2020; Dunkley, 2021). It has been hypothesized that ICM disrupts the blood-brain barrier due to its hyperosmolarity, resulting in oedema and neurologic dysfunction (Chu, 2020; Dunkley, 2021; Matsubara, 2017; Kariyanna, 2020).

Diagnosis is often a combination of both clinical and radiologic findings. Imaging typically shows cortical and subcortical contrast enhancement on CT and vasogenic oedema on MRI. Dual Energy CT can differentiate haemorrhage from contrast staining (Chu, 2020).

Risk factors include haemodialysis, hypertension, previous stroke, diabetes mellitus, kidney disease, large volumes of ICM and previous adverse reactions (Allison, 2021; Matsubara, 2017). Renal dysfunction impairs clearance of contrast medium, and may result in more severe CIE, while previous stroke may already have disrupted blood-brain barriers (Chu, 2020; Matsubara, 2017; Zhang, 2020).

In most cases of CIE, spontaneously resolution of symptoms has been reported in several days with supportive care, although patients with permanent symptoms have also been described (Leong, 2012; Niimi, 2008; Shinoda, 2004; Zhao, 2019). Median time to recovery was reported to be around 30 hours (Kocabay, 2014).

The systematic research did not identify any comparative studies, but some potential preventative strategies have been proposed in the literature. Some advice to use low-osmolar ICM instead of iso- or high osmolar ICM, but in the recent years CIE has still been observed with low osmolar ICM and no comparative case-control studies have been performed (Kariyanna, 2020; Quintas-Neves, 2020, Spina, 2020). It has been reported that in most patients with CIE more than 100 ml ICM was administered. Limiting the amount of ICM administration or diluting ICM could be beneficial (Kariyanna, 2020).

One of the risk factors for developing CIE is renal dysfunction (Chu, 2020; Matsubara, 2017). It has been advocated that haemodialysis in patients with renal dysfunction might be beneficial in case of CIE, but no comparative studies have been performed (Matsubara, 2017). In the general population good hydration is generally advised around ICM administration (see protocol in [Safe Use of Contrast Media Part 1](#)), although it is uncertain if this can avoid CIE. Another risk factor is hypertension. Hypertension itself can also induce a hypertensive encephalopathy. Whether lowering blood pressure before ICM administration decreases the risk of CIE is unknown.

In case of CIE, corticosteroid treatment has been advocated (Allison, 2021). Corticosteroid treatment may be used as preventative treatment in patients who previously have developed CIE or as a treatment to resolve the neurological symptoms during CIE. Animal studies showed that premedication with low molecular weight dextran and corticosteroids reduced the neurotoxic effects of contrast media, due to prevention of blood cell



aggregation and decreased osmotic permeability of the blood brain barrier (Kariyanna, 2020). However, no studies in humans exist to date to support these findings.

A general recommendation is to closely observe patients directly after endovascular interventions, as most cases of CIE occur within the first few hours after intervention (Kocabay, 2014).

## Recommendations

*No comparative studies were identified to provide evidence-based strategies to avoid CIE. The recommendations below are based on expert opinions.*

Health care providers should be aware of the existence of Contrast-Induced Encephalopathy (CIE) following iodine-based contrast media administration.

Adequate prevention strategies have not been investigated in detail.

General advice for clinical practice:

1. Minimize the amount of iodine-based contrast media as much as possible during endovascular interventions.
2. Consider to hydrate patients with severe renal dysfunction (eGFR <30 ml/min/1.73m<sup>2</sup>) receiving iodine-based contrast media (see protocol in [Safe Use of Contrast Media Part 1](#)).
3. Closely monitor patients the first six hours after endovascular interventions for neurological symptoms and consult a neurologist immediately in case of neurological symptoms.
4. Depending on the clinical symptoms of contrast-induced encephalopathy, treatment with antiepileptic drugs, corticosteroids, intravenous hydration, and/or mannitol may be recommended.

## Literature

- Allison C, Sharma V, Park J, Schirmer CM, Zand R. Contrast-Induced Encephalopathy after Cerebral Angiogram: A Case Series and Review of Literature. *Case Rep Neurol.* 2021; 13(2): 405-413.
- Chu YT, Lee KP, Chen CH, Sung PS, Lin YH, Lee CW, Tsai LK, Tang SC, Jeng JS. Contrast-induced encephalopathy after endovascular thrombectomy for acute ischemic stroke. *Stroke.* 2020; 51(12): 3756-3759.
- Dunkley JC, Patel KH, Doodnauth AV, Kariyanna PT, Valery E, McFarlane SI. Contrast-induced encephalopathy post cardiac catheterization, a rare mimicry of acute stroke - case presentation and review of the literature. *Am J Med Case Rep.* 2021; 9(5): 291-294.
- Hinsenveld WH, Vos EM, Blom RJ, Langezaal LCM, Schonewille WJ. Uw diagnose. TNN Neuro-imaging. 2017; 118. 118-121.
- Kariyanna PT, Aurora L, Jayarangaiah A, Das S, Gonzalez JC, Hegde S, McFarlane IM. Neurotoxicity associated with radiological contrast agents used during coronary angiography: a systematic review. *Am J Med Case Rep.* 2020; 8(2): 60-66.

- Kocabay G, Karabay CY, Kalayci A, Akgun T, Guler A, Oduncu V, Tanboga IH, Izgi A, Kirma C. Contrast-induced neurotoxicity after coronary angiography. *Herz*. 2014; 39(4): 522-527.
- Law S, Panichpisal K, Demede M, et al. Contrast-induced neurotoxicity following cardiac catheterization. *Case Rep Med*. 2012; 2012: 267860.
- Leong S, Fanning NF. Persistent neurological deficit from iodinated contrast encephalopathy following intracranial aneurysm coiling. A case report and review of the literature. *Interv Neuroradiol*. 2012; 18(1): 33-41.
- Matsubara N, Izumi T, Miyachi S, Ota K, Wakabayashi T. Contrast-induced encephalopathy following embolization of intracranial aneurysms in hemodialysis patients. *Neurol Med Chir (Tokyo)*. 2017; 57(12): 641-648.
- Niimi Y, Kupersmith MJ, Ahmad S, Song J, Berenstein A. Cortical blindness, transient and otherwise, associated with detachable coil embolization of intracranial aneurysms. *AJNR Am J Neuroradiol*. 2008; 29(3): 603-607.
- Quintas-Neves M, Araújo JM, Xavier SA, Amorim JM, Cruz E Silva V, Pinho J. Contrast-induced neurotoxicity related to neurological endovascular procedures: a systematic review. *Acta Neurol Belg*. 2020; 120(6): 1419-1424.
- Shinoda J, Ajimi Y, Yamada M, Onozuka S. Cortical blindness during coil embolization of an unruptured intracranial aneurysm--case report. *Neurol Med Chir (Tokyo)*. 2004; 44(8): 416-419.
- Spina R, Simon N, Markus R, Muller DW, Kathir K. Contrast-induced encephalopathy following cardiac catheterization. *Catheter Cardiovasc Interv*. 2017; 90(2): 257-268.
- Zhang G, Wang H, Zhao L, Li T, Sun M, Zhang Y, Hu H, Teng G, Chen J, Jian Y, Liu J. Contrast-induced encephalopathy resulting from use of ioversol and iopromide. *Clin Neuropharmacol*. 2020; 43(1): 15-19.
- Zhao, W., Zhang, J., Song, Y. et al. Irreversible fatal contrast-induced encephalopathy: a case report. *BMC Neurol*. 2019; 19: 46.

## Chapter 7 Follow-up Strategies after Hypersensitivity Reactions to Contrast Media

This chapter is an update of the modules about hypersensitivity reactions in the earlier guideline [Safe Use of Contrast Media part 2](#).

Contents of chapter 7:

- Introduction to Hypersensitivity Reactions to Contrast Media (separate chapter in previous guideline)
- Supplement Definitions of Adverse Drug Reactions
- Module 7.1 In Vitro Tests in Patients with Hypersensitivity Reactions to Contrast Media (module 3 in guideline part 2)
- Module 7.2 Diagnostic Value of Skin Testing for Hypersensitivity Reactions to Contrast Media (module 4 guideline part 2)
- Module 7.3 Risk Factors of Hypersensitivity Reactions to Contrast Media (module 5.1 in guideline part 2)
- Module 7.4 Prophylactic Measures for Prevention of Recurrent Hypersensitivity Reactions to Contrast Media (module 5.2 in guideline part 2)
- Appendix 1 Flow Charts
- Appendix 2 Contrast Media Hypersensitivity: The Weber and Lalli Effects
- Appendix 3 Allergology Services in The Netherlands

### Introduction to Hypersensitivity Reactions to Contrast Media

*Disclaimer: This narrative review has been written by members of the Guideline Development Group so that non-specialized readers can follow the Modules 7.1-7.4 more easily. It was not part of the actual guideline process with structured literature analyses.*

The increased use of contrast media (CM) may give rise to an increased absolute number of total hypersensitivity reactions (HSR). The relative number of immediate HSR has decreased since the introduction of nonionic, low-osmolar ICM, while the number of non-immediate HSR is on the rise, due to an increased use of iso-osmolar ICM (Rosado Ingelmo, 2016).

#### Terminology and Definitions (see also [Supplement](#))

The following definitions and terminology are based on the standard terminology recommended by the World Allergy Organisation (Cordona, 2020; Demoly, 2014; Johansson, 2004). When dealing with CM, the term allergy should be avoided as much as possible.

*Hypersensitivity:* Objectively reproducible symptoms or signs, initiated by exposure to a defined stimulus that is tolerated by normal subjects.

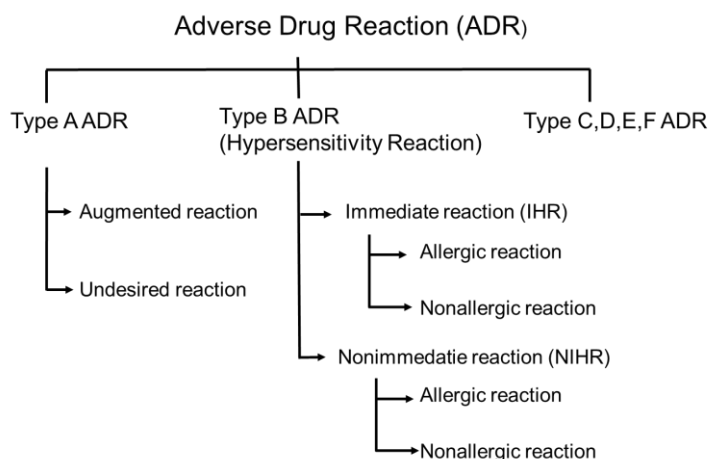
*Drug Hypersensitivity Reaction (DHR):* adverse effects of drugs that clinically resemble allergic reactions ('pseudo-allergic'). These include adverse reactions that are immune or nonimmune mediated.

*Drug Allergy:* Hypersensitivity reactions that are associated with an immune mechanism for which evidence can be shown in the form of drug-specific antibodies or activated T lymphocytes.

*Immediate (acute, early) hypersensitivity reaction to contrast media:* an adverse reaction that occurs within 1 hour of contrast agent injection. Acute reactions can either be allergy-like (IgE-mediated or not) hypersensitivity reactions or chemotoxic responses.

*Non-immediate (delayed, late) hypersensitivity reaction to contrast media:* an adverse reaction that occurs between 1 hour and 1 week after contrast agent injection.

**Figure 7.1 Schematic of adverse drug reaction types**



*Adverse drug reaction (ADR):* a response to a medicine which is noxious and unintended, and which occurs at doses normally used in man (WHO definition) (See Figure 7.1)

ADR can be classified in multiple types, and for contrast media types A, B and D are most relevant. Type A (augmented) reactions result from an exaggeration of a drug's normal pharmacological actions when given at the usual therapeutic dose and are normally dose dependent. These include all physiologic reactions. Type B (bizarre) reactions are novel responses that are not expected from the known pharmacological actions of the drug. These are less common, and so may only be discovered for the first time after a drug has already been made available for general use. These include allergic or non-allergic hypersensitivity reactions. Type D, or 'delayed' reactions, become apparent sometime after the use of a medicine. The timing of these may make them more difficult to detect. These include Nephrogenic Systemic Fibrosis (NSF) or iodine-induced hyperthyroidism (Edwards, 2000).

*Anaphylaxis:* Anaphylaxis is a severe, life-threatening systemic hypersensitivity reaction characterized by being rapid in onset with potentially life-threatening airway, breathing, or circulatory problems and is usually, although not always, associated with skin and mucosal changes (Cordona, 2020; WHO ICD-11 definition).

Anaphylaxis is highly likely when any one of the following 2 criteria are fulfilled (Cordona, 2020):

1. Acute onset of an illness (minutes to several hours) with simultaneous involvement of the skin, mucosal tissue, or both (e.g., generalized hives, pruritus or flushing, swollen lips-tongue-uvula)
  - And at least one of the following:
    - a) Respiratory compromise (e.g., dyspnoea, wheezing/bronchospasm, stridor, reduced PEF, hypoxemia)
    - b) Reduced blood pressure or associated symptoms of end-organ dysfunction (e.g., hypotonia [collapse], syncope, incontinence)

- c) Severe gastrointestinal symptoms (e.g., severe crampy abdominal pain, repetitive vomiting), especially after exposure to non-food allergens
2. Acute onset of hypotension<sup>a</sup> or bronchospasm<sup>b</sup> or laryngeal involvement<sup>c</sup> after exposure to a known or highly probable allergen<sup>d</sup> for that patient (minutes to several hours), even in the absence of typical skin involvement.

Note: a hypotension defined as a decrease in systolic BP greater than 30% from that person's baseline, or a systolic BP less than <90 mmHg. b. Excluding lower respiratory symptoms triggered by common inhalant allergens or food allergens perceived to cause "inhalational" reactions in the absence of ingestion. c. Laryngeal symptoms include stridor, vocal changes, odynophagia. d. An allergen is a substance (usually a protein) capable of triggering an immune response that can result in an allergic reaction. Most allergens act through an IgE-mediated pathway, but some non-allergen triggers can act independent of IgE (for example, via direct activation of mast cells).

## **Immediate hypersensitivity reactions to contrast media**

### Pathophysiology

Hypersensitivity reactions to CM are poorly understood. Recent research suggests that hypersensitivity reactions to nonionic CM are a heterogeneous disease. It can develop from multiple mechanisms such as IgE-dependent, complement dependent, direct membrane effects of CM, and possibly other mechanisms that have not been identified yet (Zhai, 2017). When an allergic drug reaction is suspected, DHR is the preferred term, because true drug allergy and nonallergic DHR may be difficult to differentiate based on the clinical presentation alone, especially in cases of acute severe DHR (Demoly, 2014).

Allergy-like hypersensitivity reactions may or may not be truly IgE-mediated. In general, allergy can be either antibody- or cell-mediated. Cell-mediated reactions usually occur after one or several days, while antibody-mediated reactions tend to be more immediate. A well-known reason for immediate reactions is the presence of antigen specific IgE antibodies attached to the surface of mast cells and basophil granulocytes. After cross-linking of IgE antibodies on the surface of these cells, a degranulation process follows, resulting in production of histamine and many other mediator substances. Other stimuli can also cause degranulation such as the degree of ionization, osmolality, and temperature of the injected solution. Some drugs such as fluoroquinolones are known to cause histamine release without the presence of specific IgE, via non-IgE-dependent activation routes of the mast cell (McNeil, 2015).

Compared to reactions to iodine-based CM, reactions to gadolinium-based CA are more frequently IgE-mediated, and thus true allergic reactions (Clement, 2018).

Remember: Not all symptoms experienced by patients in the hour after contrast agent injections are adverse reactions to the contrast agent. Patient anxiety may cause symptoms after contrast agent administration, known as the Lalli effect (Lalli, 1974).

### Clinical features and risk factors

The same acute adverse reactions are seen after intravascular administration of iodine-based contrast media and after gadolinium-based contrast agents or ultrasound contrast agents.

The term *adverse drug reaction (ADR)* is wider than hypersensitivity reactions, and includes several chemotoxic effects of CM injection (ADR type A), such as a feeling of warmth, dry mouth, or mild pain during injection, etc. Therefore, incidence figures between studies on

hypersensitivity reactions and studies on ADR (for example post-marketing surveillance studies) can vary.

In Radiology, hypersensitivity reactions are usually discriminated into mild, moderate, or severe reactions as outlined below. It must be realized that in Allergology other classifications are used, discriminating reactions as allergic, non-allergic, or type A adverse reactions (see Figure 7.1 and Torres, 2021).

The chance that a reaction can be classified as allergic is lower when the reaction is mild or moderate. It is important to note that re-exposure to CM after an initial mild reaction never causes a moderate or severe reaction (Lee, 2017; Davenport, 2009).

Mild reactions include *allergy-like* hypersensitivity reactions such as scattered urticaria/pruritus, limited cutaneous oedema, itchy/scratchy throat, nasal congestion, and sneezing/conjunctivitis/ rhinorrhoea. This category also includes *physiologic* reactions such as limited nausea/vomiting, transient flushing/warmth/chills, headache/dizziness/anxiety, altered taste, mild hypertension or spontaneously resolving vasovagal reactions (ACR, 2022; ESUR, 2018; Wang, 2008).

Moderate reactions include *allergy-like* reactions such as diffuse urticaria/pruritus, diffuse erythema with stable vital signs, facial oedema without dyspnoea, throat tightness/hoarseness without dyspnoea, and mild wheezing/bronchospasm. *Physiologic* reactions include protracted nausea/vomitus, hypertensive urgency, isolated chest pain, and vasovagal reactions responsive to treatment (ACR, 2022; ESUR, 2018; Wang, 2008).

Severe reactions include *allergy-like* reactions such as diffuse erythema with hypotension, diffuse/facial oedema with dyspnoea, laryngeal oedema with stridor, and severe wheezing/bronchospasm with hypoxia, and generalized anaphylactic reaction/shock. Severe *physiologic* reactions include treatment-resistant vasovagal reactions, arrhythmia, hypertensive emergencies, and convulsions/seizures. Also, to this category belong pulmonary oedema and cardiopulmonary arrest (ACR, 2022; ESUR, 2018; Wang, 2008).

#### Risk factors

Risk factor analysis is often done by retrospective observational studies without control groups (see also [chapter 7.3](#)). Risk factors for hypersensitivity are not fully established. Additional risk factors for immediate HSR that are common to allergic drug reactions include poorly controlled bronchial asthma, concomitant medications (e.g., ACE inhibitors,  $\beta$ -blockers, and proton pump inhibitors), rapid administration of the drug, mastocytosis, autoimmune diseases, and viral infections (Rosado Ingelmo, 2016).

In Radiology literature, the most consistently reported risk factors for hypersensitivity reactions to CM are (ACR, 2022):

1. A prior hypersensitivity reaction to contrast media.
2. A history of allergy, particularly multiple severe allergies (atopy).
3. A history of asthma requiring treatment.

Female gender could not be substantiated as an independent risk factor for hypersensitivity reactions, but age may be relevant (Endrikat, 2022).

## **Incidence of acute hypersensitivity reactions**

### Incidence after iodine-based contrast media

The incidence is highest after iodine-based contrast media and lowest after ultrasound contrast agents. The incidence of acute adverse reactions has declined considerably after the introduction of low-osmolar and iso-osmolar iodine-based contrast media (ACR, 2022; ESUR, 2018).

In the early days of low-osmolar media, the classic Japanese study (Katayama, 1990) reported relatively high adverse drug reaction rates after nonionic CM of up to 3,1%, with severe and very severe reactions occurring in 0,44%. In contrast, more recent studies with large patient cohorts focusing more specifically on hypersensitivity (allergic-like) reactions have shown considerably lower incidence rates of 0,15 to 0,69% with severe reactions occurring in 0,005 to 0,013% (Hunt, 2009; Mortelet, 2005; Wang, 2008).

Hypersensitivity reactions after non-vascular CM administration (either oral, rectal, intraductal, intravesical or intra-articular) are rare (see also the overview in [Safe Use of Contrast Media, part 2](#)). Such reactions occur slower, and the incidence is much lower than after intravascular administration and will be influenced by the integrity and condition of the wall of the cavity into which the contrast agent is administered (for example inflamed mucosa may lead to leakage into the intravascular compartment). Nevertheless, severe reactions can occur, even with non-vascular CM administration (Davis, 2015).

### Incidence using specific iodinated contrast media

Large post-marketing surveillance studies of iobitridol and iodixanol have shown acute adverse events of 0,58-0,59% with severe events in 0,004 to 0,010% (Maurer, 2011; Zhang, 2014). A third study using iopromide is more difficult to compare due to different definitions, and had higher rates of 2,49% and 0,034%, respectively (Palkowitsch, 2014). It must be noted that physiologic reactions (feeling of warmth, metallic taste) make up a considerable part of these events.

More recently, the hypersensitivity reaction rate after iopromide was 0,74% in adults and 0,38% in elderly (Endrikat, 2022). In the same study population, the hypersensitivity reaction rate was 0.7% after intravenous administration vs. 0.2% after intra-arterial administration (Endrikat, 2020).

In addition, several retrospective observational studies have looked at differences in acute hypersensitivity rates among iodine-based CM. Although imperfect, these studies indicate a somewhat higher rate for iopromide and iomeprol compared to other CM (An, 2019; Gomi, 2010; Kim, 2017; Seong, 2014). It remains controversial whether iobitridol has a lower percentage, as indicated in one study (Kim, 2017).

### Incidence after gadolinium-based contrast agents

Recent studies in large adult patient cohorts focusing on hypersensitivity (allergic-like) reactions have shown low incidence rates of 0,06-0,17% with severe reactions occurring in 0,003-0,006% (Aran, 2015; Behzadi, 2018; Dillman, 2007; Prince, 2011). More recent studies showed overall rates of 0,15-0,40%. For severe reactions rates were 0,002-0,004% in general populations and 0,033% in a population undergoing cardiac MRI (Ahn, 2022; McDonald, 2019; Uhlig, 2019).

In a large meta-analysis, the overall rate was 92 per 100,000 gadolinium-based contrast agent (GBCA) injections (0,09%) with severe reactions occurring in 5,2 per 100,000 injections

(0,005%). It was shown that the type of GBCA is of influence on the number of reactions. Linear nonionic GBCA had an incidence of 15 per 100,000 and linear ionic GBCA of 52 per 100,000. However, these GBCA are no longer available in Europe. The macrocyclic GBCA had slightly higher rates, macrocyclic ionic GBCA 90 per 100,000 and macrocyclic nonionic GBCA 160 per 100,000. The highest rate was for linear ionic GBCA with protein-binding, 170 per 100,000 injections (Behzadi, 2018).

Comparing specific GBCA, in one study more hypersensitivity reactions occurred after gadobenate and gadobutrol compared with gadodiamide or gadoterate injection (McDonald, 2019), while in another study most acute reactions occurred with gadoteridol and most delayed reactions with gadoterate (Ahn, 2022).

### **Breakthrough, protracted and biphasic hypersensitivity reactions**

So-called “breakthrough” hypersensitivity reactions are recurring reactions despite premedication with corticosteroids and H1-antihistamines. The occurrence in published series is variable, 2 to 17%. These reactions are most often of similar severity as the original (culprit) reaction for which premedication was prescribed. Breakthrough reactions can be severe in incidental cases. Unfortunately, no data on the number of IgE-mediated reactions are available (Davenport, 2009; Mervak, 2015).

While most hypersensitivity reactions to CM are uniphasic, other patterns may also occur. A *protracted* reaction is defined as a reaction lasting > 5h in which symptoms incompletely resolve. This pattern is rare following CM, occurring in only 4% of anaphylactic (severe) reactions and may be predicted by a low responsiveness to initial adrenaline therapy (Kim, 2018).

A *biphasic* reaction is defined as a reaction recurring 0 to 72h after an initial hypersensitivity reaction. The median time for start of the second reaction is 8 to 12h after the first reaction. This pattern is also rare, occurring in 10% of anaphylactic (severe) reactions (Rohacek, 2014). Usually, the second reaction is of similar severity or milder than the initial reaction. Predictors for biphasic anaphylaxis are severe initial symptoms requiring adrenaline redosing or a long (> 40 min) duration of the initial reaction. An observation time of 6-12h after the initial anaphylactic reaction has resolved is practical (Lee, 2016; Kim, 2018 and 2019). The use of corticosteroids in this setting is controversial and is not recommended (Gabrielli 2019; Lee, 2016; Simons, 2015).

For ultrasound contrast agents the risk is low, but no large series have been published to date. Most adverse reactions are cardiovascular, and the incidence of hypersensitivity reactions is 0,009% with severe reactions occurring in 0,004% (Khawaja, 2010).

### **Classification**

Historically, hypersensitivity reactions to CM have been graded as mild, moderate, or severe. This radiological classification shows overlap with other used classifications, such as the World Allergy Organisation (WAO) classification (Johansson, 2004) and modifications of the Ring - Messmer classification of allergic reactions (Ring, 1977; Table 7.1).



**Table 7.1 Severity grading of anaphylactic reactions (modified Ring and Messmer)**

Grade	Skin	Abdomen	Airways	Cardiovascular
I	Itch Flush Urticaria Angioedema	-	-	-
II	Itch Flush Urticaria Angioedema	Nausea Cramps	Rhinorrhoea Hoarseness Dyspnoea	Tachycardia (> 20 bpm) Hypertension (>20 mm Hg) Arrhythmia
III	Itch Flush Urticaria Angioedema	Vomiting Defecation	Laryngeal oedema Bronchospasm Cyanosis	Shock
IV	Itch Flush Urticaria Angioedema	Vomiting Defecation	Respiratory arrest	Cardiac arrest

*Classification according to the most severe symptom, no symptom is mandatory*

A practical summary classification of acute hypersensitivity reactions to contrast media for radiological practices may be (free after ACR, 2022; ESUR, 2018):

- Mild:** Itching, sneezing, flushing, conjunctivitis, rhinorrhoea, epiphora, nausea, short-duration, or incidental vomiting, altered taste, limited (localized) scattered urticaria.
- Moderate:** Generalized or extensive urticaria, diffuse erythema without hypotension, facial or angioedema without dyspnoea, mild wheezing/bronchospasm, protracted vomiting, mild isolated hypotension.
- Severe:** Severe wheezing/bronchospasm, profound hypotension, pulmonary oedema, generalized anaphylactic reaction, seizures/convulsions, respiratory arrest, and cardiac arrest.

It is important to note that re-exposure to CM after an initial mild reaction never causes a moderate or severe reaction (Lee, 2017; Davenport, 2009). In addition to this, the risk of an IgE-mediated allergic reaction (and thus the risk of severe reactions in case of re-exposure) is low in moderate reactions without cutaneous symptoms. Therefore, in the classification most used in allergology only reactions with cutaneous symptoms (urticaria or angioedema) are classified as allergic-like (Torres, 2021).

### **Nonimmediate (late, delayed) hypersensitivity reactions to Contrast Media**

#### **Clinical features**

A nonimmediate hypersensitivity reaction (NIHR) is a delayed hypersensitivity reaction > 1h after contrast administration (usually > 24h). NIHR usually presents as a maculopapular exanthema (MPE): skin rash consisting of patches (maculae) and nodules (papulae) spread over body and extremities. It normally heals within days to weeks, and if treatment is required, topical or oral steroids can be applied.

Many patients show a variety of nonspecific symptoms, which include headache, nausea, dizziness, gastro-intestinal upset, mild fever, and arm pain (Bellin, 2011; Christiansen, 2000). When compared to control populations (Loh, 2010), skin rashes with erythema and swelling are the most frequent true nonimmediate hypersensitivity reactions. Most patients present with cutaneous symptoms like other drug-induced skin eruptions, usually in the form of a

macular or maculopapular exanthema. The exanthema usually occurs 2 to 10 days after first exposure to ICM and 1 to 2 days after re-exposure to the same ICM. Most reactions are mild to moderate in severity, are usually self-limiting and resolve within 1 week (Bellin, 2011).

Discrimination should be made between mild-to-moderate NIHR and rare severe NIHR with danger signs, the so-called severe cutaneous adverse drug reactions (SCAR), such as drug reaction with eosinophilia and systemic symptoms (DRESS) syndrome, toxic epidermal necrolysis (TEN), acute generalized exanthemic pustulosis (AGEP), and Stevens-Johnson syndrome (SJS) (Brockow, 2019; Soria, 2021).

### **Pathophysiology**

There is evidence that drug-specific T-cells play an important role in nonimmediate hypersensitivity reactions. In skin reactions an infiltrate in the dermis consisting of activated CD4<sup>+</sup> or CD8<sup>+</sup> T-cells and eosinophils is usually found (Christiansen, 2000 and 2003; Schönmann, 2020).

*In vitro* studies have shown two different pathways of CM recognition which both require major histocompatibility complex (MHC) molecules for stimulation: a) direct binding of CM to the T-cell receptor or MHC molecule (p-i concept), and b) after uptake and processing by antigen-presenting cells and presented to T-cells via MHC-II molecules ((pro)hapten concept) (Keller, 2009).

The hapten-independent pathway could explain results of cross-reactivity analyses that revealed that CM-specific activated T-cell clones reacted to CM with shared structural elements.

It has been postulated that CM do not induce a primary immune response, but instead interact with receptors on activated memory T-cells raised against other foreign substances (non-allergic NIHR). Patients with nonimmediate hypersensitivity should not be at risk for an immediate hypersensitivity reaction (mediated by IgE or other mechanisms) upon re-exposure to CM.

### **Risk factors**

Established risk factors for nonimmediate hypersensitivity reactions to iodine-based CM include a previous hypersensitivity reaction and IL-2 immunotherapy. Most CM-associated nonallergic NIHR are associated with iso-osmolar CM (ACR, 2022; Bellin, 2011; ESUR, 2018).

Patients with a history of nonimmediate hypersensitivity reactions to ICM are not at increased risk for immediate HSR to ICM as these reactions are mechanistically unrelated (Christiansen, 2003; Mazori, 2018).

### **Incidence of nonimmediate hypersensitivity reactions**

The frequency of nonimmediate hypersensitivity reactions to CM varies greatly between studies and is believed to be between 1-3% of patients after iodine-based CM administration and only very rarely after gadolinium-based CA administration (Bellin, 2011; Christiansen, 2000).

#### Incidence using specific iodine-based CM

Nonimmediate skin reactions tend to be more common after iodixanol (Benin, 2011; Sutton, 2003). The incidence of nonimmediate hypersensitivity reactions is not significantly different for the other iodine-based low-osmolar CM (Bellin, 2011).

## Cross-reactivity between contrast media

### Cross-reactivity between iodine-based CM

Most of the current cross-reactivity data come from skin testing. Cross-reactivity in late hypersensitivity reactions is probably caused by the presence of CM-specific T-cells, some of which may show a broad cross-reactivity pattern. There may be a link between the chemical structure of iodine-based CM and the pattern of cross-reactivity, but results are inconsistent.

Several studies have shown considerable cross-reactivity between different iodine-based CM, but specific data on immediate versus nonimmediate hypersensitivity reactions are lacking until now. In the larger studies, most cross-reactivity has been seen between the nonionic dimer iodixanol and its monomer iohexol, with relatively fewer positive skin reactions with iobitridol (Clement, 2018; Hasdenteufel, 2011; Lerondeau, 2016; Yoon, 2015).

Based on cross-reactivity patterns iodine-based CM may be divided in three groups, with relatively high intra-group cross-reactivity but less intergroup cross-reactivity (Lerondeau, 2016). Based on additional data, it seems reasonable to add iopromide to group A as well and possibly remove ioxithalamate and iopamidol (Schrijvers, 2018).

Table 7.2 may be helpful for selecting an alternative agent for imaging studies.

**Table 7.2 Cross-reactivity grouping of iodine-based CM (Lerondeau, 2016)**

Group A	Group B	Group C
Ioxithalamate (Telebrix)	Iobitridol (Xenetix)	Amidotrizoate (Gastrografin)
Iopamidol (Iopamiro)	Ioxaglate (Hexabrix)	
Iodixanol (Visipaque)		
Iohexol (Omnipaque)		
Ioversol (Optiray)		
Iomeprol (Iomeron)		
Iopromide (Ultravist)		

*Note: Iopamidol and Ioxaglate are no longer available on the market in The Netherlands*

### Cross-reactivity between gadolinium-based CM

Information on cross-reactivity between GBCA is limited to case reports. Skin testing and provocation tests in such cases have shown that cross-reactivity among macrocyclic GBCA may be more extensive than among linear GBCA (Gallardo Higuera, 2021; Grüber, 2021).

### Cross-reactivity between iodine-based and gadolinium-based CM

A recent study examined the risk of reactions to both iodine-based CM and gadolinium-based CA in the same patient in a large patient cohort. The incidence of primary hypersensitivity reactions was 0,047% and the incidence of secondary reactions 0,024%. Nearly all reactions were mild, requiring no treatment. Therefore, cross-reactivity between iodine-based and gadolinium-based CM is an extremely rare event (Sodagari, 2018).

## **Literature**

Ahn YH, Kang DY, Park SB, Kim HH, Kim HJ, Park GY, et al. Allergic-like hypersensitivity reactions to Gadolinium-Based Contrast Agents: an 8-year cohort study of 154 539 patients. *Radiology* 2022; 303(2): 329-336.

American College of Radiology. ACR Manual on contrast media, v2022. Available at: [\[URL\]](#). Accessed: 22. May 2022.

- An J, Jung H, Kwon OY, Kang Y, Lee JH, Won HK, et al. Differences in adverse reactions among iodinated contrast media: analysis of the KAERS database. *J Allergy Clin Immunol Pract* 2019; 7: 2205-2211.
- Aran S, Shaqdan KW, Abujudeh HH. Adverse allergic reactions to linear ionic gadolinium-based contrast agents: experience with 194,400 injections. *Clin Radiol* 2015; 70: 466-475.
- Behzadi AH, Zhao Y, Farooq Z, Prince MR. Immediate allergic reactions to gadolinium-based contrast agents: systematic review and meta-analysis. *Radiology* 2018; 286: 471-482.
- Bellin MF, Stacul F, Webb JAW, Thomsen HS, Morcos SK, Almén T, et al. Late adverse reactions to iodine-based contrast media: an update. *Eur Radiol* 2011; 21: 2305-2310.
- Brockow K, Ardern-Jones MR, Mockenhaupt M, Aberer W, Barbaud A, Caubet JC, et al. EAACI position paper on how to classify cutaneous manifestations of drug hypersensitivity. *Allergy* 2019; 74: 14-27.
- Cardona V, Ansotegui IJ, Ebisawa M, El-Gamal Y, Fernandez Rivas M, Fineman S, et al. World allergy organization anaphylaxis guidance 2020. *World Allergy Organ J.* 2020; 13(10): 100472.
- Christiansen C, Pichler WJ, Skotland T. Delayed allergy-like reactions to X-ray contrast media: mechanistic considerations. *Eur Radiol* 2000; 10: 1965-1975.
- Christiansen C. Current knowledge regarding the pathophysiology of the late adverse reactions to X-ray contrast media. GE Healthcare, 2003.
- Clement O, Dewachter P, Mouton-Faivre C, Nevoret C, Guilloux L, Bloch Morot E, et al. Immediate hypersensitivity to contrast agents: The French 5-year CIRTACI study. *EClinicalMedicine.* 2018; 1: 51-61.
- European Society of Urogenital Radiology Contrast Media Safety Committee. ESUR Guidelines on contrast safety, v10, 2018. Available at: [\[URL\]](#). Accessed: 22. May 2022.
- Davenport MS, Cohan RH, Caoili EM, Ellis JH. Repeat contrast medium reactions in premedicated patients: frequency and severity. *Radiology* 2009; 253: 372-379.
- Davis L. Anaphylactoid reactions to the nonvascular administration of water-soluble iodinated contrast media. *AJR Am J Roentgenol* 2015; 2014: 1140-1145.
- Demoly P, Adkinson NF, Brockow K, Castells M, Chiriac AM, Greenberger PA, et al. International Consensus on drug allergy. *Allergy* 2014; 69: 420-437.
- Dillman JR, Ellis JH, Cohan RH, Strouse PJ, Jan SC. Frequency and severity of acute allergic-like reactions to gadolinium-containing i.v. contrast media in children and adults. *AJR Am J Roentgenol* 2007; 189(6): 1533-1538.
- Edwards IR, Aronson JK. Adverse drug reactions: definitions, diagnosis, and management. *Lancet* 2000; 356(9237): 1255-1259.
- Endrikat J, Michel A, Kölbach R, Lengsfeld P, Vogtländer K. Risk of hypersensitivity reactions to iopromide after intra-arterial versus intravenous administration: a nested case-control analysis of 133,331 patients. *Invest Radiol* 2020; 55: 38-44.
- Endrikat J, Chernova J, Gerlinger C, Pracz M, Lengsfeld P, Bhatti A, Michel A. Risk of hypersensitivity reactions to iopromide in children and elderly: an analysis of 132,850 patients from 4 observational studies and pharmacovigilance covering >288 million administrations. *Invest Radiol* 2022; 57(5): 318-326.
- Gabrielli S, Clarke A, Morris J, Eisman H, Gravel J, Enarson P, et al. Evaluation of prehospital management in a Canadian emergency department anaphylaxis cohort. *J Allergy Clin Immunol Pract* 2019; 7: 2232-2238.e3.
- Gallardo-Higueras A, Moreno EM, Muñoz-Bellido FJ, Laffond E, Gracia-Bara MT, Macias EM, et al. Patterns of cross-reactivity in patients with immediate hypersensitivity reactions to gadobutrol. *J Invest Allergol Clin Immunol.* 2021; 31: 504-506.

- Gomi T, Nagamoto M, Hasegawa M, Katoh A, Sugiyama M, Murata N, et al. Are there any differences in acute adverse reactions among five nonionic iodinated contrast media? *Eur Radiol* 2010; 20: 1631-1635.
- Grüber HP, Helbling A, Jörg L. Skin test results and cross-reactivity patterns in IgE- and T-cell-mediated allergy to gadolinium-based contrast agents. *Allergy Asthma Immunol Res* 2021; 13: 933-938.
- Hasdenteufel F, Waton J, Cordebar V, Studer M, Collignon O, Luyasu S, et al. Delayed hypersensitivity reactions caused by iodixanol: an assessment of cross-reactivity in 22 patients (letter). *J Allergy Clin Immunol* 2011; 128: 1356-1357.
- Hunt CH, Kallmes DF, Thielen KR. Frequency and severity of adverse effects of iodinated and gadolinium contrast materials: retrospective review of 456,930 doses. *AJR Am J Roentgenol* 2009; 193: 1124-1127.
- Johansson SG, Bieber T, Dahl R, Friedmann PS, Lanier BQ, Lockey RF, et al. Revised nomenclature for allergy for global use: Report of the Nomenclature Review Committee of the World Allergy Organisation, October 2003. *J Allergy Clin Immunol* 2004; 113: 832-836.
- Katayama H, Yamguchi K, Kozuka T, Takashima T, Seez P, Matsuura K. Adverse reactions to ionic and nonionic contrast media. A report from the Japanese committee on the safety of contrast media. *Radiology* 1990; 175: 621-628.
- Keller M, Lerch M, Britschi M, Tache V, Gerber BO, Luthi M, et al. Processing-dependent and -independent pathways for recognition of iodinated contrast media by specific human T-cells. *Clin Exp Allergy* 2009; 40: 257-268.
- Khawaja OA, Sheikh KA, Al-Mallah MH. Meta-analysis of adverse cardiovascular events associated with echocardiographic contrast agents. *Am J Cardiol* 2010; 106: 742-747.
- Kim SR, Lee JH, Park KH, Park HJ, Park JW. Varied incidence of immediate adverse reactions to low-osmolar non-ionic iodide radiocontrast media used in computed tomography. *Clin Exp Allergy* 2017; 47: 106-112.
- Kim TH, Yoon SH, Lee SY, Choi YH, Park CM, Kang HR, Cho SH. Biphasic and protracted anaphylaxis to iodinated contrast media. *Eur Radiol* 2018; 28: 1242-1252.
- Kim TH, Yoon SH, Hong H, Kang HR, Cho SH, Lee SY. Duration of observation for detecting a biphasic reaction in anaphylaxis: a meta-analysis. *Int Arch Allergy Immunol* 2019; 179: 31-36.
- Lalli AF. Urographic contrast media reactions and anxiety. *Radiology* 1974; 112: 267-271.
- Lee S, Sadosty AT, Campbell RL. Update on biphasic anaphylaxis. *Curr Opin Allergy Clin Immunol* 2016; 16: 346-351.
- Lee SY, Yang MS, Choi YH, Park CM, Park HW, Cho SH, Kang HR. Stratified premedication strategy for the prevention of contrast media hypersensitivity in high-risk patients. *Ann Allergy Asthma Immunol*. 2017; 118(3): 339-344.e1.
- Lerondeau B, Trechot P, Waton J, Poreaux C, Luc A, Schmutz JL, et al. Analysis of cross-reactivity among radiocontrast media in 97 hypersensitivity reactions (letter). *J Allergy Clin Immunol* 2016; 137: 633-635.
- Loh S, Bagheri S, Katzberg RW, Fung MA, Li CS. Delayed adverse reaction to contrast-enhanced CT: a prospective single-center study comparison to control group without enhancement. *Radiology* 2010; 255:764–771.
- Maurer M, Heine O, Wolf M, Freyhardt P, Schnapauff D, Hamm B. Safety and tolerability of iobitridol in general and in patients with risk factors: results in more than 160,000 patients. *Eur J Radiol* 2011; 80: 357-362.
- Mazori DR, Nagler AR, Pomerantz MK. Delayed cutaneous reactions to iodinated contrast. *Cutis* 2018; 101: 433-435.

- McDonald JS, Hunt CH, Kolbe AB, Schmitz JJ, Hartman RP, et al. Acute adverse events following Gadolinium-Based Contrast Agent administration: a single-center retrospective study of 281,945 injections. *Radiology* 2019; 292: 620-627.
- McNeil BD, Pundir P, Meeker S, Han L, Udem BJ, Kulka M, Dong X. Identification of a mast-cell-specific receptor crucial for pseudo-allergic drug reactions. *Nature*. 2015; 519(7542): 237-241.
- Mervak BM, Davenport MS, Ellis JH, et al. Rates of breakthrough reactions in inpatients at high risk receiving premedication before contrast-enhanced CT. *AJR Am J Roentgenol*. 2015; 205: 77-84.
- Mortele KJ, Oliva MR, Ondategui S, Ros PR, Silverman SG. Universal use of nonionic iodinated contrast medium for CT: evaluation of safety in a large urban teaching hospital. *AJR Am J Roentgenol* 2005; 184:31-34.
- Palkowitsch PK, Bostelmann S, Lengsfeld P. Safety and tolerability of iopromide intravascular use: a pooled analysis of three non-interventional studies in 132,012 patients. *Acta Radiol* 2014, 55: 707-714.
- Prince MR, Zhang H, Zou Z, Staron RB and Brill PW. Incidence of immediate gadolinium contrast media reactions. *AJR Am J Roentgenol* 2011; 196: W138-W143.
- Ring J, Messmer K. Incidence and severity of anaphylactoid reactions to colloid volume substitutes. *Lancet* 1977; 1(8009): 466-469.
- Rohacek M, Edenhofer H, Bircher A, Bingisser R. Biphasic anaphylactic reactions: occurrence and mortality. *Allergy* 2014; 69: 791–797.
- Rosado Ingelmo A, Doña Diaz I, Cabañas Moreno R, et al. Clinical Practice Guidelines for Diagnosis and Management of Hypersensitivity Reactions to Contrast Media. *J Investig Allergol Clin Immunol* 2016; 26(3): 144-155.
- Schönmann C, Brockow K. Adverse reactions during procedures: Hypersensitivity to contrast agents and dyes. *Ann Allergy Asthma Immunol* 2020; 124: 156-164.
- Schrijvers R, Breynaert C, Ahmedali Y, Bourrain JL, Demoly P, Chiriac AM. Skin testing for suspected iodinated contrast media hypersensitivity. *J Allergy Clin Immunol Pract* 2018; 6: 1246-1254.
- Seong JM, Choi NK, Lee J, Chang Y, Kim YJ, Yang BR, et al. Comparison of the safety of seven iodinated contrast media. *J Korean Med Sci* 2013; 28: 1703-1710.
- Simons FE, Ebisawa M, Sanchez-Borges M, Thong BY, Worm M, Tanno LK, et al. 2015 update of the evidence base: World Allergy Organisation anaphylaxis guidelines. *World Allergy Organ J* 2015; 8: 32.
- Sodagari F, Mozaffary A, Wood III CG, Schmitz B, Miller FH, Yaghmai V. Reactions to both nonionic iodinated and gadolinium-based contrast media: incidence and clinical characteristics. *AJR Am J Roentgenol* 2018; 210: 1-5.
- Soria A, Amsler E, Bernier C, Milpied B, Tétart F, Morice C, et al.; FISARD group. DRESS and AGEP Reactions to Iodinated Contrast Media: A French Case Series. *J Allergy Clin Immunol Pract* 2021; 9: 3041-3050.
- Sutton AGC, Finn P, Campbell PG, et al. Early and late reactions following the use of iopamidol 340, iomeprol 350 and iodixanol 320 in cardiac catheterization. *J Invasive Cardiol* 2003; 15: 133-138.
- Torres MJ, Trautmann A, Böhm I, Scherer K, Barbaud A, Bavbek S, et al. Practice parameters for diagnosing and managing iodinated contrast media hypersensitivity. *Allergy* 2021; 76: 1325-1339.
- Uhlig J, Lücke C, Vliegenthart R, Loewe C, Grothoff M, Schuster A, et al.; ESCR MRCT Registry contributors. Acute adverse events in cardiac MR imaging with gadolinium-based contrast agents: results from the European Society of Cardiovascular Radiology (ESCR) MRCT Registry in 72,839 patients. *Eur Radiol*. 2019; 29(7): 3686-3695.

- Wang CL, Cohan RL, Ellis JH, Caoli EM, Wang G, Francis IR. Frequency, outcome, and appropriateness of treatment of nonionic iodinated contrast media reactions. *AJR Am J Roentgenol* 2008; 191: 409-415.
- Yoon SH, Lee SY, Kang HR, Kim JY, Hahn S, Park CM, et al. Skin tests in patients with hypersensitivity reaction to iodinated contrast media: a meta-analysis. *Allergy*. 2015; 70(6): 625-637.
- Zhai L, Guo X, Zhang H, Jin Q, Zeng Q, Tang X and Gao C. Nonionic iodinated contrast media related immediate reactions; A mechanism study of 27 patients. *Leg Med* 2017; 24: 56-62.
- Zhang BC, Hou L, Lv B, Xu YW. Post-marketing surveillance study with iodixanol in 20,185 Chinese patients from routine clinical practices. *Br J Radiol* 2014; 87: 20130325.

## Supplement: Definitions of Adverse Drug Reactions

*Disclaimer: This narrative supplement has been written by members of the Guideline Development Group so that non-specialized readers can follow the text more easily. It was not part of the actual guideline process with structured literature analyses.*

**Adverse drug reaction (ADR)**, synonyms: Adverse reaction, Suspected adverse (drug) reaction, Adverse effect, Undesirable effect (CIOMS IX)

A response to a medicinal product which is noxious and unintended. Response in this context means that a causal relationship between a medicinal product and an adverse event is at least a reasonable possibility. Adverse reactions may arise from use of the product within or outside the terms of the marketing authorisation or from occupational exposure. Conditions of use outside the marketing authorization include off-label use, overdose, misuse, abuse, and medication errors (EMA, 2017).

The terms “adverse reaction” and “adverse effect” are interchangeable, except that an adverse effect is seen from the point of view of the drug, whereas an adverse reaction is seen from the point of view of the patient (Edwards, 2000).

### **Toxic effect**

A toxic effect is an effect that occurs as an exaggeration of the desired therapeutic effect, and which is not common at normal doses. It occurs by the same mechanism as the therapeutic effect and is always dose related.

### **Side effect**

A side effect is any effect that is not the main aim of a therapy. Side effect include effects that may be beneficial rather than harmful. A side effect may or may not occur through the pharmacological action for which the drug is being used.

### **Unexpected adverse reaction**

An adverse reaction, the nature or severity of which is not consistent with domestic labelling or market authorisation, or expected from characteristics of the drug

### **Serious adverse effect**

Any untoward medical occurrence that at any dose results in death, requires hospital admission or prolongation of existing hospital stay, results in persistent or significant disability/incapacity, or is life threatening

- Cancers and congenital anomalies or birth defects should be regarded as serious
- Medical events that would be regarded as serious if they had not responded to acute treatment should also be considered serious
- The term ‘severe’ is often used to describe the intensity (severity) of a medical event, as in the grading ‘mild’, ‘moderate’, and ‘severe’; thus, a severe skin reaction need not be serious

### **Adverse event/adverse experience**

Any untoward occurrence that may present during treatment with a pharmaceutical product, but which does not necessarily have a causal relation to the treatment

### **Drug hypersensitivity reaction (DHR)**

Drug hypersensitivity reactions (DHRs) are adverse effects of drugs that clinically resemble allergic reactions (‘pseudo-allergic’). DHR includes adverse reactions that are immune or



nonimmune mediated. For general communication, when an allergic drug reaction is suspected DHR is the preferred term, because true drug allergy and nonallergic DHR may be difficult to differentiate based on the clinical presentation alone, especially in cases of acute severe DHR.

Clinically, DHRs are commonly classified as immediate or nonimmediate/delayed depending on their onset during treatment. The discrimination between immediate and nonimmediate DHR has its limitations because other factors such as the route of administration, the role of drug metabolites, and the presence of co-factors or co-prescribed drugs may accelerate or slow down the onset or progression of a reaction. Although artificial, this classification into immediate and nonimmediate DHR is very important in clinical practice for workup planning.

### **Non-immune drug hypersensitivity reaction**

Nonimmune hypersensitivity drug reactions are all adverse drug reactions whose symptomatology suggests an allergy but for which the immunologic nature of the reaction cannot be proved.

Nonimmune drug hypersensitivity reactions assume most of the criteria listed under drug allergy. Numerous nonimmune hypersensitivity reactions occur and are caused by multiple aetiologies. Examples include:

- Include nonspecific histamine release (opiates, radiocontrast media, and vancomycin),
- An accumulation of bradykinin (angiotensin-converting enzyme inhibitors),
- Complement activation (radiocontrast media, protamine),
- An activation of leukotriene synthesis (aspirin and nonsteroidal anti-inflammatory drugs),
- Bronchospasm (by liberation of sulphur dioxide during treatments containing sulphites or by blockage of the b-adrenergic receptors, even when the drug is administered through the eyes).
- Nonimmediate drug hypersensitivity like reaction due to pharmacological interaction with immune receptor. P-i concept reactions are associated with specific HLA types.

### **Immediate drug hypersensitivity reaction (IHR)**

Immediate DHRs are possibly induced by an IgE-mediated mechanism and occur within 1–6 h after the last drug administration. Typically, they occur within the first hour following the first administration of a new course of treatment.

Immediate DHRs usually present with urticaria, angioedema, rhinitis, conjunctivitis, bronchospasm, gastrointestinal symptoms (nausea, vomiting, diarrhoea), or anaphylaxis, which can lead to cardiovascular collapse (anaphylactic shock)

### **Non-immediate drug hypersensitivity reaction (NIHR)**

Nonimmediate DHRs may occur any time as from 1 h after the initial drug administration. They commonly occur after many days of treatment and are often associated with a delayed T-cell-dependent type of allergic mechanism.

Nonimmediate DHRs often affect the skin with variable cutaneous symptoms such as late occurring or delayed urticaria, maculopapular eruptions, fixed drug eruptions (FDE), vasculitis, blistering diseases (such as TEN, SJS, and generalized bullous fixed drug eruptions), HSS, acute generalized exanthematous pustulosis (AGEP), and symmetrical drug-related intertriginous and flexural exanthemas (SDRIFE). Internal organs can be affected either alone or with cutaneous symptoms (HSS/DRESS/DiHS, vasculitis, SJS/TEN) and include hepatitis, renal failure, pneumonitis, anaemia, neutropenia, and thrombocytopenia.

### **Drug allergy**

A drug allergy is always associated with an immune mechanism for which evidence can be shown of drug-specific antibodies or activated T lymphocytes. Drugs can induce all the types of immunologic reactions described by Gell and Coombs

A drug allergy is characterized by the following criteria:

- The reaction is not an expected pharmacologic effect.
- A period of sensitization precedes the reaction.
- The reaction may occur at a dose much lower than that required for a pharmacologic effect.
- The clinical symptoms are characteristic of an allergic reaction.
- Resolution occurs within an expected interval, usually days, after discontinuation of the offending agent.
- Chemical cross-reactivity may occur

### **Classification of Adverse Drug Reactions**

#### **Type A adverse drug reaction**

Type A (augmented) reactions result from an exaggeration of a drug's normal pharmacological actions when given at the usual therapeutic dose and are normally dose dependent. Examples include respiratory depression with opioids or bleeding with warfarin. Type A reactions also include those that are not directly related to the desired pharmacological action of the drug, for example dry mouth that is associated with tricyclic antidepressants

#### **Type B adverse drug reaction**

Type B (bizarre) reactions are novel responses that are not expected from the known pharmacological actions of the drug. These are less common, and so may only be discovered for the first time after a drug has already been made available for general use. Examples include anaphylaxis with penicillin or skin rashes with antibiotics. Type B ADR include adverse reactions that are dose-independent, unpredictable, noxious, and unintended response to a drug taken at a dose normally used in humans. However, some dose dependence has been shown repeatedly in DHRs (e.g., for nonsteroidal anti-inflammatory drugs (NSAIDs), antiepileptic drugs) and some are predictable due to the disease state (e.g., human immunodeficiency virus (HIV) infection/acquired immunodeficiency syndrome (AIDS), Epstein–Barr virus (EBV) infection) or a similar previous reaction to the same drug or drug class. Some are associated with specific HLA types

#### **Type C adverse drug reaction**

Type C ('continuing') reactions persist for a relatively long time. Examples are osteonecrosis of the jaw with bisphosphonates, Hypothalamic-pituitary-adrenal axis suppression by corticosteroids

#### **Type D adverse drug reaction**

Type D ('delayed') reactions become apparent sometime after the use of a drug. The timing of these may make them more difficult to detect. An example is leucopenia, which can occur up to six weeks after a dose of lomustine. Teratogenic (e.g., vaginal adenocarcinoma with diethylstilbesterol) and carcinogenic reactions can also be type D reactions.

#### **Type E adverse drug reaction**

Type E ('end-of-use') reactions are associated with the withdrawal of a drug. An example is insomnia, anxiety and perceptual disturbances following the withdrawal of benzodiazepines.

### **Type F adverse drug reaction**

Type F (failure) reactions are the result of unexpected failure of therapy. An example is inadequate dosage of an oral contraceptive, particularly when used with specific enzyme inducers (interaction).

### **Causality assessment of suspected adverse drug reactions**

#### **Certain**

- A clinical event, including a laboratory test abnormality, which occurs in a plausible time relation to drug administration, and which cannot be explained by concurrent disease or other drugs or chemicals
- The response to withdrawal of the drug (de-challenge) should be clinically plausible
- The event must be definitive pharmacologically or phenomenologically, using a satisfactory rechallenge procedure if necessary

#### **Probable/likely**

- A clinical event, including a laboratory test abnormality, with a reasonable time relation to administration of the drug, unlikely to be attributed to concurrent disease or other drugs or chemicals, and which follows a clinically reasonable response on withdrawal (de-challenge)
- Rechallenge information is not required to fulfil this definition

#### **Possible**

- A clinical event, including a laboratory test abnormality, with a reasonable time relation to administration of the drug, but which could also be explained by concurrent disease or other drugs or chemicals
- Information on drug withdrawal may be lacking or unclear

#### **Unlikely**

- A clinical event, including a laboratory test abnormality, with a temporal relation to administration of the drug, which makes a causal relation improbable, and in which other drugs, chemicals, or underlying disease provide plausible explanations

#### **Conditional/unclassified**

- A clinical event, including a laboratory test abnormality, reported as an adverse reaction, about which more data are essential for a proper assessment, or the additional data are being examined

#### **Not assessable/unclassifiable**

- A report suggesting an adverse reaction that cannot be judged, because information is insufficient or contradictory and cannot be supplemented or verified

### **Literature For Further Reading**

Abrams EM, Khan DA. Diagnosing and managing drug allergy. CMAJ 2018; 190(17): E532-E538.

CIOMS Cumulative Pharmacovigilance Glossary v1.1. Available at: [\[URL\]](#). Accessed: 7 June 2022.

Demoly P, Adkinson NF, Brockow K, Castells M, Chiriac AM, Greenberger PA, et al. International consensus on drug allergy. Allergy. 2014; 69(4): 420-437.

- Demoly P, Hillaire-Buys D. Classification and epidemiology of hypersensitivity drug reactions. *Immunol Allergy Clin N Am* 2004; 24: 345– 356.
- Edwards IR, Jeffrey K Aronson JK. Adverse drug reactions: definitions, diagnosis, and management. *Lancet* 2000; 356: 1255–1259.
- European Medicines Agency. Guideline on good pharmacovigilance practices (GVP). Annex I – Definitions (rev 4, 2017). Available at: [\[URL\]](#). Accessed: 7 June 2022.
- Gerth van Wijk R, Van Cauwenberge PB, Johansson SG. [Revised terminology for allergies and related conditions]. *Ned Tijdschr Geneeskd.* 2002; 146(48): 2289-2293.
- Johansson SG, Bieber T, Dahl R, Friedmann PS, Lanier BQ, Lockey RF, et al. Revised nomenclature for allergy for global use: Report of the Nomenclature Review Committee of the World Allergy Organization, October 2003. *J Allergy Clin Immunol.* 2004; 113(5): 832-836.
- Lindquist M. The Need for Definitions in Pharmacovigilance. *Drug Safety* 2007; 30 (10): 825-830.
- Medicines and Healthcare Regulatory Agency. Guidance on adverse drug reactions Yellow Card. Available at: [\[URL\]](#). Accessed: 7 June 2022.

## Module 7.1 In Vitro Tests in Patients with Hypersensitivity Reactions to Contrast Media

This is an update of module 3 of the previous guideline [Safe Use of Contrast Media part 2](#).

### Clinical question

What is the diagnostic value of serum and/or urine testing for contrast media induced hypersensitivity reactions?

### Introduction

*In vitro* tests using blood or urine can be employed in the analysis of possible hypersensitivity reactions, immediately following the event or in an outpatient setting. Which diagnostics should be performed depends on the timing and the type of reaction.

Hypersensitivity reactions to contrast media are described as immediate (acute) or nonimmediate (delayed, late). Reactions occurring within one hour after application of the agents are coined as immediate, reactions occurring later are called nonimmediate. For more information see the [Introduction of this chapter](#).

Nonimmediate hypersensitivity reactions (NIHM) are mediated by CM specific T-lymphocytes (Christiansen, 2000; Kanny, 2005; Lerch, 2007; Romano, 2002). In the (semi)acute setting, there are no *in vitro* diagnostic methods available to confirm the diagnosis. To date, only a skin biopsy can be useful in this setting, but specific pathognomonic features are lacking. Routine laboratory diagnosis (leukocyte count + differential, liver enzymes, urea, creatinine) is useful to screen for extracutaneous organ involvement. Eosinophilia may support the diagnosis of NIHM but lacks both sensitivity and specificity. Additional diagnostic methods in the outpatient setting are also mostly performed *in vivo* by means of patch testing and/or skin prick or intradermal testing with late (>24 hours) readings. Lymphocyte transformation tests (LTT) are currently not available in the Netherlands.

Immediate hypersensitivity reactions (IHR) are nowadays considered to be mediated by both allergic (IgE-mediated) and nonallergic (non-IgE-mediated, i.e., direct nonspecific mast cell degranulation or complement activation) mechanisms (Torres, 2021).

In the acute event of an IHR, mast cell degranulation (via IgE or non-IgE mediated mechanisms) can be studied by measuring serum beta-tryptase (tryptase) or histamine. Serum histamine determination is unpractical because of its short half-life in circulation. An alternative is detection of histamine metabolites in urine. (N- $\tau$ -Methylhistamine). Although this is a reliable parameter (Keyzer, 1984), very few laboratories have this test in their routine repertoire, and there are not enough data available with respect to contrast media. So, this parameter is not further discussed.

In the outpatient setting, analysis of IHR mostly depends on *in vivo* diagnostic methods using skin prick and intradermal testing. In the recent years, additional drug provocation tests (DPT) have gradually been implemented in specialized centres. *In vitro* diagnosis is limited to detection of specific IgE antibodies and basophil activation tests (BAT). Specific antibodies against certain ionic contrast media have been detected in patients with IHR (Laroche 1998;

Mita 1998); however, to date there are no specific IgE antibodies commercially available. Application of BAT to heparin stabilized blood samples of patients shows interesting results but its availability is limited to specialized laboratories.

### **Search and select**

A systematic review of the literature was performed to answer the following question: What is the diagnostic value of serum and/or blood testing compared to clinical diagnosis of hypersensitivity reaction after contrast administration / no *in vitro* tests for contrast media induced hypersensitivity reactions?

- P:** (Patients): Patients with hypersensitivity reactions after undergoing radiological examinations with contrast media.
- I:** (Intervention): Serum tests: tryptase, blood test, basophil activation test.
- C:** (Comparison): Clinical diagnosis of hypersensitivity reaction after contrast administration / no serum tests.
- R:** (Reference test): Drug provocation test.
- O:** (Outcomes): Correctly confirmed diagnosis of hypersensitivity reaction to contrast media (sensitivity, specificity, area under the curve, positive predictive value PPV, negative predictive value NPV).

### Relevant outcome measures

The working group considered sensitivity and specificity critical outcome measures for the decision-making process; and considered the area under the curve and the positive and negative predictive values important outcome measures.

### Search and select (Methods)

The databases Medline (via OVID) and Embase (via Embase.com) were searched with relevant search terms until April 22<sup>nd</sup>, 2021. The detailed search strategy is depicted under the tab Methods. The systematic literature search resulted in 368 hits. Studies were selected based on the following criteria:

- Adult patients with hypersensitivity reaction to radio contrast media.
- Evaluation of diagnostic properties of serum tests to contrast media.
- Application of a provocation test to confirm results of cutaneous testing.
- Reports predefined outcome measures: sensitivity, specificity, area under the curve, positive predictive value, negative predictive value.
- Serum tests tryptase and urine-metabolites should be performed within 24 hours after hypersensitivity reaction.
- No reports of case series or exploratory findings (n≥10).

Seven studies were initially selected based on title and abstract screening. After reading the full text, all seven studies were excluded (see Table of excluded studies in 'Appendices to modules').

### **Summary of literature**

No studies were included in the analysis of the literature; therefore, no systematic literature analysis was performed.

### **Justifications – evidence to decision**

1. Immediate/acute hypersensitivity reactions (IHR)

### *Tryptase*

Histamine and tryptase can be both measured to confirm IHR to CM. However, histamine is degraded quickly, being less specific and more complicated to measure by commercially available assays. Thus, tryptase is regarded as the preferred mediator. The approach is to compare acute (within 4 hours of the event) and baseline total tryptase levels (at least 24 hours after all signs and symptoms of the event have subsided) to distinguish between an increased mast cell burden (e.g., mastocytosis, in which baseline tryptase levels remain elevated) and mast cell degranulation (with only acute tryptase levels elevated). The minimal elevation of acute over baseline tryptase levels suggested to be clinically significant is calculated as at least 2 ng/mL + [1.2 x baseline tryptase level] (Sprung, 2015) or at least 20% above baseline plus 2 ng/mL during or within 4 hours after a symptomatic period (Valent, 2012). An increase from baseline level during allergic symptoms is suggestive of an IHR to CM. It has been reported that higher tryptase elevations are indicative of IgE-mediated mast cell activation and correlate with the clinical severity of the reaction (Clement, 2018; Laroche, 2005; Schwarz, 2006).

Therefore, the ESUR guidelines suggests serum tryptase measurements following a suspected immediate hypersensitivity reaction. The minimum recommendation is one sample 1 to 2 hours after the reaction point. Ideally, three samples should be obtained, the first one once this histamine release is underway, the second at 1 to 2 hours after the reaction, and the third at 24 hours or during convalescence (ESUR, 2018). The recently published practice guideline by the European Academy of Allergy and Clinical Immunology (EAACI) considers tryptase determination in the acute phase useful for confirming IHR to CM, if a transient increase is detectable (strong/moderate) (Torres, 2021). It is advised to measure tryptase within 4 hours of the acute event.

### *Basophil Activation Test (BAT)*

The BAT technique is based on detection of activation of basophils with flow cytometry. CD63 expression serves as a unique marker for identifying activated cells. The technique requires a small amount of fresh blood, less than 0.1 mL. The CD63 marker is located to the same secretory granule that contains histamine; in principle, histamine production could also be used as a marker of basophil activation, but determination of histamine is more cumbersome than detecting CD63 upregulation (Hoffmann, 2015). BAT has shown its usefulness in diagnosing immediate hypersensitivity reactions to contrast media. The use of BAT in acute reactions to GBCA demonstrated an excellent specificity (93%) in the diagnosis of allergic immediate hypersensitivity to GBCA and a quite good sensitivity (69%). It was concluded that BAT remains especially useful for patients with uncertain diagnosis and to confirm a positive ST result (Kolenda, 2018). Three studies published on the diagnostic value of BAT regarding CM. The sensitivity ranged from 46 to 63%, while specificity varied between 89 and 100% (Pinnobphun, 2011; Salas, 2013; Trcka, 2008). Pinnobphun et al. also reported an area under the ROC curve of 0.79 by using the stimulation index as the diagnostic criteria with 1:100 dilution of radiocontrast media (Pinnobphun, 2011).

Thus, BAT can be a complementary tool to diagnose IHR to CM (Brockow, 2020), showing good correlation with ST and DPT results (Salas, 2013). Since it is an *in vitro* test, it may be especially useful in cases with severe reaction and contraindications for ST or DPT (Brockow, 2020). However, there are several limitations to consider. The NPV has not been clearly determined (Decuyper, 2017) and that certain factors may affect BAT result, such as the time between the reaction and the test or the severity and type of reaction (Salas, 2013). In addition, it has to be considered that more than 10% of patients have non-reacting basophils

(i.e., the positive control remains negative), rendering this test unsuitable for these patients at that time. Lastly, BAT is currently only available in specialized drug allergy centres in the Netherlands. The EAACI practical guidelines (Torres, 2021) consider BAT an additional tool for diagnosing patients with IHR with severe reactions or those with high risk (weak/low).

## 2. Nonimmediate/late hypersensitivity reactions (NIHR)

### *Lymphocyte Transformation Test (LTT)*

LTT is not recommended at the acute stage, but after 4-8 weeks after remission (Hari, 2011) and within 2 -3 years after the reaction (Pichler, 2004). Corticosteroids in doses higher than 0.2 mg/kg prednisone equivalent and other immunosuppressive or immunomodulatory agents may interfere with the test. A NPV for LTT in NIHR to CM is not available. As radioactive materials have been banned in many laboratories, the use of "modified non-radioactive LTT" will be a better choice.

The LTT is recommended as an additional diagnostic tool in selected cases with contraindications for STs (weak/low). It should only be performed by experienced physicians (weak/low) (Torres, 2021). Unfortunately, LTT is currently not available in any allergology centre in the Netherlands. Alternative *in vitro* tests such as the OX40 test are still under development.

## Recommendations

Measure serum tryptase, preferably between 1-2 hours (range 15 minutes to 4 hours) from the start of all moderate to severe immediate hypersensitivity reactions to contrast media. This measurement serves as a baseline for further allergologic examinations.

\*See also [flow charts](#)

Basophil activation tests are reserved for selected patients with moderate to severe acute hypersensitivity reactions and are only available in specialized drug allergy centres.

For nonimmediate hypersensitivity reactions there are no meaningful *in vitro* tests available in the Netherlands.

## Literature

- Brockow K. Medical algorithm: Diagnosis and treatment of radiocontrast media hypersensitivity. *Allergy*. 2020;75(5):1278-1280.
- Christiansen C, Pichler WJ, Skotland T. Delayed allergy-like reactions to X-ray contrast media: mechanistic considerations. *Eur Radiol* 2000; 10: 1965-1975.
- Clement O, Dewachter P, Mouton-Faivre C, et al. Immediate hypersensitivity to contrast agents: the French 5-year CIRTACI study. *EClinicalMedicine*. 2018; 1: 51-61.
- Decuyper II, Mangodt EA, Van Gasse AL, et al. In Vitro Diagnosis of Immediate Drug Hypersensitivity Anno 2017: Potentials and Limitations. *Drugs R D*. 2017; 17(2): 265-278.



- European Society of Urogenital Radiology Contrast Media Safety Committee. ESUR Guidelines on contrast safety, v10. Available at: [\[URL\]](#). Accessed: 22. May 2022.
- Hari Y, Frutig-Schnyder K, Hurni M, et al. T cell involvement in cutaneous drug eruptions. *Clin Exp Allergy*. 2001; 31(9): 1398-1408.
- Kanny G, Pichler W, Morisset M, Franck P, Marie B, Kohler C, Renaudin JM, Beaudouin E, Laudy JS, Moneret-Vautrin DA. T cell-mediated reactions to iodinated contrast media: evaluation by skin and lymphocyte activation tests. *J Allergy Clin Immunol*. 2005; 115(1): 179-185.
- Keyzer JJ, Kauffman HF, de Monchy JG, Keyzer-Udding JJ, de Vries K. Urinary N-tau-methylhistamine during early and late allergen-induced bronchial-obstructive reactions. *J Allergy Clin Immunol*. 1984; 74(3 Pt 1): 240-245.
- Laroche D, Aimone-Gastin I, Dubois F, et al. Mechanisms of severe, immediate reactions to iodinated contrast material. *Radiology* 1998; 209(1): 183-190.
- Laroche D. Immediate reactions to contrast media: mediator release and value of diagnostic testing. *Toxicology*. 2005; 209(2): 193-194.
- Lerch M, Keller M, Britschgi M, Kanny G, Tache V, Schmid DA, Beeler A, Gerber BO, Luethi M, Bircher AJ, Christiansen C, Pichler WJ. Cross-reactivity patterns of T cells specific for iodinated contrast media. *J Allergy Clin Immunol*. 2007; 119(6): 1529-1536.
- Mita H, Tadokoro K, Akiyama K. Detection of IgE antibody to a radiocontrast medium. *Allergy* 1998; 53(12): 1133-1140.
- Pichler WJ, Tilch J. The lymphocyte transformation test in the diagnosis of drug hypersensitivity. *Allergy*. 2004; 59(8): 809-820.
- Pinnobphun P, Buranapraditkun S, Kampitak T, Hirankarn N, Klaewsongkram J. The diagnostic value of basophil activation test in patients with an immediate hypersensitivity reaction to radiocontrast media. *Ann Allergy Asthma Immunol* 2011; 106(5): 387-393.
- Romano A, Artesani MC, Andriolo M, Viola M, Pettinato R, Vecchioli-Scaldazza A. Effective prophylactic protocol in delayed hypersensitivity to contrast media: report of a case involving lymphocyte transformation studies with different compounds. *Radiology*. 2002; 225(2): 466-470.
- Salas M, Gomez F, Fernandez TD, et al. Diagnosis of immediate hypersensitivity reactions to radiocontrast media. *Allergy*. 2013; 68(9): 1203-1206.
- Schrijvers R, Breynaert C, Ahmedali Y, Bourrain JL, Demoly P, Chiriac AM. Skin testing for suspected iodinated contrast media hypersensitivity. *J Allergy Clin Immunol Pract* 2018; 6: 1246-1254.
- Schwartz LB. Diagnostic value of tryptase in anaphylaxis and mastocytosis. *Immunol Allergy Clin North Am*. 2006; 26(3): 451-463.
- Sprung J, Weingarten TN, Schwartz LB. Presence or absence of elevated acute total serum tryptase by itself is not a definitive marker for an allergic reaction. *Anesthesiology*. 2015; 122(3): 713-714.
- Torres MJ, Trautmann A, Böhm I, Scherer K, Barbaud A, Bavbek S, et al. Practice parameters for diagnosing and managing iodinated contrast media hypersensitivity. *Allergy* 2021; 76(5): 1325-1339.
- Trcka J, Schmidt C, Seitz CS, Brocker EB, Gross GE, Trautmann A. Anaphylaxis to iodinated contrast material: nonallergic hypersensitivity or IgE-mediated allergy? *AJR Am J Roentgenol* 2008; 190(3): 666-670.
- Valent P, Akin C, Arock M, et al. Definitions, criteria, and global classification of mast cell disorders with special reference to mast cell activation syndromes: a consensus proposal. *Int Arch Allergy Immunol*. 2012; 157(3): 215-225.

## Module 7.2 Diagnostic Value of Skin Testing for Hypersensitivity Reactions to Contrast Media

This is an update of module 4 of the previous guideline [Safe Use of Contrast Media part 2](#).

### Clinical question

What should be done in patients with a history of hypersensitivity reactions after contrast media administration, to decrease the risk of developing a recurrent hypersensitivity reaction?

### Introduction

Hypersensitivity reactions to contrast media (CM) have traditionally been classified as non-allergic reactions, and skin tests have been regarded as inappropriate tools in patients having experienced such reactions. However, during the last years several investigators have reported positive skin tests in patients with both immediate and nonimmediate hypersensitivity reactions after CM exposure, which indicates that immunological mechanisms may be involved more frequently than previously thought (Brockow, 2009 and 2020). In this chapter the diagnostic value of cutaneous tests for CM hypersensitivity reactions is assessed, which may serve as a more valid alternative to prophylactic medication for CM reactions. Furthermore, the working group evaluates whether these skin tests should be recommended in clinical practice, and under which conditions.

### Search and select

A systematic review of the literature was performed to answer the following question: What is the diagnostic value of skin testing for hypersensitivity reactions to contrast media?

<b>P</b> (patient category):	Patients with hypersensitivity reactions after radiological examinations with contrast media
<b>I</b> (intervention):	Cutaneous tests: skin test, patch test (PT), intradermal test (IDT), skin prick test (SPT) or scratch test
<b>C</b> (comparison)	Clinical diagnosis of hypersensitivity reaction after contrast administration
<b>R</b> (Reference)	Drug provocation test
<b>O</b> (outcome)	Correctly confirmed diagnosis of hypersensitivity reaction to contrast media (sensitivity, specificity, area under the curve, positive predictive value, negative predictive value)

### Relevant outcome measures

The working group considered sensitivity and specificity critical outcome measures for the decision-making process; and considered the area under the curve and the positive and negative predictive values important outcome measures.

### Search and select (Methods)

On April 22<sup>nd</sup>, 2021, a systematic search was conducted in the databases Embase (embase.com) and Medline (OVID) from 2017 onwards, using relevant key words for systematic reviews, RCT's, observational studies and other study designs about hypersensitivity reactions after contrast media. Specifically, the value of serum and/or urine tests, either skin tests or prophylactic measures were sought. The literature search yielded 400 unique references.

Studies were selected based on the following criteria:

- Adult patients with  $\geq 1$  hypersensitivity reaction(s) to contrast media
- Evaluation of diagnostic properties of cutaneous tests to contrast media
- Application of a provocation test to confirm results of cutaneous testing
- Reports predefined outcome measures: sensitivity, specificity, area under the curve, positive predictive value, negative predictive value
- No reports of case series or exploratory findings ( $n \geq 10$ )

Based on title and abstract, a total of twenty-one studies were selected. After examination of full text, a total of eighteen studies were excluded and three new studies to the earlier synthesis of 2017 were included in the literature summary. Reason for exclusion is reported in Table of excluded studies which can be found in the supplementary document Appendices to modules.

Three studies were added to the literature analysis of 2017. Important study characteristics and results are summarized in the evidence tables. The assessment of the risk of bias is summarized in the risk of bias tables. Two studies (Kim, 2017; Schrijvers, 2018) did not fulfil the predefined selection criteria but described the negative predictive values of IDT and skin tests in patients who had a hypersensitivity reaction after CM administration. Since these studies did not fulfil the selection criteria and did not include a comparison to a reference test, only descriptive data of these studies was shown, and evidence tables and risk of bias tables of these studies are not included.

## Summary of literature

### Description of studies

#### *1. Diagnostic characteristics of cutaneous tests for **immediate** HSR*

The diagnostic characteristics of cutaneous tests for acute (immediate) hypersensitivity reactions (HSR) to contrast media (CM) were evaluated in 4 studies (Caimmi, 2010; Kim, 2013; Salas, 2013; Sesé, 2016).

Caimmi (2010) studied 159 patients. Patients were tested with the culprit iodine-based contrast medium (ICM) and a set of other ICM if they were positive for the culprit ICM or if its name was unknown. To know which ICM was involved, either patients already knew which drug had supposedly caused the reaction, or the authors contacted the hospital in which the reaction had occurred. The ICM used were: amidotrizoate, ioxithalamate, iopamidol, iohexol, ioversol, iopromide, iomeprol, iobitridol, iodixanol and ioxaglate. Skin tests were performed firstly as prick tests with the undiluted commercially available solution and then, if negative, by intradermal tests (IDT) at a 1: 10 dilution. Prick tests were considered positive if, after 15 min, the size of the weal was at least 3 mm in diameter. For IDT, positivity was considered when the size of the initial weal increased by at least 3 mm in diameter after 15 to 20 min, considering as non-irritant a maximum dilution of 1/10. The negative predictive value was defined as the proportion of patients with negative skin test results to at least one ICM at first testing who had a further injection with that ICM without reacting. One hundred participated (75.5% participation rate). Seventy-one of them (59.2%) were females of a median age of 56 (45–65) years. Most of the reactions were immediate (101 out of 120, 84.2%), and in two cases, it was not possible to assess whether the reaction was immediate or nonimmediate. For immediate reactions, 42 (41.6%) were of grade 1, 34

(33.7%) of grade 2, 20 (19.8%) of grades 3 and five (4.9%) of grade 4. Only one (5.9%) of the 17 nonimmediate reactions was moderate, all the others were mild (16 to 94.1%).

Kim (2013) retrospectively included 1048 patients. The mean (SD) age was 55.1 (14.5) years; 501 (47.8%) were male. Intradermal test with the RCM that was to be used in the pending nonionic CM-enhanced CT was performed just before the CT examinations. The nonionic CM used was iopromide, iomeprol, iohexol, and iodixanol. Intradermal tests were conducted on the volar surface of the forearm with a negative control, saline. A 1:10 solution of contrast medium (0.03 to 0.05 mL), which has been accepted as a non-irritating concentration, was gently injected into the skin to produce a small superficial bleb of 2 to 4 mm. Skin test positivity was determined when the diameter of the wheal increased by at least 3 mm, and surrounding erythema was observed after 15 to 20 minutes. If a patient had a negative response to skin tests, CT was performed as scheduled (provocation). Of the 376 patients previously exposed to CM, 61 (16.2%) had a history of at least 1 mild CM-associated reaction: 56 (91.8%) had immediate and 5 (8.2%) nonimmediate reactions.

Salas (2013) included 90 patients with a history of immediate HSR after contrast media (CM). Immediate HSR was classified according to the Ring and Messmer scale. Skin tests (ST) were carried out using the following CM: iobitridol, iomeprol, iodixanol, iohexol, ioversol, iopromide and ioxaglate. Prick tests were performed using undiluted CM and IDT using 10-fold dilutions. In those with a negative ST, a single-blind placebo-controlled provocation test was performed with the CM involved, as described. In patients with a positive ST and/or provocation test, a basophil activation test (BAT) was performed with iohexol (3; 0.3 mg/ml), iodixanol (3; 0.3 mg/ml), iomeprol (3.5; 0.35 mg/ml) and ioxaglate (5.8; 0.58 mg/ml) (based on dose–response curves and cytotoxicity studies). The median age of the subjects evaluated was 54.50 ± 27 years; 63 (60%) were women. The CM involved in the reaction was iomeprol in 26 cases (28.89%), iodixanol in 19 (21.11%), iohexol in 11 (12.22%), iopromide in 9 (10.00%) and unknown in 25 (27.78%). According to the clinical history, most cases developed reactions with skin involvement (65.65% urticaria/ angioedema and 30% generalized erythema), and only 4.44% had airway or cardiovascular involvement. Regarding symptom severity, 69 cases (76.71%) had grade I reactions, 18 (20%) grade II and 3 (3.33%) grade III. No patients had grade IV reactions.

Sesé (2016) included 37 patients with a definite history of immediate HSR due to iodine-based contrast media (ICM). Immediate HSR was classified according to the Ring and Messmer scale. Skin tests were performed at least 6 weeks after the HSR on the volar forearm with the suspected ICM and with four other ICM. Skin prick tests (SPTs) involved freshly prepared undiluted ICM commercial solutions, and intradermal tests (IDTs) were performed successively with 100-fold and then 10-fold solution diluted in 0.9% sterile saline. Saline and chlorhydrate histamine were negative and positive controls, respectively. In total, 37 patients (24 women, mean age 49.3 years at the time of the reaction) completed the tests. The clinical severity of the reaction was grade I for 26 (70%), grade II for 4 (11%), and grade III for 7 (19%); 35 (95%) reported skin or mucosal symptoms, including pruritus (n = 11), facial erythema (n = 6), generalized erythema (n = 20), urticaria (n = 7), and angioedema (n = 5).

## 2. Diagnostic characteristics of cutaneous tests for *non-immediate* HSR

The diagnostic characteristics of cutaneous tests for delayed (nonimmediate) hypersensitivity reactions (HSR) to iodine-based contrast media (ICM) was evaluated in one study (Torres, 2012).

Torres (2012) included a total of 161 subjects with a history of a nonimmediate reaction imputable to at least one CM was evaluated. One patient who developed Stevens–Johnson syndrome was not included. The median age was 58.5 years (IR: 48.85 to 66.5) with 82 men (50.9%). According to the information obtained from the clinical history, the CM involved in the reaction were iomeprol in 53 (32.9%), iodixanol in 46 (28.6%), iohexol in 27 (16.8%), iobitridol in 4 (2.5%), ioversol in 3 (1.9%), iopromide in 3 (1.9%), ioxaglate in 2 (1.2%) and unknown in 23 (14.3%). According to the clinical history, 108 cases (67.1%) developed symptoms compatible with exanthema and 53 (32.9%) with delayed urticaria. Regarding symptom severity, 16 cases (9.9%) had mild reactions, 143 (88.8%) moderate reactions, and 2 severe reactions (1.2%) consisting of desquamative exanthema. Concerning the number of episodes, 132 cases (82%) had one episode and 29 cases (18%) two episodes.

### 3. *Other tests*

Three studies analysed different tests to determine hypersensitivity to contrast media (Kim, 2019; Meucci, 2020; Schrijvers, 2018).

Kim (2019) in a prospective cohort studied 36 patients with a history of immediate adverse drug reactions to radiocontrast media (RCM), presenting at the Allergy and Asthma Clinic of Severance hospital in South Korea from 2017 to 2018. Mean age was  $57.3 \pm 13.9$  years and 69.4% (n=25) was female. The index test was intradermal testing (IDT) with diluted (1:10) RCM: iobitridol, iohexol, iopamidol, iopromide, and iodixanol. The IDT was considered positive when the diameter of the initial wheal had increased  $\geq 3$ mm and was surrounded by erythema, confirmed at 20 minutes and at 3 days after IDT. The comparator test was similar to the index test, only performed with undiluted RCMs. No reference test was performed.

Meucci (2020) studied retrospectively 98 patients with previous reactions to iodinated contrast media (ICM) presented at the Allergology Unit in a hospital in Italy, from 2015 to 2018. Median (range) age was 65.6 (23-90) years and 54.2% (n=53) was female. The index test was the (less sensitive) skin prick test with undiluted ICMs: iohexol, iopromide, iodixanol, iopamidol, and ioversol. The skin test was considered positive when the diameter of the initial wheal had increased  $\geq 3$ mm and was surrounded by erythema after 15 minutes. Furthermore, a distinguishment was made between immediate hypersensitivity reactions (IHR) (<1 hour after ICM administration) and delayed hypersensitivity reactions (DHR) (>1 hour after ICM administration). The comparison test was an IDT with diluted (1:10) ICM: iohexol, iopromide, iodixanol, iopamidol, and ioversol. The IDT was considered positive when the diameter of the initial wheal had increased  $\geq 3$ mm and was surrounded by erythema after 20 minutes. The reference test was a DPT, where the choice of ICM was based on the following: in case of a mild, recent (<12 month) reaction with negative skin tests for the culprit ICM, the DPT was performed with the culprit ICM. In case participants refused administering of culprit ICM, or if culprit ICM was unknown, another ICM was chosen. A subgroup of patients was re-exposed to ICM as part of their regular medical care; this re-exposition was used as a reference test to analyse their entire diagnostic protocol (skin tests + DPT).

Schrijvers (2018) in a retrospective cohort studied 597 patients with a history of ICM-mediated drug hypersensitivity reaction, presenting at the Allergy Department of the University Hospital, France, February 2001 to September 2014. Median (range) age was 60 (13-92) years and 68.0% (n=406) was female. The index test was a skin prick test with undiluted ICM: amidotrizoate, ioxitalamate, iopamidol, iohexol, ioversol, iopromide,

iomeprol, iobitridol, iodixanol, and ioxaglate. The skin test was considered positive when the diameter of the initial wheal had increased  $\geq 3$ mm and was surrounded by erythema after 15 minutes. When the skin test was negative, an intradermal test (IDT) was performed as well. The IDT was considered positive when the diameter of the initial wheal had increased  $\geq 3$ mm and was surrounded by erythema after 20 minutes. No reference test was performed, but re-exposure to a skin test negative ICM occurred in 233 (39%) patients as part of their regular medical care.

#### 4. Hypersensitivity reactions to gadolinium-based contrast agents (GBCA)

For GBCAs there was even less literature available, as hypersensitivity reactions to these agents are infrequent with an estimated prevalence of 0.004%-0.7% (Ahn, 2022). Skin tests are performed only in case reports or small case series and outcome measures as NPVs can therefore not be calculated (Gallardo-Higueras 2021, Grüber 2021). As pathogenetic mechanisms for GBCA-mediated hypersensitivity reactions are considered similar to those elicited by ICM and skin tests are performed according to comparable protocols, the recommendations for GBCA are extrapolated from those for ICM.

### Results

Due to the heterogeneity in study designs, reported outcomes and follow up times, pooling of data could not be performed.

#### 1. Diagnostic characteristics of cutaneous tests for **immediate** HSR

Caimmi (2010) revealed that ICM skin tests were positive in 21 patients (17.5%). Seventeen of them (80.9%) had a history of immediate reaction (four with grade 1, eight grade 2, four grade 3 and one grade 4). Prick tests were all negative. IDT were positive at 20 min for 15 patients with an immediate history and for the patient with unknown chronology. Caimmi (2010) found one single false negative; the negative predictive value of ICM skin tests was 96.6% (95% CI: 89.9 to 103.2).

Kim (2013) showed that among the 1046 patients who had negative responses on skin tests, 52 (5.0%) showed immediate-type adverse reactions after CT using radio contrast media. However, most reactions were mild and cutaneous, such as pruritus, urticaria, and mild angioedema. Only 1 patient (0.1%) had a grade II moderate immediate reaction accompanied by breathing difficulty and mild laryngeal oedema, which were relieved with an antihistamine. The negative predictive value of the pre-screening skin test for immediate hypersensitivity reactions before contrast media administration was 95.0%. The negative predictive value of the skin test for immediate hypersensitivity reactions in patients with a history of contrast media hypersensitivity reactions was 80.3% (n= 49/61) and that in patients without a history was 95.9% (n= 945/985).

Salas (2013) showed that five subjects (5.56%) had a positive skin test: three by prick test (one to iodixanol, one to iomeprol and one to iohexol) and five by intradermal testing (four to iohexol, three iodixanol and two to iomeprol). In cases with a negative skin test to all CM tested (N = 74), provocation test was carried out with the culprit CM if known, being positive in three cases: one to iodixanol, one to iomeprol and one to iodixanol, iohexol plus iomeprol. In total, 11 patients with a negative ST refused to undergo a provocation test, resulting in a negative predictive value to immediate hypersensitivity reactions of 95.26%. Eight (8.9%) cases were confirmed as having IHR, 5 (62.5%) by ST and 3 (37.5%) by provocation test. Five from those confirmed as IHR (62.5%) had a positive BAT.

The rate of a positive skin test in the study of Sesé (2016) was 13.5% (95% CI 4 to 29%) and increased to 20% (95% CI 4 to 48%) for patients who consulted during the year after the HSR. Among the 32 patients with negative skin test results, 31 were challenged successfully, 15 with the culprit ICM. One grade I reaction occurred 2 h after challenge (generalized pruritus, erythema, and eyelid oedema lasting < 1 h) and was considered a positive intravenous challenge result. At 2 h after provocation test, two patients reported generalized and isolated pruritus that regressed with antihistamine therapy and was not considered a positive IPT result. None of five patients with positive skin test to ICM were re-exposed to contrast media during radiologic examination, positive predictive could not be calculated. For an immediate HSR to ICM, the negative predictive value for skin tests with low dose was 80% (95% CI 44 to 97%).

## 2. Diagnostic characteristics of cutaneous tests for *nonimmediate* hypersensitivity reactions

In Torres (2012), 34 subjects (21.1%) developed a positive delayed reading of the intradermal tests (13 at 1/10 dilution and 29 undiluted). Of these, 27 were skin-test positive to just one CM, 6 to two CM and 1 to three. The immediate reading of the intradermal tests was negative in all cases. The skin test was positive to iomeprol in 21 cases (50%), to iodixanol in 7 (16.7%), to iobitridol in 5 (11.9%), to ioxaglate in 4 (9.5%), to iohexol in 3 (7.1%) and to iopromide in 1 (2.4%). In the 34 cases with a positive intradermal test, 10 also had a positive patch test. No positive patch tests were detected in the patients with negative intradermal results. In the patients with a negative skin test to all the CM tested (N = 127), a provocation test was carried out with the CM involved. Provocation test was positive in 44 cases (34.6%), 19 to one CM and 3 to two CM. Thirty-eight cases (76%) were positive to iodixanol, 8 (16%) to iomeprol and 4 (8%) to iohexol. The time interval between administration and symptom development was: 1 to 6 h (13 cases), 7 to 12 h (27 cases), 13 to 24 h (68 cases), 25 to 48 h (41 cases) and > 48 h (12 cases).

## 3. Other tests

Meucci (2020) (n=98) reported NPV for skin tests of 96.2% for immediate hypersensitivity reactions and 58.8% for delayed hypersensitivity reactions, in favour of immediate hypersensitivity reactions ( $p < 0.0001$ ) when administering ICM different than the culprit. Furthermore, the NPV for the drug provocation test with culprit ICM was 50%. The NPV for the total diagnostic protocol was 92.3%, for patients undergoing a drug provocation test and exposure to the same ICM in a real-life setting.

## 4. Hypersensitivity reactions to gadolinium-based contrast agents (GBCA)

Results not reported.

### Quality of evidence

The level of evidence towards the outcome measure **diagnostic characteristics of cutaneous tests for HSR** was graded as very low due to high risk of bias (see Risk of Bias table in the Supplement 'Appendices to modules', downgraded by two points) and low number of patients (imprecision downgraded by one point).

## Conclusions

<b>Very Low GRADE</b>	<p>The negative predictive value of the cutaneous test is estimated to be 80 to 97% for immediate hypersensitivity reactions to contrast media.</p> <p>The negative predictive value of the cutaneous test is estimated to be 58-86% for nonimmediate hypersensitivity reactions to contrast media.</p> <p><i>Caimmi, 2010; Kim, 2013; Meucci 2020; Salas, 2013; Sesé, 2016; Torres, 2012</i></p>
-----------------------	---

### Justifications – evidence to decision

In a meta-analysis of skin testing the pooled per patient positivity rate increased with the severity of the hypersensitivity reaction, and skin testing was especially useful in more severe reactions (Yoon, 2015).

The status of skin testing in immediate HSR to ICM has recently been summarized excellently by the European Association of Allergy and Clinical Immunology (EAACI) in their Practice Parameters 2021 (Torres, 2021), and the committee decided to adhere and follow these recommendations that are outlined below. The same can be followed for immediate HSR to GBCA.

Testing will adhere to the general European Network of Drug Allergy – European Association of Allergy and Clinical Immunology standards (Brockow, 2002; Brockow, 2013; Torres, 2021). Intradermal testing has high sensitivity to identify allergic hypersensitivity reactions (Trautmann, 2019).

Non-severe nonimmediate HSR is often an MPE, which is self-limiting and resolves within 7 days (Bellin, 2011). In case of nonimmediate HSR the negative predictive value of skin testing is considerably lower than in immediate HSR (Caimmi, 2010; Kim, 2013; Meucci 2020; Salas, 2013; Sesé, 2016; Torres, 2012).

Because of the mild symptomatic burden of these patients and the limitations of allergologic skin testing the committee decided to not adhere to the EAACI guideline (Torres, 2021) and recommend against referral for skin testing in these patients.

It is the GDG opinion that change of CM is a more effective approach in patients with non-severe non-immediate HSR. Thereby it is important to note that nonionic dimeric ICM induce significantly more often cutaneous NIHRs than nonionic monomeric ICM. In fact, more than 50% of MPE are induced by the iso-osmolar ICM (Torres, 2021)

#### A) Immediate Hypersensitivity Reactions

Recommendations how to perform skin testing:

- When to test: STs are preferably performed within 2-6 months after the reaction. Performing STs < 1 month or > 12 months is expected to lower sensitivity.
- What to test: STs should be performed with the ICM involved in the reaction if known. If the result is positive or if the culprit ICM is unknown, STs should be performed with the broadest possible panel of ICM.
- How to test: ICM should be used undiluted at 300- 320 mg/mL for SPT and diluted at 1:10 for IDT. Addition of undiluted IDT may increase sensitivity but should be interpreted with caution. STs should start by performing SPT and, if negative, continue with IDT.



## B) Nonimmediate hypersensitivity reactions

Recommendations how to perform skin testing:

- When to test: for non-SCAR reactions, more than 4 weeks after the skin lesions have resolved but ideally within the first 6 months after the clinical reaction. Wait > 6 months in case of DRESS or AGEP
- What to test: ideally the suspected culprit and several commonly used alternatives due to the extended cross-reactivity in nonimmediate HSR. In DRESS and FDE, patch tests can be useful and SPT and IDT should preferably not be used directly, or in lower concentrations.
- How to test: IDT with 1:10 dilution of the standard concentration of ICM or undiluted on the upper arm or upper back with delayed reading after 48 and 72 hours. PT on the upper back with undiluted standard solution of ICM with reading at 48 hours and a delayed reading (72-120 hours). Patients should be instructed to return for additional readings in case of any later appearing skin reaction at the test site. Using both tests may enhance sensitivity.

If all tests are negative: Consider IDT and/or PT with undiluted CM in local testing, especially in FDE.

**Table 7.2.1 Positive rates of cutaneous tests in patients with immediate HSR to ICM**

		Positive rate of skin tests, %		Positive rate of IDT, % Severity of HSR		
		SPT <sup>a</sup>	IDT <sup>b</sup>	Mild	Moderate	Severe
Brockow, 2009	ICM <sup>c</sup>	3 (4/122)	26 (32/121)	26 (24/92)	-	28 (8/29)
Caimmi, 2010	ICM <sup>c</sup>	0 (0/101)	15 (15/101)	-	-	-
Dewachter, 2001	ICM <sup>c</sup>	50 (2/4)	100 (4/4)	-	-	100 (4/4)
Dewachter, 2011	ICM <sup>c</sup>	4 (1/24)	46 (12/26)	33 (3/9)	40 (4/10)	71 (5/7)
Goksel, 2011	ICM <sup>c</sup>	0 (0/14)	14 (2/14)	14 (1/7)	14 (1/7)	-
Kim, 2013	ICM <sup>c</sup>	3 (1/32)	26 (12/46)	13 (4/31)	25 (2/8)	57 (4/7)
Kim, 2014	ICM <sup>c</sup>	2 (1/51)	65 (33/51)	-	18 (2/11)	78 (31/40)
Meucci, 2020	ICM <sup>c</sup>	0 (0/)	10 (10/98)			23 (3/13)
Pinnobphun, 2011	ICM <sup>c</sup>	0 (0/63)	24 (15/63)	23 (12/53)	0 (0/5)	60 (3/5)
Prieto-Garcia, 2013	ICM <sup>c</sup>	0 (0/106)	10 (11/106)	9 (6/66)	14 (4/29)	9 (1/11)
Renaudin, 2013	ICM <sup>c</sup>	14 (1/7)	57 (4/7)	-	-	57 (4/7)
Salas, 2013	ICM <sup>c</sup>	3 (3/90)	6 (5/90)	0 (0/69)	11 (2/18)	100 (3/3)
Schrijvers, 2019	ICM <sup>c</sup>	13 (80/597)		Anaphylaxis grade 3-4 had a 6.8-fold (95%CI 3.2-14.5) increased risk for skin test positivity		
Sesé, 2016	ICM <sup>c</sup>	3 (1/37)	13.5% (5/37)	11 (4/37)	3 (1/37)	-
Trcka, 2008	ICM <sup>c</sup>	-	4 (4/96)	0 (0/40)	7 (3/44)	8 (1/12)

<sup>a</sup>SPT = Skin Prick Test; <sup>b</sup>IDT= Intradermal Test; <sup>c</sup>Iodine-based Contrast Media

### Performing and Reporting Skin Testing for Contrast Media

Most hospitals nowadays have contracts with just a few contrast media vendors. For skin testing of contrast media, however, it is important to test a panel of contrast agents (ICM and/or GBCA), including the culprit contrast agent and potential alternatives. Such a panel could be individualized for the specific hospital (group) where the patient comes from.

To facilitate establishment of such a local panel of iodine-based and gadolinium-based agents for allergic skin testing, we have listed the available agents in The Netherlands and their indications below.

See for physicochemical characteristics of ICM and GBCA also [Supplemental Tables S1 and S2](#).

**Table 7.2.2 Contrast agents in The Netherlands registered with the Medicine Evaluation Board**

<b>Iodine-based contrast media</b>			
<i>Name</i>	<i>Commercial Name</i>	<i>Company</i>	<i>Main Indication</i>
Iopromide	Ultravist	Bayer Healthcare	Intravascular CT/Angio
Iomeprol	Iomeron	Bracco Imaging	Intravascular CT/Angio
Iohexol	Omnipaque	GE Healthcare	Intravascular CT/Angio
Iodixanol	Visipaque	GE Healthcare	Intravascular CT/Angio
Ioversol	Optiray	Guerbet	Intravascular CT/Angio
Iobitridol	Xenetix	Guerbet	Intravascular CT/Angio
Amidotrizoate meglumine	Gastrografine	Bayer Healthcare	Gastrointestinal RF/CT
Ioxithalamate meglumine	Telebrix Gastro	Guerbet	Gastrointestinal RF/CT
<b>Gadolinium-based contrast agents</b>			
<i>Name</i>	<i>Commercial Name</i>	<i>Company</i>	<i>Allowed Indication</i>
Gadobutrol	Gadovist	Bayer Healthcare	Total Body MRI
Gadoteridol	ProHance	Bracco Imaging	Total Body MRI
Gadoterate meglumine	Dotarem/Artirem	Guerbet	Total Body MRI
	Clariscan	GE Healthcare	Total Body MRI
	Dotagraf	Bayer Healthcare	Total Body MRI
Gadoxetate disodium	Primovist	Bayer Healthcare	Liver MRI
Gadobenate dimeglumine	MultiHance	Bracco Imaging	Liver MRI
Gadopentetate meglumine	Magnevist	Bayer Healthcare	MR Arthrography

See also: <https://www.geneesmiddeleninformatiebank.nl/nl/>

### Documentation

When reporting skin tests, it is optimal that the allergologist gives a clear written recommendation in the electronic patient dossier about:

1. The possible ICM and/or GBCA that can be used in future CM-enhanced studies
2. The use of or need for specific prophylactic measures in future CM-enhanced studies if applicable

### **Recommendations**

Refer the patient to a drug allergy specialist to perform skin tests for the suspected culprit and several commonly used alternatives, ideally within 6 months after the hypersensitivity reaction.

Refer the following patient groups:

- Moderate to severe immediate hypersensitivity reactions to a contrast medium
- Severe mucocutaneous non-immediate hypersensitivity reactions to a contrast medium
- Hypersensitivity reactions to two or more different contrast media (e.g., two different iodine-based contrast media or gadolinium agents, or an iodine-based contrast medium and a gadolinium-based contrast agent)

- All patients with breakthrough hypersensitivity reactions despite premedication with corticosteroids and/or H1-antihistamines

Always specify the used contrast medium in the referral to the drug allergy specialist.

## Literature

- Ahn YH, Kang DY, Park SB, Kim HH, Kim HJ, Park GY, et al. Allergic-like hypersensitivity reactions to Gadolinium-Based Contrast Agents: an 8-year cohort study of 154,539 patients. *Radiology* 2022; 303(2): 329-336.
- Brockow K, Romano A, Blanca M, Ring J, Pichler W, Demoly P. General considerations for skin test procedures in the diagnosis of drug hypersensitivity. *Allergy*. 2002; 57(1): 45-51.
- Brockow K, Romano A, Aberer W, et al. Skin testing in patients with hypersensitivity reactions to iodinated contrast media - a European multicenter study. *Allergy*. 2009; 64(2): 234-241.
- Brockow K, Garvey LH, Aberer W, Atanaskovic-Markovic M, Barbaud A, Bilo MB, et al. Skin test concentrations for systemically administered drugs – an ENDA/ EAACI Drug Allergy Interest Group position paper. *Allergy* 2013; 68: 702-712.
- Brockow K. Medical algorithm: Diagnosis and treatment of radiocontrast media hypersensitivity. *Allergy*. 2020; 75(5): 1278-1280.
- Caimmi S, Benyahia B, Suau D, Bousquet-Rouanet L, Caimmi D, Bousquet PJ, Demoly P. Clinical value of negative skin tests to iodinated contrast media. *Clin Exp Allergy*. 2010; 40(5): 805-810.
- Gallardo-Higueras A, Moreno EM, Muñoz-Bellido FJ, Laffond E, Gracia-Bara MT, Macias EM, et al. Patterns of cross-reactivity in patients with immediate hypersensitivity reactions to gadobutrol. *J Investig Allergol Clin Immunol*. 2021; 31(6): 504-506.
- Grüber HP, Helbling A, Jörg L. Skin test results and cross-reactivity patterns in IgE- and T-cell-mediated allergy to gadolinium-based contrast agents. *Allergy Asthma Immunol Res* 2021; 13(6): 933-938.
- Kim SH, Jo EJ, Kim MY, Lee SE, Kim MH, Yang MS, Song WJ, Choi SI, Kim JH, Chang YS. Clinical value of radiocontrast media skin tests as a prescreening and diagnostic tool in hypersensitivity reactions. *Ann Allergy Asthma Immunol*. 2013; 110(4): 258-262.
- Kim SR, Park KH, Hong YJ, Oh YT, Park JW, Lee JH. Intradermal testing with radiocontrast media to prevent recurrent adverse reactions. *AJR Am J Roentgenol*. 2019; 213(6): 1187-1193.
- Meucci E, Radice A, Fassio F, et al. Diagnostic approach to hypersensitivity reactions to iodinated contrast media: a single-center experience on 98 patients. *Eur Ann Allergy Clin Immunol*. 2020; 52(5): 220-229.
- Salas M, Gomez F, Fernandez TD, Doña I, Aranda A, Ariza A, Blanca-López N, Mayorga C, Blanca M, Torres MJ. Diagnosis of immediate hypersensitivity reactions to radiocontrast media. *Allergy*. 2013; 68(9): 1203-1206.
- Schrijvers R, Breynaert C, Ahmedali Y, Bourrain JL, Demoly P, Chiriac AM. Skin testing for suspected iodinated contrast media hypersensitivity. *J Allergy Clin Immunol Pract*. 2018; 6(4): 1246-1254.
- Sesé L, Gaouar H, Autegarden JE, Alari A, Amsler E, Vial-Dupuy A, Pecquet C, Francès C, Soria A. Immediate hypersensitivity to iodinated contrast media: diagnostic accuracy of skin

- tests and intravenous provocation test with low dose. *Clin Exp Allergy*. 2016; 46(3): 472-478.
- Torres MJ, Gomez F, Doña I, Rosado A, Mayorga C, Garcia I, Blanca-Lopez N, Canto G, Blanca M. Diagnostic evaluation of patients with nonimmediate cutaneous hypersensitivity reactions to iodinated contrast media. *Allergy*. 2012; 67(7): 929-935.
- Torres MJ, Trautmann A, Böhm I, Scherer K, Barbaud A, Bavbek S, et al. Practice parameters for diagnosing and managing iodinated contrast media hypersensitivity. *Allergy*. 2021; 76(5): 1325-1339.
- Trautmann A, Brockow K, Behle V, Stoevesandt J. Radiocontrast media hypersensitivity: skin testing differentiates allergy from nonallergic reactions and identifies a safe alternative as proven by intravenous provocation. *J Allergy Clin Immunol Pract*. 2019; 7(7): 2218-2224.
- Yoon SH, Lee SY, Kang HR, Kim JY, Hahn S, Park CM, et al. Skin tests in patients with hypersensitivity reaction to iodinated contrast media: a meta-analysis. *Allergy*. 2015; 70(6): 625-637.

## Module 7.3 Risk Factors for Hypersensitivity Reactions to Contrast Media

This is an update of module 5.1 of the previous guideline [Safe Use of Contrast Media part 2](#).

### Clinical question

Which patients are at increased risk of developing hypersensitivity reactions after contrast media administration?

### Introduction

Like virtually any drug or substance, all types of contrast media have the potential to elicit a hypersensitivity reaction (HSR) (see also Introduction). Ideally, such adverse events are prevented, but this is difficult and to date not realistic. Identifying patients with an increased risk of developing HSRs would be a first step. General risk factors for an aggravated HSR include severe asthma, systemic mastocytosis, or the use of medication such as  $\beta$ -blockers. In addition, patient in need of contrast media (CM) administration may report HSRs to a previous CM administration. This can involve objective signs or symptoms that fit well with a hypersensitivity reaction. However, in many cases other complaints are reported, such as hyperventilation, vasovagal reactions, or stress-induced responses such as throat tightness or panic attacks. These may not fit accurately with a hypersensitivity reaction to CM and thus may affect the risk of a HSR at repeated exposure.

All types of contrast media will be evaluated: iodine-based, gadolinium-based, and microbubble ultrasound CM. Also, all types of administration routes will be covered, intravascular (intravenous or intra-arterial), oral and rectal, intracavitary (joints or bladder), and intraductal (bile or pancreatic ducts). Nonvascular CM administration has already been summarized in [Safe Use of Contrast Media, part 2](#).

### Search and select

A systematic review of the literature was performed to answer the following question: *Which factors are related to an increased risk of developing hypersensitivity reactions after contrast administration?*

<b>P:</b> (patients)	Patients undergoing radiological examinations with contrast media
<b>I:</b> (intervention)	Presence of prognostic factors
<b>C:</b> (control)	Absence of prognostic factors
<b>O:</b> (outcome)	Allergic reactions to contrast media, hypersensitivity reaction, type I / type IV, severe allergic reaction

### Relevant outcome measures

The working group considered allergic / hypersensitivity reactions to contrast media critical outcome measures for the decision-making process.

### Search and select (Methods)

The databases Medline (via OVID) and Embase (via Embase.com) were searched with relevant search terms until April 22<sup>nd</sup>, 2021. The detailed search strategy is depicted under the tab Methods. The systematic literature search resulted in 400 hits.

Studies were selected based on the following criteria:

- Adult patients undergoing radiological examinations with contrast media.

- Evaluation or identification of factors associated with an increased risk of hypersensitivity reactions after contrast administration. These factors could be treatment related, or patient related. Studies were only included when the identified risk factors were corrected for confounders (multivariate models).
- Reports predefined outcome measure: hypersensitivity reactions.
- No reports of case series or exploratory findings ( $n \geq 10$ ).

Based on title and abstract a total of forty-seven studies were selected. After examination of full text, a total of forty-two studies were excluded and five studies were included in the literature summary. Reason for exclusion is reported in the exclusion table.

Five studies were included for the research question regarding the identification of factors associated with an increased risk of hypersensitivity reactions after contrast administration. The most important study characteristics and results were included in the evidence tables. The evidence tables and assessment of individual study quality are included.

## Summary of literature

### Description of studies

A total of 3 studies from [Safe Use of Contrast Media, part 2](#) described factors independently related to the risk of hypersensitivity reactions after contrast administration. All studies presented multivariate models, but no internal or external validation of these models, or the results of application of these models in clinical practice.

A total of five studies described factors independently related to the risk of hypersensitivity reactions after contrast media administration. All studies presented multivariate models, but no internal or external validation of these models, or the results of application of these models in clinical practice.

Cha (2019) in a prospective cohort study described the risk factors associated with iodinated contrast media (ICM) -related hypersensitivity reactions in 196081 patients who underwent contrast-enhanced CT examinations from seven tertiary referral hospitals in Korea.

Chen (2015) described the risk factors associated with adverse reactions (occurring within 1 hour after contrast administration) in 17,513 patients who were administered iopromide (300 or 370 mgI/mL) contrast during coronary angiography or Percutaneous Coronary Intervention (PCI). All patients (not high-risk patients only) were included in this multicentre (63 centres in China) study.

Endrikat (2020) in a case control study described the risk factors associated with hypersensitivity reactions to iopromide after intra-arterial administration and intravenous (IV) administration in 133,331 patients undergoing angiographic procedures (mostly cardio angiography) or contrast-enhanced CT. Four observational studies were pooled. Almost half of the study population (48.1%) was from Europe, and one quarter each from China (27.6%) and other Asia countries (24.1%). Hypersensitivity reactions were recorded for 822 patients, and 132,509 patients served as controls.

Kim (2017) in a retrospective cohort described the risk factors associated with immediate adverse drug reactions (ADRs) occurred within 1 h after administration of radiocontrast media (RCMs) in 1969 immediate ADRs from 286,087 examinations of 142,099 patients who underwent contrast-enhanced computed tomography (CT) examinations.

Jung (2016) described risk factors for developing a hypersensitivity reaction after re-administration of low-osmolality iodinated contrast medium for enhanced computed tomography in 322 patients with a history of hypersensitivity reactions after low-osmolality contrast administration. A total of 219 (68%) of the patients had a mild reaction, while 82 (26%) had a moderate reaction, and 21 (7%) a severe reaction in their history. Premedication was decided on an individual basis by clinicians and could consist of oral and/or intravenous H1-antihistamines, H2-antihistamines and corticosteroids.

Park (2017) described risk factors for developing a hypersensitivity reaction after administration of low-osmolar iodinated contrast medium for enhanced computed tomography in 150 patients with a history of moderate 130 (87%) to severe 20 (13%) hypersensitivity reactions after contrast administration in 328 instances of re-exposure. Patients received antihistamines and/or corticosteroids as pre-medication, the exact premedication was decided on an individual basis.

Park (2019) in a retrospective cohort described the risk factors associated with non-ionic ICM related hypersensitivity reactions in 21,947 adults during the control period and 26,491 patients during intervention period undergoing contrast-enhanced abdominal CT. Compared with CT during the control period, CT during the intervention period involved a reduced dose of contrast media achieved by lowering the CT tube voltage. Antihistamines alone were used for mild reactions, and steroids were used for moderate or severe reactions as pre-medication.

Sohn (2019) in a prospective cohort study described the risk factors associated with immediate and delayed coronary angiography (CAG)-induced ICM hypersensitivity in 714 patients who underwent CAG using intra-arterial (IA) administration of ICM including ioversol, a low-osmolar non-ionic monomer, and iodixanol, an iso-osmolar non-ionic dimer.

### Results

Cha (2019) reported that the overall prevalence of HSRs was 0.73% (1,433 of 196,081), while severe reactions occurred in 0.01% (17 of 196,081). In terms of severity, 83.2% of the events were classified as mild HSRs, with a relative prevalence of 83.2% (overall 0.61%; 1,192 of 196,081); 15.6% as moderate HSRs (overall 0.11%; 224 of 196,081); and 1.2% as severe HSRs (overall 0.01%; 17 of 196,081).

The following factors were associated with increased risk of occurrence and recurrence of ICM related HSRs:

- Hyperthyroidism (OR: 4.00, 95% CI: 1.4 to 12.1)
- Drug allergy (OR: 5.2, 95% CI: 2.8 to 9.7)
- Asthma (OR: 2.3, 95% CI: 1.1 to 4.9)
- Other allergic disease (OR: 9.5, 95% CI: 4.1 to 22.1)
- Past history of ICM exposure
  - HSR to ICM (OR: 56.3, 95% CI: 20 to 151)
- Family history
  - HSR to ICM (OR: 11.1, 95% CI: 1.4 to 85.9)

The following factor were associated with decreased risk of occurrence and recurrence of ICM related HSRs:

- Past history of ICM exposure  
No HSR to ICM usage (OR: 0.7, 95% CI: 0.6 to 0.8)

Chen (2015) reported that acute adverse drug reactions (ADRs) occurred in 66/17,513 (0.38%) patients undergoing iopromide (300 or 370 mgI/mL) administration during coronary angiography or Percutaneous Coronary Intervention (PCI), out of which 2 ADRs (0.01%) were severe. Most ADRs manifested as nausea vomiting (0.22%) and rash (0.09%).

The following factors were associated with risk of ADR:

- Age 50 to 69 versus age < 50 (OR: 0.48, 95% CI: 0.27 to 0.85).
- Premedication with corticosteroids (OR: 0.41, 95% CI: 0.18 to 0.97).
- Contrast dose  $\geq$  100mL (OR 0.50, 95% CI 0.30 to 0.82).
- Pre-procedural hydration (OR: 0.11, 95% CI: 0.04 to 0.33).
- Left main coronary disease (OR: 2.27, 95% CI: 1.15 to 4.48).
- Previous ADR to contrast (OR: 9.30, 95% CI: 1.10 to 78.84).

Allergic constitution, asthma and sex were not independently associated with the risk of developing an adverse reaction.

Endrikat (2020) reported HSR in 822/133,331 patients (0.62%). The most frequent hypersensitivity reactions were skin reactions (erythema, urticaria, rash), reported in 508 patients (0.38%), followed by pruritus (n = 294; 0.22%), cough/ sneezing (n = 151; 0.11%), and dyspnoea/bronchospasm (n = 105; 0.08%). Hypersensitivity reactions were significantly more frequently recorded after IV than after IA administration, 0.7% versus 0.2%, respectively. Their follow-up study (Endrikat, 2022) reported a decreased risk of HSR in elderly > 65 years, at least when iopromide was used.

The following factors were associated with increased risk of HSR:

- Age
  - 50-<65 (OR: 1.67, 95% CI: 1.38 to 2.02)
  - 18-<50 (OR: 2.16, 95% CI: 1.78 to 2.62)
- Female (OR: 1.16, 95% CI: 1.01 to 1.34)
- Diabetes mellitus (OR: 1.54, 95% CI: 1.19 to 2.00)
- Allergy (OR: 3.61, 95% CI: 2.84 to 4.59)
- Asthma (OR: 2.14, 95% CI: 1.26 to 3.62)
- Previous contrast media reaction (OR: 4.31, 95% CI: 2.75 to 6.75)
- Other concomitant disease: (OR: 1.42, 95% CI: 1.19 to 1.70)
- Geographic region: Asia (OR: 1.80, 95% CI: 1.54 to 2.11)
- Dose of iodine in CM
  - >20–40 g (OR: 1.24, 95% CI: 1.01 to 1.51)
- Iopromide concentration
  - Iopromide 370 (OR: 1.31, 95% CI: 1.12 to 1.54)

The following factor were associated with decreased risk of HSR:

- IA Injection route (OR: 0.23, 95% CI: 0.16 to 0.32)
- >65 (OR: 0.51 95% CI: 0.43 to 0.61)

Jung (2016) described that 47/322 (15%) of the patients experienced a recurrence of an allergic reaction after low-osmolality iodinated contrast medium administration for computed tomography, despite premedication.

The following factors were associated with an increased risk for developing this second acute allergic-like adverse reaction:

- Age (OR: 0.97, 95% CI: 0.94 to 0.99).
- Previous severe reaction (OR: 8.88, 95% CI: 2.11 to 37.42).



- Not using corticosteroid premedication (OR: 0.28, 95% CI: 0.10 to 0.78) - people that used corticosteroid medications had a lower risk to experience an allergic reaction. The following factors were not independently associated with the risk of acute allergic-like adverse reactions: sex, bronchial asthma, allergic rhinitis, chronic urticaria, food allergy, other drug allergy, H2-antihistamines premedication.

Kim (2017) reported that immediate adverse drug reactions (ADRs) occurred in 1969 cases of ADR (0.69%) among 286,087 cases in 142,099 patients who underwent contrasted CT examinations. Rash (85.3%) and itching sensation (59.8%) were the most frequent symptoms. Among these immediate ADRs, 68 cases were classified as anaphylaxis (0.024%). They found that iopromide had the highest incidence of immediate ADRs (1.03%) and was followed by iopamidol (0.67%), iohexol (0.64%), and iobitridol (0.34%). In cases of anaphylaxis, iopromide also showed the highest incidence (0.041%), followed by iopamidol (0.023%), iohexol (0.018%), and iobitridol (0.012%).

The following factors were associated with increased risk of immediate ADR:

- Types of RCMs (compared to iobitridol)
  - Iohexol (OR: 1.36, 95% CI: 1.08 to 1.72)
  - Iopamidol (OR: 1.59, 95% CI: 1.28 to 1.98)
  - Iopromide (OR: 2.72, 95% CI: 2.17 to 3.41)
- Multiple CT examinations (OR: 2.13, 95% CI: 1.89 to 2.38)
- Female sex (OR: 1.51, 95% CI: 1.36 to 1.67)
- Age 20 to 50 (OR: 1.55, 95% CI: 1.01 to 2.37)
- Body weight (OR: 1.02, 95% CI: 1.01 to 1.02)

The following factors were associated with increased risk of anaphylaxis:

- Iopromide (OR: 6.24, 95% CI: 1.32 to 29.44)
- Multiple CT examinations (OR: 3.26, 95% CI: 1.81 to 5.86)

The following factors were not independently associated with the risk of anaphylaxis: iohexol, iopamidol, sex, age, and body weight.

Park (2017) reported that a recurrence of hypersensitivity reactions after contrast exposure occurred in 64/328 (20%) of the instances of re-exposure to low-osmolar iodinated contrast in patients with a history of moderate or severe reactions.

The following factors were associated with an increased risk for developing this second hypersensitivity reaction:

- Age (OR: 0.97, 95% CI 0.94 to 0.99);
- Diabetes mellitus (OR: 6.49, 95% CI: 2.38 to 17.71);
- Chronic urticaria (OR: 7.61, 95% CI: 1.63 to 35.59);
- Drug allergy (OR: 3.69, 95% CI: 1.18 to 11.56);
- Changing the iodinated contrast medium (OR: 0.33, 95% CI: 0.17 to 0.64);
- Initial hypersensitivity reaction was severe (OR: 2.67, 95% CI: 1.05 to 6.79).

The following factors were not independently associated with the risk of developing a recurrent hypersensitivity reaction: sex, use of premedication.

Park (2019) reported the following factors associated with increased risk of acute HSRs:

- Female (RR: 1.22 (95% CI: 1.04 to 1.43)
- History of acute hypersensitivity to iodinated contrast material (RR: 10.4, 95% CI: 4.51 to 24.2)

- Contrast media used for study CT
  - Iomeprol (RR: 4.48, 95% CI: 3.09 to 6.48)
- Iodine concentration for study CT
  - 350 mg I/mL (RR: 4.66, 95% CI: 2.92 to 7.42)
  - ≥370 mg I/mL (RR: 2.83, 95% CI: 2.13 to 3.77)

The following factor were associated with decreased risk of acute HSRs:

- Age (RR: 0.98, 95% CI: 0.97 to 0.98)
- Premedication for study CT
  - Antihistamines alone (RR: 0.39, 95% CI: 0.17 to 0.9)
  - Steroid with or without antihistamines (RR: 0.37, 95% CI: 0.16 to 0.89)
- Type of CT examination
  - Multiphase (RR: 0.41, 95% CI: 0.32 to 0.52)

Sohn (2019) reported 26 of 714 (3.6%) patients with immediate HSR and 108 of 714 (15.1%) with non-immediate HSR after IA contrast administration. With regard to severity, the proportion of immediate HSR grades 1, 2, and 3 was 57.7%, 38.5%, and 3.8%, respectively, whereas that of non-immediate HSR grades 1, 2, and 3 was 85.2%, 13.9%, and 0.9%, respectively.

The following factors were associated with increased risk of immediate and nonimmediate HSR:

- Immediate HSR: Previous IA exposure (OR: 2.92, 95% CI: 1.22 to 6.96)
- Nonimmediate HSR: Iodixanol (OR: 1.61, 95% CI: 1.07 to 2.43)

Level of evidence of the literature

For all included patient populations, the quality of certainty of evidence for the outcome hypersensitivity reaction was downgraded from high to low by two points, due to risk of bias and indirectness: the prognostic factors were identified, but the prognostics model was not validated internally and externally. The value of the applicability of the multivariate models in a clinical decision-making process was not evaluated. The study sample in the primary studies do not accurately reflect the review question.

**Conclusions**

<b>Low GRADE</b>	<p>The following factors were associated with an increased risk of adverse drug reaction in patients undergoing coronary angiography or percutaneous coronary intervention and receiving iopromide contrast:</p> <ul style="list-style-type: none"> <li>• Age &lt; 50 years</li> <li>• No premedication with corticosteroids</li> <li>• Contrast dose &lt; 100mL</li> <li>• No pre-procedural hydration</li> <li>• Left main coronary disease</li> <li>• Previous ADR to contrast</li> </ul> <p>Allergic constitution, asthma and sex were not independently associated with the risk of developing an adverse reaction.</p> <p><i>Chen, 2015</i></p>
------------------	---

<b>Low GRADE</b>	<p>The following factors were associated with an increased risk for developing a <b>second</b> acute allergic-like adverse reaction in patients with a history of a</p>
------------------	---

	<p>hypersensitivity reaction after low-osmolality contrast administration, who were undergoing another enhanced computed tomography with low-osmolality contrast medium and receiving premedication:</p> <ul style="list-style-type: none"> <li>• Younger age</li> <li>• Previous severe reaction</li> <li>• No corticosteroid premedication</li> </ul> <p>The following factors were not independently associated with the risk of acute allergic-like adverse reactions: sex, bronchial asthma, allergic rhinitis, chronic urticaria, food allergy, other drug allergy, H2-antihistamines premedication.</p> <p><i>Jung, 2016</i></p>
--	---

<b>Low GRADE</b>	<p>The following factors were associated with increased risk of immediate HSR:</p> <ul style="list-style-type: none"> <li>• Types of RCMs (compared to iobitridol) <ul style="list-style-type: none"> <li>○ Iohexol (OR: 1.36, 95% CI: 1.08 to 1.72)</li> <li>○ Iopamidol (OR: 1.59, 95% CI: 1.28 to 1.98)</li> <li>○ Iopromide (OR: 2.72, 95% CI: 2.17 to 3.41)</li> </ul> </li> <li>• Multiple CT (OR: 2.13, 95% CI: 1.89 to 2.38)</li> <li>• Female (OR: 1.51, 95% CI: 1.36 to 1.67)</li> <li>• Age 20 to 50 (OR: 1.55, 95% CI: 1.01 to 2.37)</li> <li>• Body weight (OR: 1.02, 95% CI: 1.01 to 1.02)</li> </ul> <p>The following factors were associated with increased risk of anaphylaxis:</p> <ul style="list-style-type: none"> <li>• Iopromide (OR: 6.24, 95% CI: 1.32 to 29.44)</li> <li>• Multiple CT (OR: 3.26, 95% CI: 1.81 to 5.86)</li> </ul> <p>The following factors were not independently associated with the risk of anaphylaxis: Iohexol, Iopamidol, sex, age, and body weight.</p> <p><i>Kim, 2017</i></p>
------------------	--

<b>Low GRADE</b>	<p>The following factors were associated with increased risk of occurrence and recurrence of ICM-related HSRs:</p> <ul style="list-style-type: none"> <li>• Hyperthyroidism (OR: 4.00, 95% CI: 1.4 to 12.1)</li> <li>• Drug allergy (OR: 5.2, 95% CI: 2.8 to 9.7)</li> <li>• Asthma (OR: 2.3, 95% CI: 1.1 to 4.9)</li> <li>• Other allergic disease (OR: 9.5, 95% CI: 4.1 to 22.1)</li> <li>• Past history of ICM exposure <ul style="list-style-type: none"> <li>○ HSR to ICM (OR: 56.3, 95% CI: 20 to 151)</li> </ul> </li> <li>• Family history <ul style="list-style-type: none"> <li>○ HSR to ICM (OR: 11.1, 95% CI: 1.4 to 85.9)</li> </ul> </li> </ul> <p>The following factor were associated with decreased risk of occurrence and recurrence of ICM related HSRs:</p> <ul style="list-style-type: none"> <li>• Past history of ICM exposure <ul style="list-style-type: none"> <li>○ No HSR to ICM usage (OR: 0.7, 95% CI: 0.6 to 0.8)</li> </ul> </li> </ul> <p><i>Cha, 2019</i></p>
------------------	---

<b>Low GRADE</b>	<p>The following factors were associated with an increased risk for developing a <b>second</b> hypersensitivity reaction in patients with a history of a moderate or severe hypersensitivity reaction after low-osmolality contrast administration, who were undergoing another enhanced computed tomography with low-osmolality contrast medium and receiving premedication:</p> <ul style="list-style-type: none"> <li>• Younger age</li> <li>• Diabetes mellitus</li> <li>• Chronic urticaria</li> <li>• Drug allergy</li> <li>• Not changing the iodinated contrast medium</li> <li>• Initial hypersensitivity reaction was severe</li> </ul> <p>The following factors were not independently associated with the risk of developing a recurrent hypersensitivity reaction: sex, use of premedication.</p> <p><i>Park, 2017</i></p>
------------------	---

<b>Low GRADE</b>	<p>The following factors were associated with increased risk of immediate HSRs:</p> <ul style="list-style-type: none"> <li>• Female (RR: 1.22 (95% CI: 1.04 to 1.43)</li> <li>• History of acute hypersensitivity to iodinated contrast material (RR: 10.4, 95% CI: 4.51 to 24.2)</li> <li>• Contrast media used for study CT <ul style="list-style-type: none"> <li>○ Iomeprol (RR: 4.48, 95% CI: 3.09 to 6.48)</li> </ul> </li> <li>• Iodine concentration for study CT <ul style="list-style-type: none"> <li>○ 350 mg I/mL (RR: 4.66, 95% CI: 2.92 to 7.42)</li> <li>○ ≥370 mg I/mL (RR: 2.83, 95% CI: 2.13 to 3.77)</li> </ul> </li> </ul> <p>The following factor were associated with <b>decreased</b> risk of acute HSRs:</p> <ul style="list-style-type: none"> <li>• Age (RR: 0.98, 95% CI: 0.97 to 0.98)</li> <li>• Premedication for study CT <ul style="list-style-type: none"> <li>○ Antihistamine alone (RR: 0.39, 95% CI: 0.17 to 0.9)</li> <li>○ Steroid with or without antihistamine (RR: 0.37, 95% CI: 0.16 to 0.89)</li> </ul> </li> <li>• Type of CT examination <ul style="list-style-type: none"> <li>○ Multiphase (RR:0.41, 95% CI: 0.32 to 0.52)</li> </ul> </li> </ul> <p><i>Park, 2019</i></p>
------------------	--

<b>Low GRADE</b>	<p>The following factors were associated with increased risk of immediate and nonimmediate HSR:</p> <ul style="list-style-type: none"> <li>• Immediate HSR: Previous IA exposure (OR: 2.92, 95% CI: 1.22 to 6.96)</li> <li>• Nonimmediate HSR: Iodixanol (OR: 1.61, 95% CI: 1.07 to 2.43)</li> </ul> <p><i>Sohn, 2019</i></p>
------------------	---

<b>Low GRADE</b>	<p>The following factors were associated with increased risk of HSR:</p> <ul style="list-style-type: none"> <li>• Age <ul style="list-style-type: none"> <li>○ 50-&lt;65 (OR: 1.67, 95% CI: 1.38 to 2.02)</li> <li>○ 18-&lt;50 (OR: 2.16, 95% CI: 1.78 to 2.62)</li> </ul> </li> <li>• Female (OR: 1.16, 95% CI: 1.01 to 1.34)</li> </ul>
------------------	---

	<ul style="list-style-type: none"> <li>• Diabetes mellitus (OR: 1.54, 95% CI: 1.19 to 2.00)</li> <li>• Allergy (OR: 3.61, 95% CI: 2.84 to 4.59)</li> <li>• Asthma (OR: 2.14, 95% CI: 1.26 to 3.62)</li> <li>• Previous contrast media reaction (OR: 4.31, 95% CI: 2.75 to 6.75)</li> <li>• Other concomitant disease: (OR: 1.42, 95% CI: 1.19 to 1.70)</li> <li>• Geographic region: Asia (OR: 1.80, 95% CI: 1.54 to 2.11)</li> <li>• Dose of iodine in CM <ul style="list-style-type: none"> <li>○ &gt;20–40 g (OR: 1.24, 95% CI: 1.01 to 1.51)</li> </ul> </li> <li>• Iopromide concentration <ul style="list-style-type: none"> <li>○ Iopromide 370 (OR: 1.31, 95% CI: 1.12 to 1.54)</li> </ul> </li> </ul> <p>The following factor were associated with increased risk of HSR:</p> <ul style="list-style-type: none"> <li>• IA Injection route (OR: 0.23, 95% CI: 0.16 to 0.32)</li> </ul> <p><i>Endrikat, 2020</i></p>
--	---

### Justifications – evidence to decision

Although various potential risk factors were identified in the five studies mentioned above, there are several limitations to be addressed.

First, all reported data solely address iodine-based contrast media (ICM). It is not clear whether these findings can be extrapolated to gadolinium-based contrast agents (GBCA).

Second, hypersensitivity reactions are generally diagnosed on clinical symptoms only and often in retrospect. Therefore, it is likely that the outcome group in many studies consists of a mixture of true HSR and other, nonimmune-mediated adverse events caused by severe physiological effects, chemotoxic effects and/or anxiety (Lalli, 1974). The increased odds ratio reported by Cha, 2019 for hyperthyroidism suggests inclusion of other reactions, since this risk factor was not reported by any other study and is suggestive of iodine-induced hyperthyroidism, which may present with clinical features with a certain overlap to mild hypersensitivity reactions.

Third, the hypersensitivity reactions are analysed together, while stratification for immediate vs nonimmediate reactions and based on severity would be preferred. Since immediate (IgE- or non-IgE-mediated mast cell activation) and nonimmediate (T-cell mediated) HSR are pathophysiological distinct, we assume that risk factors may be different as well. For example, a genetic predisposition is possible for T-cell mediated nonimmediate HSR since different HLA types may predispose for certain drug hypersensitivity reactions. Since mast cells belong to the innate immune system, it is from a pathophysiological standpoint hard to understand why there would be an increased risk in certain families, except for rare forms of familial mastocytosis.

Moreover, except for Kim, 2017, none of the studies stratified outcomes according to severity of the HSR. This is important, since identifying risk factors for severe reactions such as anaphylaxis has the highest clinical relevance. Cha, 2019 and colleagues reported that 968 (68.8%) of the 1433 patients with an ICM-related HSR recovered spontaneously; identifying a risk factor for a self-limiting reaction has little clinical relevance and will not lead to adaption of protocols. Only the study by Kim (2017) reported outcomes separately for anaphylaxis. Since anaphylaxis is rare, it is difficult to gain sufficient power for statistical analyses.

Fourth, the robustness of findings depends on validation by other studies. A previous reaction to CM has been reported by several studies and is therefore more likely to be relevant than hyperthyroidism or a positive family history.

Fifth, the absolute OR or RR adds to the clinical relevance. Kim et al. (Kim, 2017) proposed risk factor “body weight” (which is not clearly mentioned in the results, table 2 suggests that a higher body weight may be a risk factor but remains unclear) is a risk factor for (all) immediate HSR. With an OR of 1.02 this is of no clinical relevance, aside from the other limitations. Overall, the highest odds ratios were noted for previous CM reactions.

As mentioned before, it is uncertain whether previous reactions would be a risk factor for GBCA as well since literature on GBCA is scarce. A meta-analysis of nine studies in which immediate reactions to GBCA were recorded from a total of 716,978 GBCA administrations met the criteria for inclusion. The overall and severe rates of GBCA allergic-like adverse events were 9.2 and 0.52 per 10,000 administrations, respectively: 539 of 662 (81%) were mild, 86 (13%) were moderate, and 37 (6%) were severe reactions. The nonionic linear chelate gadodiamide had the lowest rate of reactions, at 1.5 per 10,000 administrations, which was significantly less than that of linear ionic GBCAs at 8.3 and nonionic macrocyclic GBCAs at 16 per 10,000 administrations. GBCAs known to be associated with protein-binding (like gadobenate) had a higher rate of reactions, at 17 per 10,000 administrations compared with the same chelate classification without protein binding, at 5.2 per 10,000 administrations (Behzadi, 2018).

A large retrospective study in children and adults studied all intravenous GBCA injections performed at a single institution. A total of 158,100 patients received 281,945 GBCA injections (140,645 gadodiamide, 94,109 gadobutrol, 39,138 gadobenate, and 8,053 gadoterate). At multivariate analysis, gadobenate or gadobutrol had higher rates of allergic-like reactions compared with gadodiamide (gadobenate: odds ratio (OR), 3.9; gadobutrol: OR, 2.3) or gadoterate (gadobenate: OR, 4.8; gadobutrol: OR, 2.8). Six severe allergic-like reactions (three gadobutrol, three gadobenate) occurred requiring hospitalization. Patient age ( $P = 0.025$  to  $< 0.001$ ), sex ( $P < 0.001$ ), location ( $P = 0.006$ ), and MRI type ( $P = 0.003$  and  $P = 0.006$ ) were associated with acute reactions (McDonald, 2019).

Thus, both studies suggest that the type of GBCA may be a relevant risk factor, but do not take the severity of the reaction into account. The importance is limited as the total reaction rate is very low and the large majority of those reactions are mild and self-limiting.

Taken together, a previous reaction to CM appears to be the only clinically relevant risk factor for developing a new hypersensitivity reaction based on the currently available literature. It is plausible that the same holds true for GBCA, although there is currently not enough literature available to solidly confirm this.

In the ACR Manual on Contrast Media v.2021 (ACR, 2022) and the ESUR v10 guidelines (ESUR 2018), the most significant risk factor for increased risk of hypersensitivity reactions remains a documented history of a previous hypersensitivity reaction to a contrast medium. Patients with atopy/bronchial asthma or multiple allergies could not be established as a consistent risk factor (Chen, 2015; Jung, 2016).

## Recommendations



Only consider a previous hypersensitivity reaction after contrast media administration a relevant risk factor for developing a new hypersensitivity reaction.

## Literature

- American College of Radiology. ACR Manual on contrast media, v2022. Available at: [\[URL\]](#). Accessed: 15. April 2022.
- Behzadi AH, Zhao Y, Farooq Z, Prince MR. Immediate allergic reactions to gadolinium-based contrast agents: systematic review and meta-analysis. *Radiology* 2018; 286: 471-482.
- Cha MJ, Kang DY, Lee W, Yoon SH, Choi YH, Byun JS, Lee J, Kim YH, Choo KS, Cho BS, Jeon KN, Jung JW, Kang HR. Hypersensitivity Reactions to iodinated contrast media: a multicenter study of 196,081 patients. *Radiology*. 2019; 293:117-124.
- Chen JY, Liu Y, Zhou YL, et al. Safety and tolerability of iopromide in patients undergoing cardiac catheterization: real-world multicenter experience with 17,513 patients from the TRUST trial. *Int J Cardiovasc Imaging* 2015; 31: 1281-1291.
- Endrikat J, Michel A, Kölbach R, Lengsfeld P, Vogtländer K. Risk of hypersensitivity reactions to iopromide after intra-arterial versus intravenous administration: a nested case-control analysis of 133,331 patients. *Invest Radiol*. 2020; 55:38-44.
- European Society of Urogenital Radiology Contrast Media Safety Committee. ESUR Guidelines on contrast safety, v10. Available at: [\[URL\]](#). Accessed: 15. April 2022.
- Jung JW, Choi YH, Park CM, Park HW, Cho SH, Kang HR. Outcomes of corticosteroid prophylaxis for hypersensitivity reactions to low osmolar contrast media in high-risk patients. *Ann Allergy Asthma Immunol* 2016; 117: 304-309.
- Kim SR, Lee JH, Park KH, Park HJ, Park JW. Varied incidence of immediate adverse reactions to low-osmolar non-ionic iodide radiocontrast media used in computed tomography. *Clin Exp Allergy*. 2017; 47:106-112.
- McDonald JS, Hunt CH, Kolbe AB, Schmitz JJ, Hartman RP, et al. Acute adverse events following Gadolinium-Based Contrast Agent administration: a single-center retrospective study of 281,945 injections. *Radiology* 2019; 292: 620-627.
- Park HJ, Park JW, Yang MS, Kim MY, Kim SH, Jang GC, et al. Re-exposure to low osmolar iodinated contrast media in patients with prior moderate-to-severe hypersensitivity reactions: A multicentre retrospective cohort study. *Eur Radiol* 2017; 27: 2886-2893.
- Park HJ, Son JH, Kim TB, Kang MK, Han K, Kim EH, Kim AY, Park SH. Relationship between lower dose and injection speed of iodinated contrast material for CT and acute hypersensitivity reactions: An observational study. *Radiology*. 2019; 293:565-572.
- Pichler WJ. The important role of non-covalent drug-protein interactions in drug hypersensitivity reactions. *Allergy*. 2022; 77(2): 404-415.
- Sohn KH, Kim GW, Lee SY, Kim HS, Cho SH, Han JK, Kang HR. Immediate and delayed hypersensitivity after intra-arterial injection of iodinated contrast media: a prospective study in patients with coronary angiography. *Eur Radiol*. 2019; 29: 5314-5321.

## Module 7.4 Prophylactic Measures for Prevention of Recurrent Hypersensitivity Reactions to Contrast Media

This is an update of module 5.2 of the previous guideline [Safe Use of Contrast Media part 2](#).

### Clinical question

Which prophylactic measures should be taken in patients at increased risk of hypersensitivity reactions to contrast media?

This question contains the following patient categories:

- I Patients with previous immediate (acute) hypersensitivity reactions to iodine-based contrast media or gadolinium-based contrast agents
- II Patients with a previous breakthrough reaction to contrast media
- III Patients with previous hypersensitivity reactions to multiple contrast media
- IV Patients with previous nonimmediate (delayed) hypersensitivity reactions to iodine-based contrast media or gadolinium-based contrast agents

In addition, the following subjects were elaborated:

- V Cross-reactivity between contrast media
- VI Documentation of hypersensitivity reactions

### Introduction

Patients reporting a previous hypersensitivity reaction (HSR) to contrast media are at increased risk of developing a recurrent hypersensitivity reaction upon re-exposure (see Module 7.3). It is unclear what the best strategy is to prevent such a recurrent hypersensitivity reaction.

Options include complete avoidance of contrast media and performing alternative imaging techniques, which may lead to inferior quality of the diagnostic modality or higher costs, depending on the modality used. Alternatively, contrast media can be alternated to a different agent, and/or so-called premedication may be employed. Premedication consists of antihistamines with or without corticosteroids, with the aim to prevent a hypersensitivity reaction. Different protocols for premedication (Greenberger, 1981; Greenberger, 1984; Greenberger, 1986; Lasser, 1994) are still in widespread use, often slightly modified, but there is no literature to establish an optimal indication or protocol. The older protocols have been challenged by newer, shorter options for inpatients (Mervak, 2017). Moreover, the use of premedication is a current topic of debate, as the literature on the effectiveness of premedication prior to CM administration remains unclear and particularly corticosteroids have relevant adverse effects.

All types of contrast media can give hypersensitivity reactions. See further the [Introduction](#) to this chapter.

All types of contrast media will be evaluated: iodine-based, gadolinium-based, microbubble, CM. Also, all types of administration routes will be covered, intravascular (intravenous or intra-arterial), oral and rectal, intracavitary (joints or bladder), and intraductal (bile or pancreatic ducts). See separate chapter for nonvascular CM administration.

### Search and select



A systematic review of the literature was performed to answer the following question: What are the effects of prophylactic measures to prevent hypersensitivity reactions after contrast media administration?

- P (Patients):** Patients undergoing radiological examinations with contrast media.  
**I (Intervention):** Prophylactic measure to prevent hypersensitivity reactions after contrast administration.  
**C (Comparison):** No prophylactic measure or a different prophylactic measure to prevent hypersensitivity reactions after contrast administration.  
**O (Outcome):** Allergic reactions to contrast media, hypersensitivity reaction, type I/type IV, severe allergic reaction.

#### Relevant outcome measures

The working group considered *allergic / hypersensitivity reactions to contrast* as critical outcome measures for the decision-making process.

#### Search and select (Methods)

The databases Medline (via OVID) and Embase (via Embase.com) were searched with relevant search terms until April 22<sup>nd</sup>, 2021. The detailed search strategy is depicted under the tab Methods. The systematic literature search resulted in 400 hits. Studies were selected based on the following criteria

- Adult patients undergoing radiological examinations with contrast media.
- Evaluation of effectiveness of prophylactic measures to prevent hypersensitivity reactions after contrast administration.
- Reports predefined outcome measure: hypersensitivity reactions.
- No reports of case series or exploratory findings ( $n \geq 10$ ).

Based on title and abstract a total of twenty-three studies were selected. After examination of full text, a total of fifteen studies were excluded and eight studies were included in the literature summary. Reason for exclusion is reported in Table of excluded studies in the Appendices to modules.

The most important study characteristics and results were included in the evidence tables. The evidence tables and assessment of individual study quality are included.

### **Summary of literature**

#### Description of studies – Iodine-based contrast media

Cha (2019) described a multicentre registry study aiming to identify the prevalence, patterns, risk factors, and preventive measures for ICM-related HSRs. Between March 2017 and October 2017, a total of 196 081 patients who underwent contrast-enhanced CT examinations using ICM were enrolled from seven participating institutions. Regimens for premedication were as follows: for patients who reported a mild index reaction, 4 mg of intravenous chlorpheniramine 30 minutes before ICM administration; for patients who reported a moderate index reaction, 40 mg of intravenous methylprednisolone and 4 mg of intravenous chlorpheniramine 1 hour before ICM administration; and for patients who reported a severe index reaction, 40 mg of intravenous methylprednisolone 4 hours and 1 hour before ICM administration and 4 mg of intravenous chlorpheniramine 1 hour before ICM administration via the intravenous cannula inserted for ICM injection.

Mervak (2017) described a retrospective cohort study aiming to determine if the allergic-like breakthrough reaction rate of intravenous corticosteroid prophylaxis administered 5 hours before contrast material–enhanced CT is noninferior to that of a traditional 13-hour oral regimen. All subjects were premedicated for a prior allergic like or unknown-type reaction to iodine-based contrast material. A noninferiority margin of 4.0% was selected to allow for no more than a clinically negligible 6.0% breakthrough reaction rate in the cohort that received 5-hour intravenous corticosteroid prophylaxis. The breakthrough reaction rate for a cohort of 202 patients who received accelerated 5-hour IV corticosteroid prophylaxis before contrast material–enhanced CT for a prior allergic-like or unknown-type reaction to iodine-based contrast media was compared with a previously published breakthrough reaction rate from the same institution for a similar group of subjects who received a 13-hour oral premedication regimen for the same indication (2.1%; 13 of 626). Only allergic-like breakthrough reactions were considered for this study; physiologic reactions were ignored, because they are not considered relevant to corticosteroid prophylaxis.

Park (2017) described a retrospective cohort study aiming to evaluate the outcomes of re-exposure to low osmolar iodine-based contrast medium (LOCM) in patients with a history of moderate-to-severe hypersensitivity reaction (HSR) who underwent contrast-enhanced computed tomography after the initial HSR. Premedication was defined as antihistamines or systemic steroids prescribed with the aim of preventing recurrence of HSR. The premedication regimens used at the time of re-exposure were determined according to the decision of the physicians in charge. Steroids and antihistamines were administered 0.5–1 hour before re-exposure to LOCM.

Park (2018) described a retrospective cohort aiming to evaluate premedication protocols involving administration of antihistamines and multidose corticosteroids that have been widely used in prevention of recurrent HSRs to ICM. The outcomes of patients with mild HSR who subsequently underwent contrast material–enhanced CT between January 2012 and December 2015 were analysed. For premedication, 4 mg of chlorpheniramine was intravenously administered 30 minutes prior to re-exposure to ICM For patients with a mild index reaction. The initial HSR event was defined as the first occurrence of an immediate HSR to ICM. Recurrent HSR events were defined as an immediate HSR at repeated exposure to ICM after the initial event.

Specjalski (2020) described a prospective observational study aiming to determine efficacy of premedication before medical procedures with the use of iodine-based contrast media in patients with a history suggesting a hypersensitivity reaction after their past use. Out of 152 patients consulted due to adverse reactions after ICM (85 women and 67 men, aged 43–90), 101 were selected with a history suggesting a mild hypersensitivity reaction (urticaria, itching, skin redness, malaise etc.). All patients had an indication for ICM administration in the near future. Premedication was given with cetirizine (10 mg) and prednisone (20 mg or 50 mg, randomly assigned) 13, 7 and 1 h before the ICM administration. Patients with a history of a severe drug hypersensitivity reaction, including anaphylaxis, unstable asthma, renal insufficiency, or unstable heart insufficiency were excluded from the study. They also excluded patients with isolated subjective vasomotor symptoms (nausea, sweating, feeling of warmth etc.). Patients were randomly assigned to one of the premedication arms: 10 mg cetirizine + 20 mg prednisone or 10 mg cetirizine + 50 mg prednisone. The premedication was given orally 13, 7 and 1 h before the ICM administration. Subjects were observed 24 h after the ICM administration.

One systematic review (Tramer, 2006) included 9 RCTs in this analysis. The goal of this review was to review the efficacy of pharmacological prevention of serious reactions to iodine-based contrast media. A systematic search was performed up to October 2005. The pre-specified inclusion criteria were random allocation of patients, use of premedication alone or in combination, presence of a placebo or a no treatment control group, and reporting of presence or absence of allergic reactions. A total of 9 trials with 10,011 adult patients were included in the review analysis. No RCTs that answered the search questions were found that were published after this systematic review.

#### Description of studies – Gadolinium-based contrast agents

Bhatti (2018) described a retrospective cohort study aiming to determine the severity of breakthrough reactions to gadobenate dimeglumine in patients premedicated with a 13-hour premedication regimen. The final study population consisted of 19 breakthrough reactions to gadobenate dimeglumine in 19 subjects (18 female, 1 male) with a mean age of 51 years (range, 28-90 years) and a mean administered volume of gadobenate dimeglumine of 17 mL (range, 9-30 mL). Hypersensitivity reactions to gadobenate that were not preceded by premedication (n = 97) were explored as a comparator group. All premedication regimens were 13 hours in length, consisting of 150 mg oral prednisone (50mg 13, 7, and 1 hour before contrast material) and 50 mg oral diphenhydramine (1 hour before contrast material).

Ryoo (2019) described a retrospective cohort study aiming to evaluate the effectiveness of changing the contrast agent and single-dose premedication for HSR recurrence prevention in patients with a history of mild immediate HSR to GBCA who subsequently underwent enhanced magnetic resonance imaging. Intravenous chlorpheniramine 4 mg, 30 minutes before the GBCA administration, or intravenous methylprednisolone sodium succinate 40 mg plus chlorpheniramine 4 mg, 1 hour before the GBCA administration, was administered as premedication regimen. Recurrence rates of immediate HSR were compared according to prevention strategies. The GBCA that was used at the initial HSR event was defined as the culprit agent. An immediate HSR event at re-exposure to a GBCA after the initial HSR was defined as recurrent HSR.

Walker (2021) described a prospective observational efficacy trial aiming to evaluate HSR rate to GBCA among patients with history of HSR to GBCA, empirically given an alternative GBCA prior to repeat administration. Patients with prior HSR to GBCA received 13-hour oral corticosteroid and diphenhydramine premedication prescription with switching of GBCA to gadoterate.

#### Results – Iodine-based contrast media

Cha (2019) studied 196081 patients (mean age 59.1 ±16.0 years; 53% men) who underwent ICM administration. The overall prevalence of HSRs was 0.73% (1433 of 196081), and severe reactions occurred in 0.01% (17 of 196081). Among the 196081 patients, 570 patients reported experiencing an HSR to ICM in the past, and 94.9% (541 of 570) patients underwent preventive measures before ICM administration.

Premedication only was conducted in 213 patients (37.4%, 213 of 570; 187 patients received antihistamine only and 26 patients received antihistamine with corticosteroids) and change of ICM only was performed in 52 patients (9.1%, 52 of 570). In 276 patients (48.4%, 276 of 570), both premedication and change of ICM were performed (203 received antihistamine with change of ICM and 73 received antihistamine and corticosteroids with change of ICM).

Among 570 patients who had experienced an HSR to ICM in the past, 195 patients experienced recurrent HSR, whereas 375 patients did not show any symptoms of recurrence. A total of 176 of 541 patients (32.5%) experienced recurrent HSR despite premedication and/or change of ICM. Of those 176 patients, 158 patients received pretreatment (n= 131 antihistamines only, n= 27 antihistamines plus corticosteroids) and their reactions were thus considered breakthrough reactions. In addition, recurrent events occurred in 92 of 328 (28.1%) patients for whom culprit agents were changed. Logistic regression analysis showed that use of premedication with antihistamine (OR, 0.5; P = .01) and change in the generic profile of ICM (OR, 0.5; P < 0.001) were preventive against recurrent HSR.

Mervak (2017) showed that significantly more subjects receiving a 13-hour oral regimen had a prior reaction to iodine-based contrast material of unknown type (38% vs 15%, P= .0001), and significantly more subjects who received an accelerated IV regimen had a prior mild reaction to iodine-based contrast material (51% vs 34%, P=.0001). The breakthrough reaction rate for 5-hour intravenous prophylaxis was 2.5% (five of 202 patients; 95% CI: 0.8%, 5.7%), which was noninferior to the 2.1% (13 of 626 patients; 95% CI: 1.1%, 3.5%) rate for the 13-hour regimen (P =.018). The upper limits of the confidence interval for the difference between the two rates was 3.7% (0.4%; 95% CI: 21.6%, 3.7%), which was within the 4.0% noninferiority margin. All breakthrough reactions were of equal or lesser severity to those of the index reactions (two severe, one moderate, and one mild reaction).

Park (2017) included 150 patients from the 11 included centres. The proportion of males was 49.3% and the mean age was 61.7 ± 11.5 years. Among a total of 328 cases of re-exposure, the ICM was changed in 59.1% and systemic steroids were administered as premedication in 37.2% of cases at the time of re-exposure. Among 180 re-exposures without steroid premedication following moderate initial HSR, changing the ICM significantly reduced the recurrence rate of HSR (22.5% vs. 11.0%; P = 0.037). Among 92 re-exposures premedicated with systemic steroids following moderate initial HSR, the recurrence rate of HSR did not significantly differ (30.6% vs. 16.1% with the same vs. different ICM; P = 0.100). Among 23 re-exposures without steroid premedication following severe initial HSR, the recurrence rate was similar irrespective of whether the same ICM was used or not (33.3% vs. 23.5%; P = 0.632). On the other hand, among 26 cases premedicated with systemic steroids following a severe initial HSR, the recurrence rate was only 9.5% (2/21) when a different ICM was used, whereas four out of five cases (80.0%) using the same ICM experienced recurrence (P = 0.005). Steroid premedication did not result in improvement of the overall outcomes at the subsequent re-exposure (16.5% vs. 23.0%, P = 0.250). Next, the subjects premedicated with systemic steroids into two groups were divided according to the dose of steroids. The recurrence rate of HSR was not statistically different between subjects premedicated with a steroid equivalent to < 40 mg (19.7%; 13/66) or ≥40 mg of prednisolone (26.8%; 15/56) (P = 0.353) The risk of recurrent HSR was 67.1% lower in cases where the implicated ICM was changed to another one (OR: 0.329; P = 0.001). However, steroid premedication did not show protective effects against recurrent HSR.

Park (2018), report a total of 1178 patients (men 47.5%, 55.8 ±11.2 years) with mild immediate HSR were re-exposed to ICM 3533 times. Among these patients, 1056 patients (89.6%) experienced allergy-like reactions and 122 patients (10.4%) developed gastrointestinal reactions. Premedication with an antihistamine had a significant recurrence-lowering effect; the recurrence rate was 16.6% in non-premedicated patients, but decreased to 10.7% when antihistamine premedication was administered (OR, 0.569; 95% CI: 0.443, 0.731; P=.001) Regardless of whether contrast media was replaced or not, administration of antihistamine premedication lowered the recurrence rate significantly (with the same

contrast media: OR, 0.627; 95% CI: 0.430, 0.912; P = .015; with different contrast media: OR, 0.584; 95% CI: 0.4240, 0.776; P=.001) With re-exposure to the culprit agent without premedication, the recurrence rate was 31.1% (85 of 273 examinations). The recurrence rate decreased to 12% (105 of 872 examinations; P=.001) by only changing the culprit agent and to 7.6% (148 of 1947 examinations; P=.001) by using the combination of changing the ICM and antihistamine premedication. Changing the ICM plus antihistamine premedication was also helpful in reducing the recurrence of gastrointestinal symptoms from 16.1% to 1.8% (P=.020). However, despite changing of the ICM, some combinations of ICM did not show a prophylactic effect.

In Specjalski (2020), 76 patients underwent the radiologic procedure with premedication with antihistamine and a lower (40 patients; 3x 20mg) or higher dose (36 patients; 3x 50mg) of prednisone. Four of them (5%) reported a cutaneous hypersensitivity reaction (urticaria, itching, redness) and one dyspnoea. There was no statistically significant difference in relation to the premedication protocol (p = 0.1306).

Tramer (2006) reported 9 trials (including 10,011 adults) tested H1 antihistamines, corticosteroids, and an H1 +H2 blocker combination. No trial included exclusively patients with a history of allergic reactions. Many outcomes were not allergy related, and only a few were potentially life threatening. No reports on death, cardiopulmonary resuscitation, irreversible neurological deficit, or prolonged hospital stays were found. In two trials, 3/778 (0.4%) patients who received oral methylprednisolone 2x32 mg or intravenous prednisolone 250 mg had laryngeal oedema compared with 11/769 (1.4%) controls (odds ratio 0.31, 95% confidence interval 0.11 to 0.88). In two trials, 7/3093 (0.2%) patients who received oral methylprednisolone 2x32 mg had a composite outcome (including shock, bronchospasm, and laryngospasm) compared with 20/2178 (0.9%) controls (odds ratio 0.28, 0.13 to 0.60). In one trial, 1/196 (0.5%) patient who received intravenous clemastine 0.03 mg/kg and cimetidine 2 to 5 mg/kg had angio-oedema compared with 8/194 (4.1%) controls (odds ratio 0.20, 0.05 to 0.76).

### Results – Gadolinium-based contrast agents

Bhatti (2018) showed that premedication was most commonly given (63% [12/19]) for a previous hypersensitivity reaction to gadolinium-based contrast media (GBCM); in 37%(7/19), it was given for a different risk factor. In those premedicated for a previous allergic-like reaction to GBCM of known severity (n = 9), the breakthrough reaction severity was the same as index reaction severity in 56% (5/9), less severe in 11% (1/9), and of greater severity in 33% (3/9). Two severe breakthrough reactions occurred; both were in subjects premedicated for risk factors other than a previous GBCM reaction. No subjects died. Five subjects were re-exposed to GBCM a total of 9 times; no repeat breakthrough reactions occurred.

Ryoo (2019) studied a total of 185 patients with a history of mild immediate HSR to GBCA who were re-exposed to GBCA 397 times during the study period. The overall recurrence rate was 19.6% (78/397). Changing the culprit GBCA significantly reduced the recurrence rate, compared with reusing the culprit GBCA (6.9%, 9/130 and 25.8%, 69/267; P < 0.001). The recurrence rate was lowest when the GBCA was changed to a different molecular structure class from the culprit agent, followed by changing to CM with the same molecular structure and reusing the culprit GBCA (6.2%, 7/113 vs 11.8%, 2/17 vs 25.8%, 69/267; P < 0.001). Single-dose premedication demonstrated no significant prophylactic effect on recurrence (20.4%, 17/98 vs 17.3%, 61/299 with and without premedication, respectively; P

= 0.509). The recurrence rate of cases with antihistamine administration was 19.9%, and the recurrence rate of cases with systemic steroid plus antihistamine administration was 25.9%. Both premedication protocols did not show a recurrence-lowering effect, compared with the non-premedicated cases (antihistamine administration [OR, 1.180; 95% CI, 0.647–2.154; P = 0.589] and systemic steroid plus antihistamine [OR, 1.668; 95% CI, 0.609–4.565; P = 0.316]). Premedication in addition to changing CM also showed no additional prophylactic effect (7.2%, 7/97 and 6.1%, 2/33, respectively; P = 0.821).

Walker (2021) evaluated 26 patients with mild (92.3% [24/26]) or moderate (7.7% [2/26]) HRS to gadobutrol (53.8% [14/26]), gadoxetate (3.8% [1/26]), and gadopentetate (3.8% [1/26]). In 38.5% (10/26), inciting GBCA was unknown but was likely gadobutrol or gadopentetate based on availability. Most patients were female (84.6% [22/26]). The mean patient age was 52.1 ± 15.8 years. From 27 gadoterate administrations, 59.3% (16/27) patients received corticosteroid and diphenhydramine premedication, 11.1% (3/27) received only diphenhydramine, and 29.6% (8/27) with no premedication. Among the 26 included patients, 2 patients, both female, with a history of immediate HR to gadobutrol had a breakthrough HR to gadobutrol despite adequately dosed corticosteroid premedication. Hypersensitivity reaction rate after empiric switching to gadoterate was 3.7% (1 mild reaction; 95% CI, 0.09%–18.9%) overall with no difference in patients with (6.3% [1/16]; 95% CI, 0.15%–28.7%) or without (0%; [0/11] upper bound 95% CI, 25.0%) corticosteroid premedication.

#### Summary of study's conclusions – Iodine-based contrast media

Use of premedication with antihistamine (OR, 0.5; P = .01) was preventive against recurrent HSR (Cha, 2019).

A change in the culprit ICM and premedication with antihistamine are useful for reducing the recurrence of HSRs (Cha, 2019).

Accelerated intravenous premedication with corticosteroids beginning 5 hours before contrast-enhanced CT has a breakthrough reaction rate noninferior to that of a 13-hour oral premedication regimen (Mervak, 2017).

In patients with moderate-to-severe HSR, steroid premedication only shows limited effectiveness. Steroid premedication did not result in improvement of the overall outcomes at the subsequent re-exposure (16.5% vs. 23.0%, P = 0.250). Steroid premedication did not show protective effects against recurrent HSR (Park, 2017).

Premedication with an antihistamine had a significant recurrence-lowering effect (OR, 0.569; 95% CI: 0.443, 0.731; P=.001) in mild HSR (Park, 2018).

Premedication with cetirizine and prednisone before radiologic procedures, regardless of dosage of the corticosteroid, proved to be efficient in patients with a history suggesting hypersensitivity to iodine-based contrast media (Specjalski, 2020).

#### Summary of study's conclusions – Gadolinium-based contrast agents

Premedication with antihistamine and corticosteroid does not eliminate moderate or severe reactions to gadobenate dimeglumine and recurrent reactions can be of greater severity than index reactions (Bhatti, 2018).

Both premedication protocols (antihistamine, systemic steroid plus antihistamine) did not show a recurrence-lowering effect, compared with the non-premedicated cases (antihistamine administration [OR, 1.180; 95% CI, 0.647–2.154; P = 0.589] and systemic steroid plus antihistamine [OR, 1.668; 95% CI, 0.609–4.565; P = 0.316]) (Ryoo, 2019).

Empirically switching GBCAs, with or without the use of corticosteroid premedication, can substantially reduce the rate of hypersensitivity breakthrough reactions (Walker, 2021).

Level of evidence of the literature

The quality of certainty of evidence for the outcome allergic / hypersensitivity reaction was downgraded from low to very low due to risk of bias (as described below), heterogeneity of included studies, indirectness, and imprecision of outcome measures (low numbers of events).

The risk of bias of the included studies was deemed high due to high risk of bias in selection of participants, selection of the outcome of interest and Confounding analysis.

**Conclusions**

<b>Very low GRADE</b>	<p>The evidence is very uncertain about the effect of premedication on hypersensitivity reactions to contrast media when compared with no premedication or a different premedication strategy in patients undergoing examinations with iodine-based contrast media.</p> <p><i>Cha, 2019; Mervak, 2017; Park, 2017; Park, 2018; Specjalski, 2020; Tramer, 2006</i></p>
-----------------------	---

<b>Very low GRADE</b>	<p>The evidence is very uncertain about the effect of premedication on hypersensitivity reactions to contrast when compared with no premedication or a different premedication strategy in patients undergoing examinations with gadolinium-based contrast agents.</p> <p><i>Bhatti, 2018; Ryoo, 2019; Walker, 2021</i></p>
-----------------------	---

**Justifications – evidence to decision**

Primarily, in patients with a (documented) history of a hypersensitivity reaction to a contrast medium, an alternative imaging modality should be considered. The more severe the reaction, the stronger omitting a contrast medium should be considered. For mild reactions in which alternative imaging modalities are of substantially inferior quality, the risk – benefit ratio may shift. In many cases, CT with iodine-based contrast media can be replaced by ultrasound, with or without contrast agents, or MRI, with or without contrast agents. When this is not possible, consider performing the examination without a contrast medium, but only if this has an acceptable degree of diagnostic quality. For this, close communication with the referring specialist is mandatory.

*Use of premedication*

In premedication, two types of drugs are used: H1-antihistamines and corticosteroids. Often, they are used concomitantly, making their individual effect difficult to assess, particularly since there are many variations in premedication schedules. H1-antihistamine monotherapy

is not common practice in Europe and the US, but has been used successfully in milder HSRs, particularly by Korean research groups.

H1-antihistamines block histamine receptors on various effector cells, blocking the effect of one of the pivotal players in direct mast cell responses. However, mast cells and basophils secrete various other substances that are not blocked by these drugs. The main side effect of the older H1-antihistamines that are available for intravenous administration is drowsiness/sedation. For the newer nonsedating antihistamines this effect is usually mild, but these are mainly available for oral administration.

Corticosteroids have various effect on the immune system, including mast cells, and therefore can block both mast cell degranulation by upregulating inhibitory signalling receptors, and inhibit cytokine production through suppression of gene transcription. (Andrade, 2004; Park, 2009) These membrane stabilizing effects require that administration is started >6h before contrast media administration. Unfortunately, this comes with a less favourable side effect profile, particularly with higher doses and repeated exposure.

The old protocols for premedication shown below (Greenberger, 1981; Greenberger, 1986; Lasser, 1994) are still in widespread use. The Greenberger protocol is popular in the USA, while the Lasser protocol is more frequently used in Europe. There is no literature to establish an optimal indication or protocol. Recently, the Greenberger protocol has been modified into shorter options with intravenous administration for inpatients (Mervak, 2017).

Greenberger protocol (elective examinations 1981, 1984):

- Prednisolone 50 mg IV - 13h, 7h and 1h before the procedure.
- Diphenhydramine 50 mg IV - 1h before the procedure.

Greenberger protocol (emergency examinations 1986):

- Hydrocortisone 200 mg IV - immediately and every 4h until procedure is finished
- Diphenhydramine 50 mg IV - 1h before the procedure

Lasser protocol (elective examinations 1994):

- Methylprednisolone 32 mg IV - 12h and 2h before the procedure.

The evidence regarding the effectivity of corticosteroids and antihistamines for pharmacological prevention is very heterogeneous and of low quality; moreover, it stems from the time of use of high osmolar, ionic ICM (Delaney 2006; Tramer, 2006; Davenport, 2017). It seems that prophylactic premedication can prevent the number of hypersensitivity reactions after contrast administration, but premedication mainly reduces the number of mild reactions and therefore the total number of reactions (Lasser, 1994), and not the number of severe reactions (Jung, 2016). It has been shown that premedication can cause brief hyperglycaemia (Davenport, 2010), but may also be associated with longer hospital stay, increased costs, and worse clinical outcomes (Davenport, 2016).

Few studies have focused on H1-antihistamine monotherapy, and these are biased to patients with mild reactions (Lee, 2016; Park, 2018). In a large Korean multicentre study logistic regression analysis showed that changing the ICM (odds ratio 0.51; 95% CI: 0.36, 0.73) and premedication with H1-antihistamines (odds ratio 0.53; 95% CI: 0.33, 0.86) were protective against recurrent reactions (Cha, 2019).

Many studies report a use of antihistamine and corticosteroid combination premedication; often these regimens are stratified according to the severity of the previous HSR (antihistamines only in mild HSR; antihistamines + corticosteroids in moderate to severe



HSR) (Lee, 2016; Park 2017; Park, 2018) or adapted based to the clinical preference. Corticosteroid monotherapy has rarely been used in older studies (from the high osmolar, ionic ICM era) and their findings cannot reasonably be extrapolated to the current low osmolar, nonionic contrast media (Lasser, 1994) To our knowledge, there are no studies available in which prescription of premedication has been randomized. The currently discussed studies show no additional beneficial effect of corticosteroid premedication in preventing a recurrent HSR. (Park, 2018; Cha, 2019)

Not surprisingly, the Joint Task Force on Practice Parameters of the American Academy of Allergy, Asthma, and Immunology and the American College of Allergy, Asthma, and Immunology concluded in 2020 that “Evidence is lacking to support the role of glucocorticoid routine premedication in patients receiving low-osmolar or iso-osmolar ICMs to prevent recurrent radiocontrast media anaphylaxis” (Shaker, 2020)

In a recent study by McDonald (2021), published after our literature search, 1,973 high-risk patients with a history of HSR were retrospectively studied. Prophylactic measures consisted of changing the ICM and/or steroid premedication, with or without antihistamines. Only patients with a complete steroid premedication protocol (i.e., 2 doses of 32mg of methylprednisolone at 12 and 2 hours before) CT were include in the steroid group; patients with an incomplete protocol were put in the ‘not-steroid-premedicated’ group. In 4,360 examinations, 280 HSR occurred in 224 patients (11%), of which 19 (7%) were more severe than the previous HSR. Patients who received a different ICM with or without steroid premedication had a significantly lower rate of recurrent HSR than those who received the same ICM with steroid premedication (same ICM and steroid premedication: 80 of 423 examinations [19%]; different ICM and no steroid premedication: 10 of 322 examinations [3%]; odds ratio [OR], 0.14 [95% CI: 0.06, 0.33]; P, .001; different ICM and steroid premedication: five of 166 patients [3%]; OR, 0.12 [95% CI: 0.04, 0.36]; P < .001). A sub analysis of the first CT scans only revealed that patients who received the same ICM had a similar risk of recurrent HSR, regardless of whether they received steroid premedication. (Steroid premedication: 44 of 172 patients [26%] vs. no premedication: 73 of 298 patients [25%]; OR, 1.00 [95% CI: 0.64, 1.57]; P = .99).

Although there is less data on the effectivity of premedication in GBCA, the few studies available show comparable results. Premedication with antihistamines and corticosteroid did not eliminate moderate or severe reactions to gadobenate dimeglumine. (Bhatti, 2018). Both premedication protocols employed by Ryoo (2019) (antihistamine, systemic steroid plus antihistamine) did not show a recurrence-lowering effect, compared with the non-premedicated cases (antihistamine administration [OR, 1.180; 95% CI, 0.647–2.154; P = 0.589] and systemic steroid plus antihistamine [OR, 1.668; 95% CI, 0.609–4.565; P = 0.316]).

Finally, there is a paucity of data on the benefits of premedication for non-severe nonimmediate hypersensitivity reactions. Most of these reactions are self-limiting or can be treated symptomatically. In the very recent large Korean analysis, changing the type of GBCA and premedication were preventive, but premedication was only preventive in nonimmediate reactions (Ahn YH, 2022). Major international guidelines suggest performing allergologic skin testing, but do not recommend the use of premedication for non-severe nonimmediate reactions (ACR, 2022; ESUR, 2018; Torres, 2021).

#### Changing of a specific contrast medium

In recent years, changing the culprit ICM has become a frequently employed prophylactic strategy that is used as an alternative or a complementary measure to premedication, the latter particularly if the change has been made empirically without performing skin tests.

A large comparative study with 771 patients showed that changing the CM was more effective than premedication in the prevention of adverse reactions (Abe, 2016). Similar results were achieved in patient cohorts with mild or moderate-severe HSR where changing the contrast medium led to fewer recurrent HSR (Park, 2017; Park, 2018).

A large retrospective study on 1,963 patients showed that changing the culprit ICM only led to significantly lower rates of recurrent HSR, odds ratio of 0.14 [95% CI: 0.06, 0.33]. Additional, corticosteroid premedication did not offer additional protection, odds ratio of 0.12 [95% CI: 0.04, 0.36] (McDonald, 2021). In severe HSR, skin testing is useful to provide a safe alternative ICM (Ahn, 2022; Sohn, 2021).

In a very recent meta-analysis (Umakoshi, 2022), published after our literature search, six retrospective observational studies at moderate to severe risk of bias assessed 4,329 patients in the ICM-change-group and 2,826 in the no-change group. Changing ICM was associated with a reduced risk of recurrent hypersensitivity reaction by 61% (risk ratio = 0.39; 95% credible interval [CrI]: 0.24, 0.58). Adverse events associated with ICM-change were not reported. It was concluded that in observational evidence of limited quality, ICM-change was associated with a reduced risk of recurrent immediate hypersensitivity reaction in patients with a prior ICM-induced hypersensitivity reaction.

In MRI, the experience of changing the culprit GBCA is more limited. In patients with mild immediate HSR, changing the contrast agent could reduce the recurrence rate (Ryoo, 2019). In a small study with mild to moderate HSR to a variety of linear and macrocyclic GBCA, empiric switching to gadoterate reduced the rate of recurrent HSR, independent of premedication with either corticosteroids and H1-antihistamines or corticosteroids only (Walker, 2021).

These findings are in line with the pathogenetic concept that the allergic reactions are not directed against a ubiquitous part of all ICM or GBCA (i.e., not against iodide), but are directed against a specific allergen that is unique to one or more contrast media; switching to a contrast medium that does not contain this epitope will prevent a recurrent allergic reaction. Unfortunately, the exact allergens/epitopes have not been identified and since contrast media are structurally related, the allergen may be present in other contrast media as well, leading to cross-reactivity for those specific agents. As a result, empiric switching of contrast media does not fully prevent a recurrent HSR. For ICM, the presence of the N-(2,3 dihydroxypropyl)-carbamoyl side chain may play a role in the HSR; after a HSR to an ICM containing this side chain, it is advised to switch to an ICM lacking this side chain (iobitridol, iopamidol), preferably supported by a negative skin test (Lerondeau, 2016).

#### *Evidence to decision*

There is no evidence that premedication reduces the risk of life-threatening anaphylactic reactions. The evidence for its role in less severe (moderate to mild) HSR remains weak and conflicting. Therefore, the GDG has decided to not advice premedication in patients with an history of immediate HSR to CM.

Corticosteroids do not appear to prevent immediate HSR to GBCA. Contrary, corticosteroids have significant side effects, particularly with cumulative use and in susceptible patients.

Antihistamines reduce the recurrence risk in milder reactions, but it remains uncertain if they also reduce the risk or ameliorate symptoms in moderate to severe reactions, as they are usually given in combination with steroids. Also, antihistamines have side effects, especially sedating side effects can occur (e.g., preventing driving a car). Changing the culprit CM as sole or complementary prophylactic measure significantly lowered the HSR recurrence rate for both ICM and GBCA.

Preferably the CM change is based on negative skin tests; if these are not available, an empiric but educated change should be performed, in which the currently known risks for cross-reactivity are considered (Table 7.4.1-7.4.2). In case of an unknown previous culprit CM a testing dose of 10% of the alternative CM can be considered, especially in case of a previous severe reaction.

#### Breakthrough hypersensitivity reactions to contrast media

It's becoming increasingly clear that premedication is far from perfect. In premedicated patients so-called "breakthrough" hypersensitivity reactions can occur despite premedication. These are usually of similar severity as the original culprit reaction and are seldom severe (Davenport, 2017; Mervak 2015), but occasionally are of greater severity than the index reaction (Bhatti, 2018).

#### *Iodine-based contrast media*

A large study of antihistamine premedication in patients with mild HSR showed no benefit of premedication with a breakthrough reaction frequency of 11%, identical to using no premedication (Lee, 2016).

In a study using a stratified premedication protocol, the frequency of breakthrough reactions was 17%. Most of these reactions (89%) were mild and required no treatment. In severe HSR underdosage of premedication led to a significant increase in breakthrough reactions (Lee, 2017).

Kim (2018) studied the effect of the administration route on breakthrough reactions. Re-exposure to intravascular CM yielded a breakthrough frequency of 19,5%. The number of reactions after extravascular CM was negligible.

#### *Gadolinium-based contrast agents*

Walker (2019) showed a high rate (35%) of breakthrough reactions in patients with HSR to gadobutrol. Both culprit and breakthrough HSR were usually mild but may escalate in severity. This rate is very similar to the rate in a previous large prospective study on HSR after gadobutrol (Power, 2016).

In a meta-analysis of breakthrough reactions, a similar 39% rate of breakthrough HSR was found. The frequency was similar between macrocyclic and protein-binding linear GBCA (Walker, 2020).

#### *Evidence to decision*

The frequency of breakthrough reactions varies on the severity of the culprit reaction and the specific premedication protocol. Rates after ICM vary between 2-20%, but rates after GBCA administration are higher, in the order of 35-40%. Most of the reactions are of similar severity as the culprit reaction, but incidental escalation in severity may be found.

Cross-reactivity between specific contrast media (see also [Introduction](#) to chapter 7)

In most studies on contrast media hypersensitivity, the term cross-reactivity is used when patients have a HSR to two or more different contrast media, or if there are positive skin tests for two or more contrast media. In the latter case, it is not always entirely certain whether the skin test positivity is clinically relevant, as a drug provocation test is generally not performed. It has recently been suggested to discriminate polyvalent reactivity from cross-reactivity. Polyvalent reactivity comprises patients that have positive skin tests to multiple contrast media. It is argued that the term cross-reactivity should be reserved for polyvalent reactivity within a defined chemical group (e.g., with a N-(2,3 dihydroxypropyl)-carbamoyl side chain), and that multiple positive reactions against non-group CM should be defined as individual reactivity that is probably more prominent between contrast media (Schmid, 2021). However, this is a much stricter definition than has been used in most studies and for clarity we here stick to the broader definition of cross-reactivity.

#### *Iodine -based contrast media*

Schrijvers (2018) found most cross-reactivity between agents with a N-(2,3 dihydroxypropyl)-carbamoyl side chain. For immediate HSR, iomeprol and iopromide showed the highest test positivity (41%), while for nonimmediate HSR this was between ioversol and iomeprol (55%) (Table 7.4.1 and 7.4.2).

Sohn (2021) showed in 250 patients with positive skin tests, polyvalent reactivity to at least 2 different ICM in 157 patients. The highest frequency was between iomeprol and iohexol (36%). The frequency was higher in pairs with common N-(2,3 dihydroxypropyl)-carbamoyl side chains than between CM with non-common side chains. This was significant for severe immediate HSR.

In contrast, Gamboa (2021) found in IgE-mediated allergic reactions that cross-reactivity of iomeprol with iopamidol, iopromide, and iobitridol was low. In their study, iopamidol was a valid alternative in patients with IgE-mediated allergy to iomeprol and negative skin tests to iopamidol. The culprit ICM itself can be administered safely in patients having experienced nonallergic immediate hypersensitivity.

In the CIRTACI study on immediate HSR it was also shown that cross-reactivity was predominantly present in allergic immediate reactions, but seldom in nonallergic immediate HSR (Clement, 2018).

In 43 patients with skin tests for nonimmediate HSR, Gaudin (2019) showed a high rate of cross-reactivity between ICM, that followed the Lerondeau classification (Lerondeau, 2016). Iobitridol was a well-tolerated alternative ICM in 77% of patients. Very similar findings have been found in a 19/142 patients with non-immediate HSR and positive intradermal tests (Gracia Bara, 2019).

In an older meta-analysis of 21 studies on skin testing, extensive data are presented on the frequency of cross-reactivity in immediate and nonimmediate reactions (Yoon, 2015). The percentage of cross-reactivity is in general lower than the percentages found in other

studies (Schrijvers, 2018; Sohn, 2021). This may be related to the inclusion of older studies with a lower overall positive yield of the skin test.

**Table 7.4.1. Cross-reactivity rates between pairs of ICM in skin positive patients with immediate hypersensitivity reactions to iodine-based contrast media**

ICM Name	<i>lobitridol</i>	<i>lopamidol</i>	<i>lopromide</i>	<i>lohexol</i>	<i>lomeprol</i>	<i>loversol</i>	<i>lodixanol</i>
<i>lobitridol</i>	X						
<i>lopamidol</i>	11.8% [5.5-18]	X					
<i>lopromide</i>	22.1% [22-22.2]	25.6% [11.1-40]	X				
<i>lohexol</i>	20.8% [16.6-25]	25.1% [11.1-39]	43.5% [38.9-48]	X			
<i>lomeprol</i>	17.6% [13-22.2]	33.2% [33-33.3]	38.7% [33-44.4]	40.2% [36-44.4]	X		
<i>loversol</i>	20.6% [19-22.2]	35.6% [22.2-49]	37.7% [33.3-42]	50.0% [38.9-61]	53.3% [51-55.5]	X	
<i>lodixanol</i>	19.3% [16.6-22]	36.6% [22.2-51]	45.5% [38.9-52]	51.7% [44.4-59]	45.5% [41-50]	51.5% [38.9-64]	X

Average percentages and [range] of findings by Yoon 2015, Schrijvers 2018 and Sohn 2021. ICM containing the common *N*-(2,3-dihydroxypropyl) carbamoyl side chain is grouped within the black line. Risk of cross-reactivity is marked as very low (dark green, <10%), low (green, 10-20%), medium (orange 20-30%), high (red, 30-50%) and very high (dark red, >50%).

**Figure 7.4.2. Cross-reactivity rates between pairs of ICM in skin positive patients with immediate hypersensitivity reactions to iodine-based contrast media**

ICM Name	<i>lobitridol</i>	<i>lopamidol</i>	<i>lopromide</i>	<i>lohexol</i>	<i>lomeprol</i>	<i>loversol</i>	<i>lodixanol</i>
<i>lobitridol</i>	X						
<i>lopamidol</i>	12.7% [5.9-22.1]	X					
<i>lopromide</i>	10% [5.9-12.1]	14.3% [11.7-19.1]	X				
<i>lohexol</i>	9.8% [5.9-16.4]	11% [8-14]	12.8% [5.9-23.6]	X			
<i>lomeprol</i>	10.8% [5.9-16.6]	10% [6-14]	27.9% [21-41.1]	22.2% [1-36.3]	X		

<i>Ioversol</i>	8.4% [6-10.8]	8% [5-10.9]	12.2% [4-20.4]	15.3% [7-23.5]	19.7% [8-29.4]	X	
<i>Iodixanol</i>	9.9% [7-12.8]	6.3% [5-7.6]	12.4% [9-16.6]	16% [10-20.4]	15.5% [11-17.8]	14.3% [5-20.4]	X

Average percentages [range] of findings by Yoon, 2015 and Schrijvers, 2018. ICM containing the common *N*-(2,3-dihydroxypropyl) carbamoyl side chain are grouped within the black lines. Risk of cross-reactivity is marked as very low (dark green, <10%), low (green, 10-20%), medium (orange 20-30%), high (red, 30-50%) and very high (dark red, >50%).

### *Gadolinium-based contrast agents*

The CIRTACI study showed that a high percentage of Ring-Mesmer type 3-4 reactions after contrast media administration were allergic. Cross-reactivity among GBCA was only shown in these allergic immediate HSR. The overall number of cross-reactivity reactions was higher for GBCA than for ICM, but the number of patients was low for GBCA (Clement, 2018).

In a 7-year retrospective analysis of patients with hypersensitivity to GBCA, 13,6% (18/132) had positive skin tests and were deemed allergic. Cross-reactivity occurred in 38% and was more frequent among the macrocyclic GBCA. Cross-reactivity between macrocyclic and linear GBCA also occurred (Mankouri, 2021).

In a small retrospective study, Grüber (2021) showed cross-reactivity among macrocyclic GBCA and between macrocyclic and linear GBCA, but not among linear GBCA.

In a small case-series of 5 patients with immediate HSR to gadobutrol, only cross-reactivity with gadoterate was demonstrated (Gallardo-Higueras, 2021).

### *Evidence to decision*

In ICM cross-reactivity is common in allergic immediate and even more in nonimmediate HSR. It occurs most frequently among ICM with a common *N*-(2,3 dihydroxypropyl)-carbamoyl side chain such as iopromide, iohexol, ioversol, iomeprol and iodixanol.

In GBCA cross-reactivity in allergic HSR is more common than with ICM and is especially prevalent among macrocyclic GBCA.

Serum tryptase evaluation and skin testing are key in diagnosing allergic vs. nonallergic HSR and skin tests can identify safe alternative contrast media for future diagnostic studies.

### Unknown severity of previous hypersensitivity reaction to contrast media

Unfortunately, there is a lack of data about the recurrence rate and severity of HSR to CM of patients in which there is no data about the severity of the initial HSR. Although in our daily practice this is a substantial part of the population, in studies these patients are not included. Therefore, we want to stress the importance of proper documentation (see below).

A practical guideline to assess the severity of the initial reaction can be adapted from the Hartwig's Severity Assessment Scale (Hartwig, 1992):

- Did the hypersensitivity reaction to contrast media caused permanent harm to the patient?
- Was the hypersensitivity reaction to contrast media reason for admission to the hospital or reason for increasing of hospital stay?
- Was the hypersensitivity reaction to contrast media treated with an adrenaline auto-injector (Epipen)?

The GDG advice to treat patients in line with a previous mild reaction if these questions are answered with ‘no’. In case one of these questions is answered with ‘yes’ patient should be treated as having a previous severe reaction.

### Documentation of hypersensitivity reactions to contrast media

With an increasing use of changing between specific contrast media and the use of skin testing for identifying possible safe alternatives to culprit contrast media causing hypersensitivity reactions, proper documentation in the electronic patient record (EPR) has become very important.

However, the practice is quite different. Documentation in the EPR is not well standardized, is often done by physicians without any experience in the administration of contrast media, and is therefore often insufficient and incomplete (Ananthakrishnan, 2021; Deng, 2019). Recommendations for standardization have recently been published (Böhm, 2020). In selected institutions semi-structured tools for documentation of adverse events have only just been developed and implemented (Lang, 2022).

We would like to re-iterate the recommendations from [Safe Use of Contrast Media, part 2](#): It is mandatory that the *physician responsible for the administration of the CM or (EPR only) the drug allergy specialist* accurately records the following:

- The place, date, and time of CM administration in the imaging report and in the electronic patient record.
- The specific contrast medium name and dose (volume, concentration) in the imaging report and in the electronic patient record.
- The type of hypersensitivity reaction, immediate or non-immediate, in the imaging report and in the electronic patient record.
- All patient symptoms and vital signs (blood pressure, pulse, respiration rate, oxygen saturation) in the imaging report and in the electronic patient record.
- The treatment given, and the response of the patient to the treatment in the imaging report and in the electronic patient record.
- Any clinical follow-up and advice on need for future premedication in the imaging report and in the electronic patient record.
- Any results of the consultation with a drug allergy specialist on future CM administration in the electronic patient record.

In addition:

- The presence of a documented allergic or nonallergic hypersensitivity reaction in the electronic patient record allergy registry (“allergie registratie”). It is essential that this reporting should be based on the name of the specific contrast medium and be done by *radiologists/cardiologists or drug allergy specialists* with experience in the use of contrast media.

- If the adverse reaction to a contrast medium is severe or unusual, the *physician responsible for the administration of the CM or the drug allergy specialist* should report all details of the reaction to the National Pharmacovigilance Authority (LAREB).

## Recommendations and flowcharts

In all patients with a (documented) history of a hypersensitivity reaction to an iodine-based contrast medium or a gadolinium-based contrast agent, consider an alternative imaging modality. When this is not possible, consider performing an unenhanced exam, but only if the reduction in diagnostic quality is acceptable.

\*See also [flow charts](#)

### I Patients with previous immediate (acute) hypersensitivity reactions to iodine-based contrast media or gadolinium-based contrast agents

In patients with a (documented) history of a **mild immediate** hypersensitivity reaction to an iodine-based contrast medium or a gadolinium-based contrast agent:

- Treat these patients as any other patient because of the low risk of developing a moderate or severe reaction

\*See also [flow charts](#)

In patients with a (documented) history of a **moderate or severe** hypersensitivity reaction to iodine-based contrast media or gadolinium-based contrast agents

- Postpone imaging and refer the patient to a drug allergy specialist

If there is no time to refer the patient to a drug allergy specialist:

- Choose a different iodine-based contrast medium or gadolinium-based contrast agent, if the culprit contrast medium is known\*
- Consider a test dose by first giving 10% of the total contrast dose and observing the patient for >15 minutes; particularly with severe reactions and/or unknown culprit
- Observe the patient  $\geq 30$  min with IV in place
- Be vigilant to react to a possible new hypersensitivity reaction

\*See also [flow charts](#)

### II Patients with a previous breakthrough reaction to contrast media

In patients with a breakthrough hypersensitivity reaction to iodine-based contrast media or gadolinium-based contrast agents, always refer to a drug allergy specialist for skin testing with a panel of different iodine-based contrast media or gadolinium-based contrast agents.

\*See also [flow charts](#)

### III Patients with previous hypersensitivity reactions to multiple contrast media



In patients with hypersensitivity reactions to multiple iodine-based or gadolinium-based contrast media (either two or more different iodine-based contrast media or gadolinium-based contrast agents or to an iodine-based contrast medium and a gadolinium-based contrast agent) apply the same as above, but always refer the patient to a drug allergy specialist.

\*See also [flow charts](#)

#### IV Patients with previous nonimmediate (delayed) hypersensitivity reactions to iodine-based contrast media or gadolinium-based contrast agents

- Do **not** give iodine-based contrast media or gadolinium-based contrast agents to a patient with a previous (suspected) severe nonimmediate skin eruption with danger signs\*\*
- Refer the patient immediately to a drug allergy specialist

\*See also [flow charts](#)

In patients with a history of a mild-moderate nonimmediate skin eruption without danger signs\*\*:

- Choose a different iodine-based contrast medium or gadolinium-based contrast agent if the culprit contrast medium is known\*
- Instruct the patient in case of a recurrent reaction to take pictures of the skin lesions and contact the radiology or cardiology department for feedback

\*See also [flow charts](#)

\* Consider cross-reactivity of contrast media (see Tables 7.4.1 and 7.4.2) and an increased risk for NIHR with use of iso-osmolar ICM.

\*\* Danger signs: erosive and/or haemorrhagic lesions, blistering and skin disruption, mucosal involvement, extracutaneous organ involvement (high fever, abnormal liver / kidney values, lymphadenopathy)

Assessment of severity of previous hypersensitivity reaction when information in patient file is lacking can be performed by asking patient the following questions:

- Did the hypersensitivity reaction to contrast media caused permanent harm to the patient?
- Was the hypersensitivity reaction to contrast media reason for admission to the hospital or reason for increasing of hospital stay?
- Was the hypersensitivity reaction to contrast media treated with an adrenaline auto-injector (Epipen)?

The GDG advice to treat patients in line with a previous mild reaction if these questions are answered with 'no'. In case one of these questions is answered with 'yes' patient should be treated as having a previous severe reaction.

\*See also [flow charts](#)

## V Cross-reactivity between contrast media

Cross-reactivity is most relevant in *allergic* hypersensitivity reactions.

It occurs with a higher frequency among:

- Iodine-based contrast media with a *N*-(2,3 hydroxypropyl)-carbamoyl side chain
- Macrocyclic gadolinium-based contrast agents

The drug allergy specialist determines through skin testing with a panel of different iodine-based contrast media and gadolinium-based contrast agents:

- The allergic nature of the hypersensitivity reaction
- Cross-reactivity between contrast media
- Suggestions of safe alternative contrast media

## VI Documentation of hypersensitivity reactions

The physician responsible for the administration of the contrast medium should accurately document the hypersensitivity reaction in the imaging report.

The physician responsible for the administration of the contrast medium or the drug allergy specialist should accurately document the hypersensitivity reaction in the electronic patient dossier.

It is essential that reporting should be based on the name of the *specific* contrast medium and be done by *physicians or drug allergy specialists* with experience in the use of contrast media.

After all hypersensitivity reactions to contrast media, the following should be registered:

- The place, date, and time of CM administration - in the imaging report and in the electronic patient record.
- The specific contrast medium name and dose (volume, concentration) - in the imaging report and in the electronic patient record.
- The type of hypersensitivity reaction, immediate or non-immediate - in the imaging report and in the electronic patient record.
- All patient symptoms and vital signs (blood pressure, pulse, respiration rate, oxygen saturation) - in the imaging report and in the electronic patient record.
- The treatment given, and the response of the patient to the treatment - in the imaging report and in the electronic patient record.
- Any clinical follow-up and advice on need for future premedication - in the imaging report and in the electronic patient record.

- Any results of the consultation with a drug allergy specialist on future CM administration - in the electronic patient record.

The physician responsible for the administration of the contrast medium or the drug allergy specialist should accurately document severe or unusual hypersensitivity reactions to the National Pharmacovigilance Authority LAREB.

Notes: see also the [Introduction to Chapter 7](#)

## Literature

- Abe S, Fukuda H, Tobe K, Ibukuro K. Protective effect against repeat adverse reactions to iodinated contrast medium: Premedication vs. changing the contrast medium. *Eur Radiol.* 2016; 26(7): 2148-2154.
- Ahn KM, Ahn YH, Cho MK, Kang DY, Lee SY, Kang HR. Validation of practical pathway in patients with anaphylaxis to low osmolar contrast media: a retrospective cohort study. *J Allergy Clin Immunol Pract.* 2022; 10(10): 2685-2692.e2.
- Ahn YH, Kang DY, Park SB, Kim HH, Kim HJ, Park GY, et al. Allergic-like hypersensitivity reactions to gadolinium-based contrast agents: an 8-year cohort study of 154,539 patients. *Radiology.* 2022; 303(2): 329-336.
- American College of Radiology. ACR Manual on contrast media, v2022. Available at: [\[URL\]](#). Accessed: 1 April 2022.
- Ananthakrishnan L, Parrott DT, Mielke N, Xi Y, Davenport MS. Fidelity of electronic documentation for reactions prompting premedication to iodine-based contrast media. *J Am Coll Radiol.* 2021; 18(7): 982-989.
- Andrade MV, Hiragun T, Beaven MA. Dexamethasone suppresses antigen-induced activation of phosphatidylinositol 3-kinase and downstream responses in mast cells. *J Immunol.* 2004; 172(12): 7254.
- Bhatti ZS, Mervak BM, Dillman JR, Davenport MS. Breakthrough reactions to gadobenate dimeglumine. *Invest Radiol.* 2018; 53: 551-554.
- Böhm IB, van der Molen AJ. Recommendations for standardized documentation of contrast medium-induced hypersensitivity. *J Am Coll Radiol.* 2020; 17(8): 1027-1028.
- Cha MJ, Kang DY, Lee W, Yoon SH, Choi YH, Byun JS, et al. Hypersensitivity reactions to iodinated contrast media: a multicenter study of 196 081 patients. *Radiology.* 2019; 293: 117-124.
- Clement O, Dewachter P, Mouton-Faivre C, Nevoret C, Guilloux L, Bloch Morot et al. Immediate Hypersensitivity to Contrast Agents: The French 5-year CIRTACI Study. *EClinicalMedicine.* 2018; 1: 51-61.
- Davenport MS, Cohan RH, Caoili EM, Ellis JH. Hyperglycemic consequences of corticosteroid premedication in an outpatient population. *AJR Am J Roentgenol.* 2010; 194(6): W483-W488.
- Davenport MS, Mervak BM, Ellis JH, Dillman JR, Dunnick NR, Cohan RH. Indirect cost and harm attributable to oral 13-hour inpatient corticosteroid prophylaxis before contrast-enhanced CT. *Radiology.* 2016; 279(2): 492-501.
- Davenport MS, Cohan RH. The evidence for and against corticosteroid prophylaxis in at-risk patients. *Radiol Clin North Am.* 2017; 55(2): 413-421.

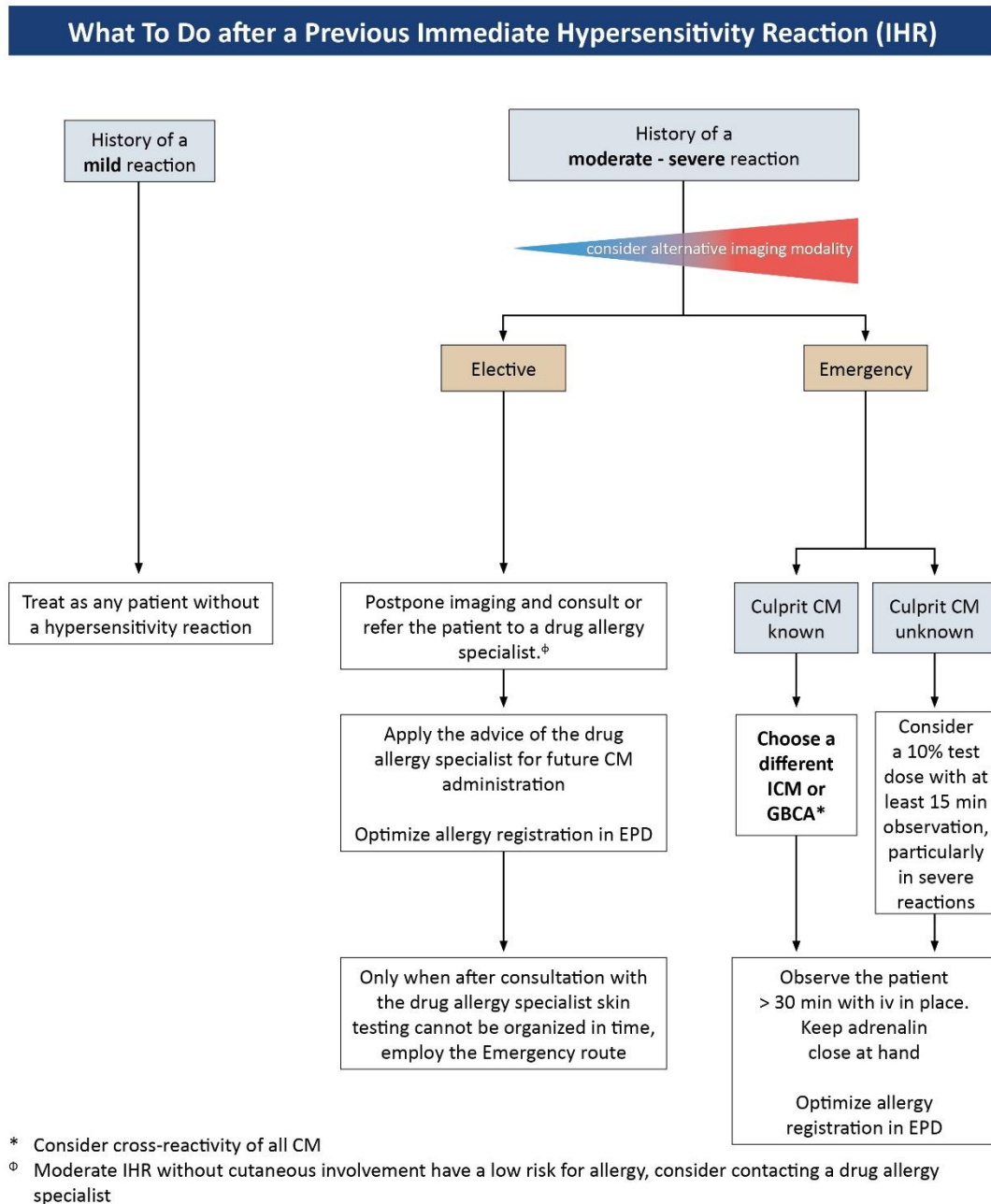
- Delaney A, Carter A, Fisher M. The prevention of anaphylactoid reactions to iodinated radiological contrast media: a systematic review. *BMC Med Imaging*. 2006; 6: 2.
- Deng F, Li MD, Wong A, Kowalski LT, Lai KH, Digumarthy SR, Zhou L. Quality of documentation of contrast agent allergies in electronic health records. *J Am Coll Radiol* 2019; 16: 1027-1035.
- European Society of Urogenital Radiology Contrast Media Safety Committee. ESUR Guidelines on contrast safety, v10, 2018. Available at: [URL](#) Accessed: 1 April 2022.
- Gallardo-Higueras A, Moreno EM, Muñoz-Bellido FJ, Laffond E, Gracia-Bara MT, Macias EM, et al. Patterns of cross-reactivity in patients with immediate hypersensitivity reactions to gadobutrol. *J Investig Allergol Clin Immunol*. 2021; 31(6): 504-506.
- Gamboa P, Sánchez de Vicente J, Galán C, Jáuregui I, Seguro A, García-Lirio E, et al. Tolerance to iopamidol in patients with confirmed allergic immediate hypersensitivity to iomeprol. *J Allergy Clin Immunol Pract*. 2021; 9(5): 2101-2103.e1.
- Gaudin O, Deschamps O, Duong TA, Gener G, Paul M, Luciani A, et al. Cutaneous tests, and interest of iobitridol in non-immediate hypersensitivity to contrast media: A case series of 43 patients. *J Eur Acad Dermatol Venereol*. 2020; 34(4): e178-e180.
- Gracia-Bara MT, Moreno E, Laffond E, Muñoz-Bellido F, Lázaro M, Macías E, et al. Tolerability of iobitridol in patients with non-immediate hypersensitivity reactions to iodine-based contrast media. *Allergy*. 2019; 74(1): 195-197.
- Greenberger PA, Patterson R, Simon R, Lieberman P, Wallace W. Pretreatment of high-risk patients requiring radiographic contrast media studies. *J Allergy Clin Immunol*. 1981; 67(3): 185-187.
- Greenberger PA, Patterson R, Radin RC. Two pretreatment regimens for high-risk patients receiving radiographic contrast media. *J Allergy Clin Immunol*. 1984; 74(4 Pt 1): 540-543.
- Greenberger PA, Halwig JM, Patterson R, Wallemark CB. Emergency administration of radiocontrast media in high-risk patients. *J Allergy Clin Immunol*. 1986; 77(4) :630-634.
- Grüber HP, Helbling A, Jörg L. Skin test results and cross-reactivity patterns in IgE- and T-cell-mediated allergy to gadolinium-based contrast agents. *Allergy Asthma Immunol Res*. 2021; 13(6): 933-938.
- Hartwig SC, Siegel J, Schneider PJ. Preventability and severity assessment in reporting adverse drug reactions. *Am J Hosp Pharm*. 1992; 49: 2229–2232.
- Jung JW, Choi YH, Park CM, Park HW, Cho SH, Kang HR. Outcomes of corticosteroid prophylaxis for hypersensitivity reactions to low osmolar contrast media in high-risk patients. *Ann Allergy Asthma Immunol*. 2016; 117(3): 304-309.e1.
- Kim YS, Choi YH, Cho YJ, Lee S, Yoon SH, Park CM, Kang HR. Incidence of breakthrough reaction in patients with prior acute allergic-like reactions to iodinated contrast media according to the administration route. *Korean J Radiol*. 2018; 19(2): 352-357.
- Lang M, Deng F, Singh R, DeFuria CL, Saini S, Alkasab TK. Implementation of a semistructured clinical event documentation tool for acute adverse contrast reactions. *J Am Coll Radiol*. 2022; 19(5): 655-662.
- Lasser EC, Berry CC, Mishkin MM, Williamson B, Zheutlin N, Silverman JM. Pretreatment with corticosteroids to prevent adverse reactions to nonionic contrast media. *AJR Am J Roentgenol*. 1994; 162(3): 523-526.
- Lee SH, Park HW, Cho SH, Kim SS. The efficacy of single premedication with antihistamines for radiocontrast media hypersensitivity. *Asia Pac Allergy*. 2016; 6(3): 164-167.
- Lee SY, Yang MS, Choi YH, Park CM, Park HW, Cho SH, Kang HR. Stratified premedication strategy for the prevention of contrast media hypersensitivity in high-risk patients. *Ann Allergy Asthma Immunol*. 2017; 118(3): 339-344.e1.

- Lerondeau B, Trechot P, Waton J, Poreaux C, Luc A, Schmutz JL, Paris C, Barbaud A. Analysis of cross-reactivity among radiocontrast media in 97 hypersensitivity reactions. *J Allergy Clin Immunol*. 2016; 137(2): 633-635.e4.
- Mankouri F, Gauthier A, Srisuwatchari W, Moutou A, Borushko A, Popa L, et al. Hypersensitivity to gadolinium-based contrast agents: A single-center retrospective analysis over 7 years. *J Allergy Clin Immunol Pract*. 2021; 9(4): 1746-1749.e2.
- McDonald JS, Larson NB, Kolbe AB, Hunt CH, Schmitz JJ, Maddox DE, et al. Prevention of allergic-like reactions at repeat CT: steroid pretreatment versus contrast material substitution. *Radiology*. 2021; 301(1): 133-140.
- Mervak BM, Davenport MS, Ellis JH, Cohan RH. Rates of breakthrough reactions in inpatients at high risk receiving premedication before contrast-enhanced CT. *AJR Am J Roentgenol*. 2015; 205(1): 77-84.
- Mervak BM, Cohan RH, Ellis JH, Khalatbari S, Davenport MS. Intravenous corticosteroid premedication administered 5 hours before CT compared with a traditional 13-hour oral regimen. *Radiology*. 2017; 285:425-433.
- Park HJ, Park JW, Yang MS, Kim MY, Kim SH, Jang GC, Nam YH, Kim GW, Kim S, Park HK, Jung JW, Park JS, Kang HR. Re-exposure to low osmolar iodine-based contrast media in patients with prior moderate-to-severe hypersensitivity reactions: A multicentre retrospective cohort study. *Eur Radiol*. 2017; 27:2886-2893.
- Park SJ, Kang DY, Sohn KH, Yoon SH, Lee W, Choi YH, Cho SH, Kang HR. Immediate mild reactions to CT with iodine-based contrast media: strategy of contrast media re-administration without corticosteroids. *Radiology*. 2018; 288:710-716.
- Park SK, Beaven MA. Mechanism of upregulation of the inhibitory regulator, src-like adaptor protein (SLAP), by glucocorticoids in mast cells. *Mol Immunol*. 2009;46(3):492. Epub 2008 Nov 25.
- Power S, Talbot N, Kucharczyk W, Mandell DM. Allergic-like reactions to the MR Imaging contrast agent gadobutrol: A prospective study of 32 991 consecutive injections. *Radiology*. 2016; 281(1): 72-77.
- Ryoo CH, Choi YH, Cheon JE, Yoon SH, Kang HR, Park SJ, Lee W. Preventive effect of changing contrast media in patients with a prior mild immediate hypersensitivity reaction to gadolinium-based contrast agent. *Invest Radiol*. 2019; 54: 633-637.
- Schmid AA, Böhm IB. Cross-Reactivity and Polyvalent Reactivity in Patients with Iodine-based Contrast Medium Allergy: How to Use the Terms Correctly. *Int Arch Allergy Immunol*. 2021; 182(8): 725-727.
- Schrijvers R, Breynaert C, Ahmedali Y, Bourrain JL, Demoly P, Chiriac AM. Skin testing for suspected iodine-based contrast media hypersensitivity. *J Allergy Clin Immunol Pract*. 2018; 6(4): 1246-1254.
- Sohn KH, Seo JH, Kang DY, Lee SY, Kang HR. Finding the optimal alternative for immediate hypersensitivity to low-osmolar iodine-based contrast. *Invest Radiol*. 2021; 56(8): 480-485.
- Shaker MS, Wallace DV, Golden DBK, et al. Anaphylaxis: a 2020 practice parameter update, systematic review, and Grading of Recommendations, Assessment, Development and Evaluation (GRADE) analysis. *J Allergy Clin Immunol* 2020; 145(4): 1082–1123.
- Specjalski K, Górska L, Wajda B, Chełmińska M, Jassem E. Oral premedication in patients with a history suggesting hypersensitivity to iodinated contrast media. *Adv Dermatol Allergol*. 2020; 37(4): 520-523.
- Tramer MR, von Elm E, Loubeyre P, Hauser C. Pharmacological prevention of serious anaphylactic reactions due to iodinated contrast media: systematic review. *BMJ* 2006; 333(7570): 675-682.
- Umakoshi H, Nihashi T, Takada A, Hirasawa N, Ishihara S, Takehara Y, et al. Iodinated contrast media substitution to prevent recurrent hypersensitivity reactions: A systematic review and meta-analysis. *Radiology*. 2022; 305(2): 341-349.

- Walker DT, Chakraborty S, Schieda N. Single-center retrospective analysis of breakthrough allergic-like reactions to gadobutrol. *Invest Radiol.* 2019; 54(7): 448-451.
- Walker DT, Davenport MS, McGrath TA, McInnes MDF, Shankar T, Schieda N. Breakthrough hypersensitivity reactions to gadolinium-based contrast agents and strategies to decrease subsequent reaction rates: a systematic review and meta-analysis. *Radiology.* 2020; 296(2): 312-321.
- Walker DT, McGrath TA, Glikstein R, Chakraborty S, Blanchette C, Schieda N. Empiric switching of gadolinium-based contrast agents in patients with history of previous immediate hypersensitivity reaction to GBCA: A prospective single-center, single-arm efficacy trial. *Invest Radiol.* 2021; 56:369-373.
- Yoon SH, Lee SY, Kang HR, Kim JY, Hahn S, Park CM, et al. Skin tests in patients with hypersensitivity reaction to iodinated contrast media: a meta-analysis. *Allergy.* 2015; 70(6): 625-637.

## Appendix 1. Flow charts

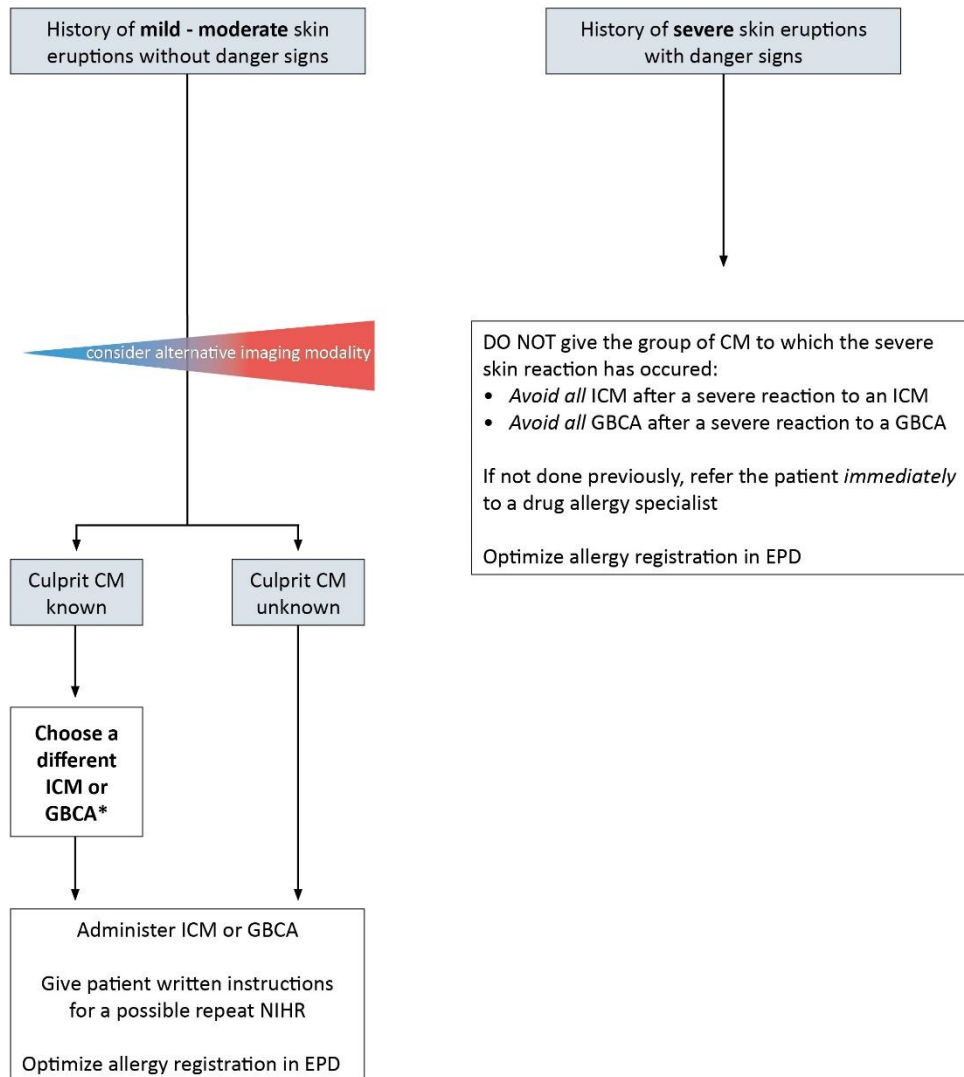
Flowchart 1: What to do after a previous immediate hypersensitivity reaction



Severity of previous immediate hypersensitivity reactions	
Mild	Scattered urticaria/pruritus, limited cutaneous oedema, itchy/scratchy throat, nasal congestion, and sneezing/conjunctivitis/rhinorrhoea.
Moderate	Diffuse urticaria/pruritus, diffuse erythema with stable vital signs, facial oedema without dyspnoea, throat tightness/hoarseness without dyspnoea, and mild wheezing/bronchospasm.
Severe	Diffuse erythema with hypotension, diffuse/facial oedema with dyspnoea, laryngeal oedema with stridor, severe wheezing/bronchospasm with hypoxia, and generalized anaphylactic reaction/shock.

**Flowchart 2: What to do after a previous nonimmediate hypersensitivity reaction**

**What To Do after a Previous Non-Immediate Hypersensitivity Reaction (NIHR)**



\* Consider cross-reactivity of all CM and increased risk of iso-osmolar ICM for NIHR

- Danger signs of non-immediate hypersensitivity reactions:**
- Erosive and/or haemorrhagic lesions.
  - Blistering and skin disruption.
  - Mucosal involvement.
  - Extracutaneous organ involvement (high fever, abnormal liver or kidney function, lymphadenopathy)



## Appendix 2. Contrast Media Hypersensitivity: The Lalli and Weber Effects

When using contrast media in medical imaging the user should be aware about two linked effects that may influence the frequency of acute hypersensitivity reactions, the Lalli and Weber effects.

### *Lalli Effect*

In the heydays of high osmolar ionic contrast media use in the 1970s it was demonstrated that fear and anxiety play an important role in the occurrence of hypersensitivity reactions to iodine-based contrast media (ICM), now termed the Lalli effect (Lalli, 1974; Thomsen, 2012). Anxiety causes the limbic system to interact with the hypothalamus. As contrast media pass the blood-brain barrier, it can interact with the hypothalamus and reticular formation of the medulla. In the hypothalamus the vasomotor system and respiratory system can become activated, leading to shock or respiratory arrest. Reticular formation activation can lead to nausea and emesis, as well as vagal reactions with bradycardia, hypotension, and bronchospasm. Finally, in the ventral and lateral funiculi of the spinal cord and in the stellate ganglion the sympathetic autonomous nervous system can become activated, which may result in pulmonary oedema, skin urticaria, or even ventricular fibrillation or cardiac arrest (Lalli, 1980 and 1981). It was shown that diazepam may be beneficial in apprehensive patients scheduled for imaging with ICM (Lalli, 1981).

### *Weber Effect*

The Weber effect is a well-known reporting bias from pharmacovigilance studies. The reporting of adverse effects after regulatory approval of a drug to the market peaks at the end of the second year after approval, and declines steadily thereafter (Weber, 1984). In the field of contrast media this effect has been demonstrated for gadopentetate (Aran, 2014) and for gadobenate (Fakhran, 2015). It was also demonstrated for nonsteroidal anti-inflammatory drugs (Hartnell, 2004), but could not be demonstrated for other drugs in the same Food & Drug Administration's Adverse Events Registration System (FAERS) (Hoffman, 2014). In daily medical imaging practice, it is important to realize that when one specific contrast medium is substituted for another, a significant transient increase in the frequency of reported hypersensitivity reactions may be seen (Davenport, 2013; Forbes-Amrhein, 2018).

## Literature

- Aran S, Shaqdan K, Abujudeh H. The Weber effect; A multi-year experience with gadopentetate dimeglumine administration. Radiological Society of North America 2014 Scientific Assembly and Annual Meeting, Chicago IL. Available at: [\[URL\]](#). Accessed May 20, 2022.
- Davenport MS, Dillman JR, Cohan RH, Hussain HK, Khalatbari S, McHugh JB, Ellis JH. Effect of abrupt substitution of gadobenate dimeglumine for gadopentetate dimeglumine on rate of allergic-like reactions. *Radiology*. 2013; 266(3): 773-782.
- Fakhran S, Alhilali L, Kale H, Kanal E. Assessment of rates of acute adverse reactions to gadobenate dimeglumine: review of more than 130,000 administrations in 7.5 years. *AJR Am J Roentgenol*. 2015; 204(4): 703-706.
- Forbes-Amrhein MM, Dillman JR, Trout AT, Koch BL, Dickerson JM, Giordano RM, Towbin AJ. Frequency and severity of acute allergic-like reactions to intravenously administered gadolinium-based contrast media in children. *Invest Radiol*. 2018; 53(5): 313-318.

- Hartnell NR, Wilson JP. Replication of the Weber effect using post-marketing adverse event reports voluntarily submitted to the United States Food and Drug Administration. *Pharmacotherapy* 2004; 24(6): 743–749.
- Hoffman KB, Dimbil M, Erdman CB, Tatonetti NP, Overstreet BM. The Weber effect and the United States Food and Drug Administration's Adverse Event Reporting System (FAERS): analysis of sixty-two drugs approved from 2006 to 2010. *Drug Saf.* 2014; 37(4): 283-294.
- Lalli AF. Urographic contrast media reactions and anxiety. *Radiology.* 1974; 112(2): 267-271.
- Lalli AF. Contrast media reactions: data analysis and hypothesis. *Radiology.* 1980; 134(1): 1-12.
- Lalli AF, Greenstreet R. Reactions to contrast media: testing the CNS hypothesis. *Radiology.* 1981; 138(1): 47-49.
- Thomsen HS, Webb JAW. The Lalli and Weber effects and the incidence of acute non-renal adverse reactions to contrast media. *Acta Radiol.* 2012; 53(9): 953-954.
- Weber JCP. Epidemiology of adverse reactions to nonsteroidal anti-inflammatory drugs. In: Rainsford KD, Velo GD, editors. *Side-effects of Anti-inflammatory Drugs, Advances in Inflammation Research.* New York: Raven Press; 1984: 1–7.

### Appendix 3. Allergology Services in The Netherlands

<i>Hospital</i>	<i>Location</i>	<i>Internist-Allergologists (including residents)</i>	<i>Paediatrician- Allergologists (including residents)</i>
Albert Schweitzerziekenhuis*	Zwijndrecht	2	0
Catharinaziekenhuis	Eindhoven	1	1
Deventer ziekenhuis	Deventer	0	2
Diakonessenhuis	Utrecht	3	1
Elkerliek Ziekenhuis	Helmond	0	1
Erasmus MC	Rotterdam	8	4
ETZ	Tilburg	4	0
Groene Hart ziekenhuis	Gouda	1	1
Leiden UMC	Leiden	1*	0
Maasstadziekenhuis*	Rotterdam	2	0
Martini ziekenhuis	Groningen	0	1
Noordwest Ziekenhuis Groep	Alkmaar	0	1
Reinier de Graaf	Delft	2	4
Rijnstate ziekenhuis	Arnhem	3	1
Spaarnegasthuis	Haarlem	1	1
Tergooi Ziekenhuizen	Hilversum	1	0
UMC Amsterdam*	Amsterdam	3	3
UMC Groningen	Groningen	8	2
UMC Maastricht*	Maastricht	2	0
UMC Utrecht*	Utrecht	3	0
Zaans medisch centrum	Zaandam	1	0
ZGT	Hengelo	2	0
Zuyderland Medisch Centrum	Heerlen	0	1
<b>Total</b>		<b>45</b>	<b>24</b>

*\*Dermatologists having allergology services*

## Chapter 8 Analytical Interference of Contrast Media with Clinical Laboratory Tests

### Clinical question

How can contrast media interfere with commonly performed laboratory tests?

- 1 Iodine-based contrast media' interference
- 2 Gadolinium-based contrast agents' interference

### Introduction

Radiological imaging with (or without) contrast media (CM) and laboratory tests are commonly used complimentary tools in the diagnosis and monitoring of patients. In terms of efficient patient work-up, these tools are often planned together. Though most clinicians are not aware, several studies have reported interference of iodine-based contrast media (ICM) and gadolinium-based contrast agents (GBCA) with several clinical laboratory tests.

Awareness of these interferences is important since they may pose a potential threat by misdiagnosing and/or incorrect monitoring of patients, denying or delaying their treatment or initiating/continuing undesirable treatment (Doorenbos, 2003). These clinically relevant interferences are specific for the contrast media administered as well as for the specific technique/method used for the analysis of the biomarker (Otnes, 2017).

N.B. (Patho)physiological responses of the body, represented by specific biomarkers, e.g., thyroid function (Bednarczuk, 2021), coagulation status (Aspelin, 2006; Lukasiwicz, 2012), due to the administration of contrast agents are outside of the scope of this chapter.

### Systematic literature analysis

For this chapter it was decided not to perform a systematic literature analysis.

### Narrative literature analysis / Justifications – evidence to decision

#### ***1. Iodine-based contrast media interference with laboratory tests***

The effect of iodine-based contrast media (ICM) on clinical assays has not been systematically studied extensively. Depending on method and ICM used, interference may be clinically relevant (Morcos, 2005). M-protein analysis is paramount in the diagnosis and monitoring of monoclonal gammopathy (Dimopoulos, 2021). Several studies report interference of ICM on the spectrophotometric detection of monoclonal protein analysis by capillary zone electrophoresis with spectrophotometric detection (CZE-UV) (Quirós, 2018). ICM absorb UV-light at a similar wavelength as the peptide bonds in m-proteins, thereby mimicking the presence of (M-)proteins in the commonly used CZE analysis with UV detection. In contrast, Capaldo and co-workers (Capaldo, 2021) demonstrated that the opposite may also occur, i.e., masking an M-protein peak. In the M-protein analysis by CZE-UV, a duplication in the beta-2 fraction which was at first assigned to ICM (iomeprol) interference and the beta-1 fraction did not display any M-protein peak. Further analysis demonstrated that the iomeprol peak should appear in the beta-1-fraction and not in the beta-2-fraction. After 6 days, a new urine sample demonstrated a m-protein in the beta-1-fraction, which was masked by the iomeprol interference.

Otnes and co-workers investigated in vitro the analytical interference of two specific ICM, iodixanol and iomeprol (Otnes, 2017). They reported in the high, but clinically relevant, concentration range of the ICMs, either a positive bias (colorimetric calcium assay) or a negative bias, i.e., colorimetric iron, magnesium, and zinc assay as well as in the direct potentiometric sodium assay. Other assays did not show any interference with both ICMs. In another study, Lin and co-workers (Lin, 2006) investigated the interference of ICM on two cardiac Troponin I immunoassays (Opus Magnum (Behring Diagnostics) and the Access (Beckman Coulter, Inc)) in patients undergoing coronary angiography. In two in-vivo and two in-vitro experiments, they demonstrated a clinically relevant interference of the ICM on the cardiac levels on the Opus system, especially in the samples obtained directly after the coronary angiography procedure. The interference was absent in the sample after 30 minutes from patients with normal kidney function and lasted longer than 30 min in patients with reduced kidney function. In contrast the Access did not show any interference in the in vivo experiments. In the same study, in vitro experiments of 12 different ICMs showed a similar interference on the Opus system for all ICMs and only one (Lipiodol) on the Access system. A similar interference by iohexol on endocrine immunoassays was observed by Loh and co-workers in in-vitro experiments (Loh, 2013). They reported that soon after contrast administration iohexol may affect follicle stimulating hormone (FSH), luteinizing hormone (LH), plasma renin activity (PRA) and thyrotropin (TSH) measurements by different manufacturers. The interference on immunoassays may be explained by either the presence of an unidentified antigenic site on the contrast medium molecule blocking or cross-reacting with antibodies, dilutional effects due to the high osmolar aspects of iohexol and/or, as described before, due to spectrophotometric aspects of the ICM, interfering with UV-detection.

Next to the photometric aspects of ICM, the higher refractive index of the ICMs interference may occur in urinary analysis, e.g., specific gravity measurement (Glasson, 2012; Oyaert, 2021; Strassinger, 2008).

Besides interference on laboratory testing, sample integrity and quality may be impacted (Lippi, 2014). Since, due to the presence of ICM in the blood, the density of blood is altered, thereby potentially influencing gel cell separator characteristics resulting in incorrect plasma or serum collection (Daves, 2012; Kaleta, 2012; Spiritus, 2003).

Table 8.1 shows commonly demonstrated ICM interference on clinical laboratory tests. Unfortunately, there are not many systematic studies addressing CM interference on clinical laboratory tests and recommendations (Stacul, 2018) rely mainly on CM elimination. ESUR for instance recommends performing blood and urine clinical tests prior to administration of the GBCA, to circumvent interference and incorrect assessment of the patient. Post-imaging non-emergency blood and urine analysis should be delayed until the CM concentration in blood and/or urine is not present anymore. In emergency testing, blood and urine analysis can be performed, though clinicians and laboratory specialists should be aware of potential interference of CM. As is with all laboratory tests, the results should be interpreted in relationship with the patient’s medical history and clinical examination.

**Table 8.1 Clinical and/or analytical significant analyte interference of specific ICMs**

Iodine-based Contrast Media				
Analyte	Method/technique	Name ICM	Observed Interference (bias)	Reference
Albumin	Colorimetric assay	Iodixanol	↑	Otnes, 2017

Aldosterone	Radioimmunoassay with I <sup>125</sup> -tracer	iohexol	↓	Loh, 2013
Bicarbonate	Enzymatic assay	lomeprol, iodixanol	↓	Otnes, 2017
Calcium	Colorimetric assay	lomeprol, iodixanol	↑	Otnes, 2017
Chloride	Ion selective electrode	iohexol	↓	Sankaran, 2019
Cortisol	Immunoassay with spectrophotometric detection	iohexol	↑	Loh, 2013
C-peptide	Immunoassay with spectrophotometric detection	iohexol	↓	Loh, 2013
Erythrocytes in urine	Fluorescence flow cytometry	lomeprol	↑	Oyaert, 2021
Follicle Stimulating Hormone	Immunoassay with spectrophotometric detection	iohexol	↓	Loh, 2013
Insulin	Immunoassay with spectrophotometric detection	iohexol	↓	Loh, 2013
Iron	Colorimetric assay	iodixanol	↑	Otnes, 2017
LDH	Enzymatic assay	iodixanol	↓	Otnes, 2017
Leukocytes in urine	Fluorescence flow cytometry	lomeprol	↑	Oyaert, 2021
Luteinizing Hormone	Immunoassay with spectrophotometric detection	iohexol	↓	Loh, 2013
Magnesium	Colorimetric assay	lomeprol	↓	Otnes, 2017
M-proteins	CZE-UV	lomeprol, iohexol, meglumine iotroxate, sodium meglumine amidotrizoate, loversol, lopromide, lobitridol, lopamidol, loxitalamic acid, loversol	↑, ↓	Arranz-Pena, 2004; Capaldo, 2021; Vermeersch, 2006;
Potassium	Potentiometric assay	iodixanol, lomeprol	↑	Otnes, 2017
Renin activity	Radioimmunoassay with I <sup>125</sup> -tracer	iohexol	↓	Loh, 2013
Sodium	Potentiometric assay, Ion selective electrode	lometrol, iodixanol, iohexol	↓	Otnes, 2017; Sankaran, 2019
Specific gravity in urine	Refractometry	lomeprol, iohexol, iodixanol	↑	Giasson, 2012; Oyaert, 2021
Thyroid Stimulating Hormone	Immunoassay with spectrophotometric detection	iohexol	↓	Loh, 2013

Troponin I	Immuno-enzymatic assay	11 ICMs, a.o. Iopromide, ioversol, iohexol	↑	Lin, 2006
Zinc	Colorimetric assay	Iodixanol	↓	Otnes, 2017

*N.B. Interference may be manufacturer/analyser specific. For detailed information see references.*

## **2. Gadolinium-based contrast agent interference with laboratory tests**

Since the introduction of gadolinium-based contrast agents (GBCA) in 1983, these contrast agents have been used extensively. Several interferences on laboratory tests have been described, ranging from commonly used laboratory tests (Lippi, 2014) to more specialized laboratory tests (Day, 2019). One of the most reported clinically relevant interferences is the interference of GBCAs, especially gadodiamide (Normann, 1995; Prince, 2003; Prince, 2004; Zhang, 2006) and gadoversetamide (Lin, 1999) on serum calcium measurement by specific colorimetric methods, irrespective of the molecular configuration of the CA (i.e., linear or cyclic and ionic or non-ionic) (Prince, 2003). Depending on the colorimetric method used the potential bias could be either absent, positive, or negative. In principle, other methods to measure calcium, e.g., Inductively Coupled plasma Mass Spectrometry (ICP-MS) does not demonstrate clinically relevant interference.

In an in-vitro study Proctor and co-workers (Proctor, 2004) investigated the analytical interference of four GBCAs on multiple analytes and multiple analysers. They demonstrated that depending on the specific GBCA a positive and negative analytical interference is observed, which is most prominent in Angiotensin Converting Enzyme (ACE), calcium, iron, total iron binding capacity (TIBC), magnesium and zinc. Mechanistically, all the affected analytes are either endogenous divalent cations or somehow use divalent cations in the reaction of the laboratory test.  $Gd^{3+}$  can interact with the analyte of interest (e.g., transmetallation), thereby potentially interrupting the analytical process or in colorimetric assays by binding with the chromophore (Yan, 2014). In an in-vitro experiment, Otnes and co-workers demonstrated a similar interference by the GBCAs gadoxetate disodium, gadoterate meglumine, and gadobutrol on iron and zinc (negative bias) assays. Other 29 clinical tests did not display any clinically relevant interference by these GBCAs (Otnes, 2017).

In the field of trace elements and heavy metals, ICP-MS is the golden standard.  $Gd^{3+}$  may interfere also with this technique in multiple ways, i.e., space-charge effects, interference in the mass spectrometry analysis by double charged ions and polyatomic interference (Day, 2019). The latter can be circumvented by applying the correct analytical technique. In the study, Day and co-workers shared their experience with the clinical impact of GBCA interference in their clinical metal's laboratory. Especially in the analysis of selenium by ICP-MS is complicated by the presence of  $^{156}Gd$  which may be doubly charged in the ionization process and therefore has a similar m/z ratio. Moreover, the presence of excess of Gd ions may interfere with the ionization process, suppressing ions of analytes, e.g., trace elements or (toxic) heavy metals and internal standards used.

It is worth noting that many studies report interference of gadodiamide and gadoversetamide on calcium assays but these GBCAs no longer available on the European market.

Table 8.2 shows commonly described GBCA interference on clinical laboratory tests. Assay interference by GBCAs can be contrast agent specific, analyte specific and method specific.

**Table 8.2 Clinical and/or analytical significant analyte interference of specific GBCA.**

Gadolinium Based Contrast Agents				
Analyte	Method/technique	Name GBCA	Observed interference (bias)	Reference
ACE	Colorimetric enzymatic reaction	Gadodiamide, gadoversetamide	↓	Proctor, 2004
calcium	Several colorimetric assays	Gadodiamide, gadoversetamide	↓	Proctor, 2004; Yan, 2014
Iron	Colorimetric assay	Gadodiamide, gadoversetamide, gadopentetate dimeglumine, gadoxetate disodium	↓, ↑	Otnes, 2017; Proctor, 2004
Magnesium		Gadodiamide, gadoversetamide	↓, ↑	Proctor, 2004
Selenium	ICP-MS	Not specified	↑	Harrington, 2014; Ryan, 2014
TIBC	Colorimetric assay	Gadodiamide, gadoversetamide	↑	Proctor, 2004
Troponin I	Immuno-enzymatic assay	Gadopentetate dimeglumine	↑	Lin, 2006
Zinc	Colorimetric assay	Gadodiamide, gadoversetamide, gadopentetate dimeglumine, gadoteridol, gadoxetate disodium	↓	Otnes, 2017; Proctor, 2004

*N.B. Interference may be manufacturer/analyser specific. For detailed information see references. Note: Gadodiamide and gadoversetamide are currently not on the market in the EU.*

## Recommendations

*Recommendations are similar to the recommendations in the [ESUR guideline version 10.0](#) (ESUR, 2018; Morcos, 2005) and based on pharmacokinetics and elimination recommendations in [Chapter 5 Safe time intervals between contrast-enhanced studies](#).*

### Blood Analysis

Be aware that the potential interference of contrast media on laboratory tests is crucial to prevent adverse patient work-up. As with all laboratory tests, the results should be interpreted in relationship with the patient's medical history and clinical examination.

Consult the laboratory specialist if there are any discrepancies between clinical presentation and laboratory tests.

Perform clinical laboratory testing prior to administering contrast media or delay blood collection for non-emergency clinical laboratory testing\* for:



- At least 4 hours and optimally 12 hours after administration of the contrast medium in patients with normal kidney function (eGFR > 60 mL/min/1.73 m<sup>2</sup>)
- At least 16 hours and optimally 48 hours after administration of the contrast medium in patients with reduced kidney function (eGFR 30-60 mL/min/1.73 m<sup>2</sup>)
- At least 60 hours and optimally 168 hours after administration of the contrast medium in patients with reduced kidney function (eGFR < 30 mL/min/1.73 m<sup>2</sup>)

\*See also [Chapter 5 Safe time intervals](#)

### Urine Analysis

Perform urine clinical laboratory tests prior to contrast media administration. Another option is to delay urine collection for at least\*\*:

- 24 hours after administration of the contrast medium in patients with normal kidney function (eGFR > 60 mL/min/1.73 m<sup>2</sup>)
- 48 hours after administration of the contrast medium in patients with reduced kidney function (eGFR 30-60 mL/min/1.73 m<sup>2</sup>)
- 168 hours after administration of the contrast medium in patients with reduced kidney function (eGFR < 30 mL/min/1.73 m<sup>2</sup>)

\*\* based on near complete clearance of contrast media

### **Literature**

- Arranz-Pena ML, Gonzalez-Sagrado M, Olmos-Linares AM, Fernandez-Garcia N, Martin-Gil FJ. Interference of iodinated contrast media in serum capillary zone electrophoresis. *Clin Chem* 2000; 46: 736-737.
- Aspelin P, Stacul F, Thomsen HS, Morcos SK, van der Molen AJ, Members of the Contrast Media Safety Committee of the European Society of Urogenital Radiology (ESUR). Effects of iodinated contrast media on blood and endothelium. *Eur Radiol* 2006; 16(5): 1041-1049.
- Bednarczuk T, Brix TH, Schima W, Zetting G, Kahaly G. 2021 European Thyroid Association guidelines for the management of iodine-based contrast media-induced thyroid dysfunction. *Eur Thyroid J.* 2021; 10(4): 269-284.
- Capaldo C, El Aouni MC, Laurelli D, Leven C, Carré JL. Detection of monoclonal protein by capillary zone electrophoresis can be challenged by iodinated contrast agent interference: a case report. *Biochem Med (Zagreb)* 2021; 31(2): 021001.
- Daves M, Lippi G, Cosio G, Raffagnini A, Peer E, Dangella A, et al., An unusual case of a primary blood collection tube with floating separator gel. *J Clin Lab Anal.* 2012; 26(4): 246-247.
- Day P, Erdahl S, Eckdahl S, Bornhorst J, Jannetto PJ. Gadolinium-based contrast agents: A clinically significant analytical interference in inductively coupled plasma mass spectrometry elemental analysis. *Ann Clin Biochem.* 2019; 56(6): 638-645.
- Dimopoulos MA, Moreau P, Terpos E, Mateos MV, Zweegman S, Cook G, et al. Multiple myeloma: EHA-ESMO Clinical Practice Guidelines for diagnosis, treatment and follow-up. *Ann Oncol* 2021; 32(3): 309-322.
- Doorenbos CJ, Ozyilmaz A, van Wijnen M. Severe pseudohypocalcemia after gadolinium-enhanced magnetic resonance angiography. *N Engl J Med* 2003; 349(8): 817-818.
- European Society of Urogenital Radiology Contrast Media Safety Committee. ESUR Guidelines on contrast safety, v10, 2018. Available at: [\[URL\]](#) Accessed: 1 April 2022.

- Giasson J, Chen Y. A discrepant urine specific gravity. *Clin Chem* 2012; 58(4): 797.
- Harrington CF, Walter A, Nelms S, Taylor A. Removal of the gadolinium interference from the measurement of selenium in human serum by use of collision cell quadrupole inductively coupled plasma mass spectrometry (Q-ICP-MS). *Ann Clin Biochem* 2014; 51(Pt 3): 386-391.
- Kaleta EJ, Jaffe AS, Baumann NA, Block DR. A case of floating gel. *Clin Chem* 2012; 58(11): 1604-1605.
- Lin J, Idee JM, Port M, Dai A, Berthommier C, Robert M, et al. Interference of magnetic resonance imaging contrast agents with the serum calcium measurement technique using colorimetric reagents. *J Pharm Biomed Anal* 1999; 21(5): 931-943.
- Lin CT, Lee HC, Voon WC, Yen HW, Tang MH, Chin TT, et al. Positive interference from contrast media in cardiac troponin I immunoassays. *Kaohsiung J Med Sci* 2006; 22(3): 107-113.
- Lippi G, Daves M, Mattiuzzi C. Interference of medical contrast media on laboratory testing. *Biochem Med (Zagreb)* 2014; 24(1): 80-88.
- Loh TP, Mok SF, Ang BW, Chuah TY, Sethi SK. Non-ionic radiologic contrast (iohexol) interferes with laboratory measurements of endocrine hormones. *Pathology* 2013; 45(5): 527-529.
- Lukasiewicz A, Lebkowska U, Galar M. Effect of iodinated low-osmolar contrast media on the hemostatic system after intraarterial and intravenous contrast administration. *Adv Med Sci* 2012; 57(2): 341-347.
- Morcos SK, Thomsen HS, Exley CM; Members of Contrast Media Safety Committee of European Society of Urogenital Radiology (ESUR). Contrast media: interactions with other drugs and clinical tests. *Eur Radiol* 2005; 15(7): 1463-1468.
- Normann PT, Froyso A, Svaland M. Interference of gadodiamide injection (Omniscan) on the colorimetric determination of serum calcium. *Scan J Clin Lab Invest* 1995; 55(5): 421-426.
- Otnes S, Fogh-Andersen N, Rømsing J, Thomsen HS. Analytical interference by contrast agents in biochemical assays. *Contrast Media Mol Imaging* 2017; 2017: 1323802.
- Oyaert MN, De Buyzere ML, Verstraete KL, Speeckaert MM, Delanghe JR. Iodine containing contrast media and urinary flow cytometry: an unknown interference in automated urine sediment analysis. *Clin Chem Lab Med* 2021; 59(8): e335-e337.
- Prince MR, Erel HE, Lent RW, Blumenfeld J, Kent KC, Bush HL, et al. Gadodiamide administration causes spurious hypocalcemia. *Radiology* 2003; 227(3): 639-646
- Prince MR, Choyke PL, Knopp MV. More on pseudohypocalcemia and gadolinium-enhanced MRI. *N Engl J Med* 2004; 350(1): 87-88.
- Proctor KA, Rao LV, Roberts WL. Gadolinium magnetic resonance contrast agents produce analytic interference in multiple serum assays. *Am J Clin Pathol* 2004; 121(2): 282-292.
- Quirós C, Cillero AI, Bretaña L, García M, Prieto B, Álvarez FV. In vivo interference of Ioversol in serum and urine capillary electrophoresis: an optimized protocol for sample collection. *Clin Chem Lab Med* 2018; 26;56(2): e53-e55.
- Ryan JB, Grant S, Walmsley T, Florkowski CM, George PM. Falsely elevated plasma selenium due to gadolinium contrast interference: a novel solution to a preanalytical problem. *Ann Clin Biochem* 2014; 51(6): 714-716.
- Sankaran S, Saharia GK, Naik S, Mangaraj M. Effect of iodinated contrast media on serum electrolyte concentrations in patients undergoing routine contrast computed tomography scan procedure. *Int J Appl Basic Med Res* 2019; 9(4): 217-220.
- Stacul F, Bertolotto M, Thomsen HS, Pozzato G, Ugolini D, Bellin MF, et al. ESUR Contrast Media Safety Committee. Iodine-based contrast media, multiple myeloma and monoclonal gammopathies: literature review and ESUR Contrast Media Safety Committee guidelines. *Eur Radiol* 2018; 28(2): 683-691.

- Strasinger SK, Di Lorenzo MS. Urinalysis and body fluids. 5th ed. Philadelphia: F.A. Davis, 2008.
- Spiritus T, Zaman Z, Desmet W. Iodinated contrast media interfere with gel barrier formation in plasma and serum separator tubes. *Clin Chem* 2003; 49(7): 1187-1189.
- Vermeersch P, Mariën G, Bossuyt X. Pseudoparaproteinemia related to iomeprol administration after angiocardiology: Detection in the beta fraction by capillary zone electrophoresis. *Clin Chem* 2006; 52(12): 2312–2313.
- Yan R, Tarr H, McNally M, Cartier LJ, Chen Y. Interference of gadolinium-based contrast agents on colorimetric calcium assays. *Clin Biochem* 2014; 47(7-8): 648-653.
- Zhang HL, Ersoy H, Prince MR. Effects of gadopentetate dimeglumine and gadodiamide on serum calcium, magnesium, and creatinine measurements. *J Magn Reson Imaging* 2006; 23(3): 383-387.

## Chapter 9 Gadolinium Deposition after Administration of Gadolinium-Based Contrast Agents

### Content

This chapter is partly new and partly an update of the modules about gadolinium deposition in the previous guideline [Safe Use of Contrast Media, part 2](#).

Contents of chapter 9:

- Introduction to Safe Use of Gadolinium-Based Contrast Agents (updated)
- Module 9.1 Gadolinium deposition in the brain and body (updated)
- Module 9.2 Strategies for Dose Reduction of Gadolinium-Based Contrast Agents (new)

### Introduction to Safe Use of Gadolinium-Based Contrast Agents

*Disclaimer: This narrative review has been written by members of the Guideline Development Group so that non-specialized readers can follow the Modules 9.1-9.2 more easily. It was not part of the actual guideline process with structured literature analyses.*

Gadolinium-based contrast agents (GBCA) are routinely used in patients undergoing magnetic resonance imaging (MRI) to enhance image contrast and thereby improving detection and characterization of lesions. These agents exploit the highly paramagnetic nature of gadolinium (Gd), which alters the local magnetic properties shortening both  $T_1$  and  $T_2$  of tissue leading to increased signal intensity on  $T_1$ -weighted images (and reduced signal intensity on  $T_2$ -weighted images) (Elster, 2021). Since their introduction in 1988, an estimate of 700 million doses have been delivered and the current (end of 2021) estimated use is 50 million doses per year (Balzer, 2017; Endrikat, 2018, McDonald, 2018; Bayer AG estimates based on various internal and external data, 2022). Overall, 30--45% of the MRI scans have used GBCAs, with high contributions in current sales by Neuroradiology (~40%) and Cardiovascular Radiology (~20%) (Bayer AG estimates, based on various internal and external data, 2022).

### I Gadolinium Physicochemistry

#### Gadolinium and relaxivity

Gadolinium (Gd;  $Z = 64$  and  $MW = 157,25$  g/mol) is a rare earth metal from the Lanthanide family of elements in the periodic system. It has seven unpaired electrons in its 4f orbitals, has a high magnetic moment, and a very long electron spin relaxation time (Caravan, 1999; Hao, 2012; Lin, 2007).

The efficiency of  $T_1$ -weighted contrast agents in aqueous solutions is determined by its relaxivity ( $R_1 = 1 / T_1$ ). The relaxivity is determined by relaxation effects of water molecules interacting directly with the paramagnetic ion (inner sphere) and interactions with closely diffusing water molecules without interacting with the M-L complex (outer sphere).

For clinical GBCA 60% of relaxivity comes from inner sphere effects and 40% from outer sphere effects. Chelated gadolinium complexes are monohydrated ( $Gd(H_2O)^{3+}$ ), as in their spherical configuration there is only enough space around the gadolinium for one (inner

sphere) water molecule that exchanges rapidly with other nearby water molecules (outer sphere) (De Leon-Rodriguez, 2015).

#### Gadolinium chelation and stability constants

In biological systems, unchelated  $Gd^{3+}$  ions are toxic because the ion has an ionic radius (107,8 pm) close to the ionic radius of  $Ca^{2+}$  (114 pm) and can bind to  $Ca^{2+}$  ion channels and  $Ca^{2+}$ -dependent proteins such as metalloenzymes or messenger proteins like calmodulin or calxetin.

To suppress this potential toxicity, the  $Gd^{3+}$  ions must be tightly bound to an organic ligand to form a metal-ligand (ML) complex or chelate. The ligand will reduce toxicity, change the tissue distribution, and influence relaxivity. In the current European situation, such ligands are macrocyclic (DOTA, BT-DO3A or HP-DO3A) or linear (BOPTA or EOB-DTPA) ([Supplemental Table S2](#)).

Normally, equilibrium exists for the reaction between metal M and ligand L.  
The reaction can be written as:  $(M) + (L) \leftrightarrow (ML)$

The stability of the Gadolinium-ligand complex can be described by a number of constants.

The logarithm of the thermodynamic stability constant  $K_{\text{therm}}$  describes the affinity of Gd for the ligand and is normally measured at pH = 14. Higher values imply a higher stability.

$$K_{\text{therm}} = (ML) / (M) \cdot (L).$$

For biological systems more appropriate is the logarithm of the apparent or conditional thermodynamic stability constant  $K_{\text{cond}}$ , which considers the total concentration of the free ligand, including all its protonation states. It characterizes the affinity of Gadolinium for ligand in aqueous media under physiologic conditions (pH = 7,4). In all GBCA the conditional stability is substantially lower than the thermodynamic stability.  $K_{\text{cond}} = (ML) / (M) \cdot \{(L) + (HL) + (H_2L) + \dots\}$

The kinetic stability describes the kinetic rate of the dissociation of the Gadolinium-Ligand complex. It is closely related to the thermodynamic stability and is commonly described as the half-life of the dissociation of the Gd-Ligand complex or by the observed dissociation constant  $k_{\text{obs}}$ . To be measurable, such kinetic analyses are done under acidic conditions at pH =1 (Port, 2008). Dissociation rate =  $k_{\text{obs}} (ML)$ .

Some commercial solutions of contrast media contain variable amounts of free ligands or calcium complexes to ensure chelation of any free  $Gd^{3+}$  or other metal traces from the vial during its shelf life. This amount is often used as indirect indicator of the instability of the compound.

The thermodynamic stability constants are a measure of how much uncomplexed  $Gd^{3+}$  will be released in biologic tissues if the system reaches equilibrium. In vivo, such new thermodynamic equilibrium is usually not reached as most of the complex is excreted long before any uncomplexed gadolinium can be released. Therefore, the kinetic stability is in vivo much more important than the thermodynamic stability.

#### Transmetallation

Transmetallation is the exchange between  $Gd^{3+}$  and other metal ions  $M^+$  that have greater affinity for the chelate. The amount of transmetallation depends on the stability of the chelating ligand. Gadolinium ions can be removed from the Gd-ligand complex by several

endogenous positively charged ions like  $Zn^{2+}$ ,  $Cu^{2+}$ , and  $Ca^{2+}$  whereby  $Gd^{3+}$  is released, while endogenous negatively charged ions like  $PO_4^{3-}$  and  $CO_3^{2-}$  can compete with the free ligand to form insoluble toxic  $Gd^{3+}$  compounds like  $GdPO_4$  or  $Gd_2(CO_3)_3$  (Idee, 2006).

Transmetallation can be described by the reaction:  $(Gd-L) + (M^+) \leftrightarrow Gd^{3+} + (ML)$

Of the most frequently described stability constants, a high kinetic stability is regarded as the most important to minimize transmetallation. Since the stability of the macrocyclic Gd chelates is much more limited by the slow release of  $Gd^{3+}$  from the complex, the kinetic stability is more important in such ligands.

The main physicochemistry and stability data of current GBCA are summarized in [Supplemental Table S2](#).

#### Biodistribution and Elimination (see [Chapter 5](#) for more details)

After intravenous administration, the GBCA is excreted by the kidneys with an early elimination half-life of about 1.5 h in patients with normal renal function. More than 90% of the injected GBCA is cleared from the body within 12 h. This early excretion phase is similar for linear and macrocyclic GBCA.

In patients with severely reduced renal function ( $eGFR < 30 \text{ ml/min/1.73m}^2$ ) this elimination half-life for GBCA can increase up to 18-34 h (Joffe, 2008). During that time there is a potential for transmetallation with an increased release of free  $Gd^{3+}$  ions (Aime, 2009).

Recent systematic review of pharmacokinetic analysis revealed a deep compartment of distribution with long-lasting residual excretion. This long-lasting excretion is faster for macrocyclic compared to linear GBCA, correlated to the higher thermodynamic stability and differences in transmetallation. In addition, bone residence time for macrocyclic GBCA (up to 30 days) was much shorter than for linear GBCA (up to 2,5 years) (Lancelot, 2016).

## **II Gadolinium Deposition in the Brain and Body (See [Module 9.1 for update 2022](#))**

### A. Gadolinium Deposition in the Brain

#### *Clinical studies*

In 2014, it was suggested that the retrospectively observed hyperintensity of the dentate nucleus and the globus pallidus relative to the pons (dentate nucleus to pons (DNP) ratio) on unenhanced  $T_1$ -weighted images of a population of patients with brain tumours, was related to repeated administrations of linear GBCAs (Kanda, 2014). Almost simultaneously, another group reported similar findings on unenhanced  $T_1$ -weighted brain images after multiple injections of gadodiamide in patients with multiple sclerosis and patients with brain metastases (Errante, 2014).

After these initial reports, a multitude of retrospective studies have found increased SI in the dentate nucleus and or globus pallidus for linear GBCA. No such increases were found for macrocyclic GBCA, even after large doses (Radbruch, 2015 and 2017; Ramalho, 2016). In a recent systematic review of these studies by the ESMRMB Gadolinium Research Evaluation Committee (now ESMRMB-GREC) it was shown that there was large variety in sequence type and evaluation methodologies (Quattrocchi, 2019).

One of the biggest problems is that increased SI ratios at unenhanced T<sub>1</sub>-weighted MRI are a poor biomarker for gadolinium deposition, as SI ratios do not have linear relationship with Gd concentration and are highly dependent on the MRI parameters used during acquisition. Absolute signal intensity (expressed in arbitrary units) in MRI depends on many MRI parameters such as field strength, sequence type/parameters, coil sensitivity/filling factor, coil tuning/matching drift, etc. Since little is known about which forms of gadolinium are present (speciation), signal intensities, or changes thereof, will not reflect true changes in gadolinium content (McDonald, 2018; Quattrocchi, 2019).

#### *Preclinical studies*

Preclinical studies in rat brains have highlighted the importance of in vivo dechelation of Gd<sup>3+</sup> ions from less stable GBCAs, regardless of the presence of a renal dysfunction and with a clear dose-effect relationship. All quantities were in the nmol per gram tissue range. They have also shown that differences exist in the amount of total gadolinium retained in the brain when comparing different GBCA compounds (Jost, 2016; Robert, 2015 and 2017; Smith, 2017).

To date it is unclear what forms are responsible for the T<sub>1</sub>w signal increase (gadolinium speciation). Recently, it was shown that for gadolinium in the rat brain 3 different chemical forms must be distinguished: intact chelate, gadolinium bound to macromolecules, and insoluble gadolinium salts (Frenzel, 2017). The intact chelates were found for both linear and macrocyclic GBCA, but the other forms only for linear GBCA. As precipitated gadolinium does not induce any change in MRI signal when excited, it is likely that the gadolinium bound to macromolecules is responsible for the visible T<sub>1</sub>w hyperintensity in clinical MRI (Gianolio, 2017).

Well-conducted long-term animal studies demonstrated that for linear GBCA a large portion of gadolinium was retained in the brain, with binding of soluble gadolinium to macromolecules. For macrocyclic GBCA only traces of the intact chelated gadolinium were present with complete washout in time (Jost, 2019; Robert, 2018).

Intact GBCA does not cross the intact blood-brain barrier. It is now believed that GBCA can reach the CSF via the choroid plexus and ciliary body and can reach the brain interstitium via the glymphatic system along perineural sheaths and perivascular spaces of penetrating cortical arteries. GBCA distributed into the cerebrospinal fluid cavity via the glymphatic system may remain in the eye or brain tissue for a longer duration compared to the GBCA in systemic circulation. The glymphatic system may be responsible for deposition in linear GBCA as well as for GBCA clearance (Deike-Hofmann, 2019; Taoka, 2018).

### B. Gadolinium Deposition in the Body

Most data mentioned below are all from preclinical studies in animals.

#### *Gadolinium deposition in bone*

Lanthanide metals (gadolinium, samarium, europium, and cerium) have long been known to deposit in bone tissue and have effects on osteoblasts and osteoclasts, but the exact mechanisms are not yet well understood (Vidaud, 2012).

Gadolinium deposits have been found in samples of bone tissues of humans at higher concentrations than in brain tissue after administration of linear and macrocyclic GBCA,

whereby linear GBCA deposit 4 to 25 times more than macrocyclic GBCA (Darrah, 2009; Murata, 2016; White, 2006; Wang, 2015).

The bone residence time for macrocyclic GBCA (up to 30 days) is much shorter than for linear GBCA (up to 8 years) (Darrah, 2009; Lancelot, 2016). Bone may serve as a storage compartment from which Gd is later released in the body (Thakral, 2007). It is postulated that the long-term reservoir of gadolinium in bones might implicate that some patients with high bone turnover, such as menopausal women and patients with osteoporosis may be more vulnerable to gadolinium deposition (Darrah, 2009).

#### *Gadolinium deposition in skin*

Gadolinium depositions in skin have been demonstrated ever since the association of GBCA with nephrogenic systemic fibrosis in 2006. See also section on NSF.

In skin biopsies of NSF patients, gadolinium was found along collagen bundles but also as insoluble apatite-like deposits, suggesting dechelation (Sieber, 2009; Thakral, 2009). After linear GBCA, gadolinium deposits were found up to 40-180 times more frequently than after macrocyclic GBCA, histologic changes are more extensive, and products of dechelation of GBCA can be found (Haylor, 2012; Wang, 2015).

Recently, gadolinium has also been found in the skin of patients with normal renal function after high cumulative GBCA doses (Roberts, 2016). With normal renal function even a case of 'gadolinium-associated plaques' has been described, which suggest that gadolinium deposition in the skin after linear GBCA might give clinically relevant symptoms (Gathings, 2015).

#### *Gadolinium deposition in other organs*

Thus far, little is published about the effects of gadolinium deposition in other organs.

In a clinical study in the liver, gadolinium deposits have been associated with iron overload in the livers of paediatric stem cell transplantation patients with normal renal function, reacting well to iron dechelation therapy (Maximova, 2016).

Based on animal studies, it has been suggested that residual Gd is also present in tissues samples of kidney, liver, spleen, and testis (Celiker, 2018 and 2019; Di Gregorio, 2018; McDonald, 2017; Mercantepe, 2018; Tweedle, 1995; Wang, 2015) While deposition in the brain was only 2 to 7 µg Gd, the amounts in other organs varied 168 to 2134 µg Gd for kidney, 16 to 388 µg Gd for liver, and 18 to 354 µg Gd for spleen, all per gram of tissue. In all tissues the level was highest for the linear GBCA gadodiamide (McDonald, 2017).

#### *Self-reported clinical symptoms*

Thus far, gadolinium deposition has not been associated with clinical symptoms, except for NSF. Small online gadolinium toxicity support groups in USA have claimed that their members have manifested symptoms analogous to NSF and have prolonged excretion of Gd in urine following administration of GBCA. Surveys have shown variable symptoms that occur either directly or within 6 weeks of GBCA administration. Most reported symptoms are burning sensation and bone pain in lower arms and limbs, central torso pain, headache with vision/hearing changes, and skin thickening and discoloration (Burke, 2016; Semelka, 2016).

This complex of symptoms was coined "gadolinium deposition disease (GDD)". The critical findings are the presence of gadolinium in the body beyond 30 days, combined with at least



3 of the following features, with onset after the administration of GBCA: i) central torso pain, ii) headache and clouded mentation, iii) peripheral leg and arm pain, iv) peripheral leg and arm thickening and discoloration, and v) bone pain (Semelka, 2016).

Significant differences in gadolinium levels in bone and urine have been observed between individuals experiencing symptoms and those who are not (Lord, 2018). A large study with a control population found more new symptoms within 24 h after exposure to GBCA than after unenhanced MRI. From the GDD-like symptoms, only fatigue and mental confusion were more frequently reported after enhanced MRI, questioning the term GDD (Parillo, 2019).

### **III The European Medicines Agency (EMA) ruling**

In many European countries, the described association between NSF and exposure to linear GBCAs in 2006 has resulted in the fact that most hospitals switched early (2007 and onwards) to macrocyclic GBCA use only, in most cases gadoterate or gadobutrol. After the series of publications describing increased signal intensities in the brain nuclei on unenhanced T1-weighted imaging after multiple linear GBCA exposures and post-mortem studies revealing the presence of small amounts of gadolinium in neural tissues, the EMA instituted an article 31 procedure. Eventually, this led to the withdrawal of EU market authorizations of the high-risk linear GBCA gadodiamide and gadoversetamide, as well as restrictions on the use of gadopentetate (MR Arthrography only) and, gadobenate (liver imaging only) (Dekkers, 2018; EMA, 2017). Therefore, for general use in MRI only macrocyclic GBCA are available, while the linear GBCA gadoxetate and gadobenate are available for liver-specific MRI.

Gadolinium metabolism and deposition still has many knowledge gaps for which an international research agenda is important. The ACR/NIH/RSNA Meeting 2018 has made a good inventory where future research should be aimed at (McDonald, 2018).

### **Literature**

- Aime S, Caravan P. Biodistribution of gadolinium-based contrast agents, including gadolinium deposition. *J Magn Reson Imaging* 2009; 30: 1259-1267.
- Balzer T. Presence of gadolinium (Gd) in the brain and body. Presentation to the Medical Imaging Drugs Advisory Committee, FDA. Silver Spring, MD: U.S. Food and Drug Administration, 2017.
- Bellin MF, Van Der Molen AJ. Extracellular gadolinium-based contrast media: an overview. *Eur J Radiol* 2008; 66: 160-167.
- Burke LM, Ramalho M, Al Obaidy M, Chang E, Jay M, Semelka RC. Self-reported gadolinium toxicity: a survey of patients with chronic symptoms. *Magn Reson Imaging* 2016; 34: 1078-1080.
- Caravan P, Ellison J, McMurry TJ, Lauffer RB. Gadolinium (III) chelates as MRI contrast agents: structure, dynamics and applications. *Chem Rev* 1999; 99: 2293–2352.
- Çeliker FB, Tumkaya L, Mercantepe T, Beyazal M, Turan A, Beyazal Polat H, et al. Effects of gadodiamide and gadoteric Acid on rat kidneys: A comparative study. *J Magn Reson Imaging* 2019; 49: 382-389.
- Darrah TH, Prutsman-Pfeiffer JJ, Poreda RJ, Ellen Campbell M, Hauschka PV, Hannigan RE. Incorporation of excess gadolinium into human bone from medical contrast agents. *Metallomics* 2009; 1: 479-488.

- De Kerviler E, Maravilla K, Meder JF, Naggara O, Dubourdieu C, Jullien V, et al. Adverse reactions to gadoterate meglumine: review of over 25 years of clinical use and more than 50 million doses. *Invest Radiol* 2016; 51: 544-551.
- De León-Rodríguez LM, Martins AF, Pinho MC, Rofsky NM, Sherry AD. Basic MR relaxation mechanisms and contrast agent design. *J Magn Reson Imaging* 2015; 42: 545-565.
- Deike-Hofmann K, Reuter J, Haase R, Paech D, Gnirs R, Bickelhaupt S, et al. Glymphatic pathway of gadolinium-based contrast agents through the brain: overlooked and misinterpreted. *Invest Radiol* 2019; 54: 229-237.
- Dekkers IA, Roos R, van der Molen AJ. Gadolinium retention after administration of contrast agents based on linear chelators and the recommendations of the European Medicines Agency. *Eur Radiol* 2018; 28: 1579–1584.
- Di Gregorio E, Ferrauto G, Furlan C, Lanzardo S, Nuzzi R, Gianolio E, et al. The issue of gadolinium retained in tissues insights on the role of metal complex stability by comparing metal uptake in murine tissues upon the concomitant administration of lanthanum- and gadolinium-diethylene-triaminopenta-acetate. *Invest Radiol* 2018; 53: 167–172.
- Elster AD. T1 shortening by Gad. Available at: [\[URL\]](#). Accessed: 15. April 2022.
- Endrikat J, Dohanish S, Schleyer N, Schwenke S, Agarwal S, Balzer T. 10 years of nephrogenic systemic fibrosis: a comprehensive analysis of nephrogenic systemic fibrosis reports received by a pharmaceutical company from 2006 to 2016. *Invest Radiol* 2018; 53: 541-550.
- Errante Y, Cirimele V, Mallio CA, Di Lazzaro V, Zobel BB, Quattrocchi CC. Progressive increase of T1 signal intensity of the dentate nucleus on unenhanced magnetic resonance images is associated with cumulative doses of intravenously administered gadodiamide in patients with normal renal function, suggesting dechelation. *Invest Radiol* 2014; 49: 685-690.
- European Medicines Agency. EMA's final opinion confirms restrictions on use of linear gadolinium agents in body scans (21 July 2017). Available at: [\[URL\]](#). Accessed: 15 April 2022.
- Frenzel T, Lengsfeld P, Schirmer H, Hütter J, Weinmann HJ. Stability of gadolinium-based magnetic resonance imaging contrast agents in human serum at 37° C. *Invest Radiol* 2008; 43: 817-828.
- Frenzel T, Apte C, Jost G, Schöckel L, Lohrke J, Pietsch H. Quantification and assessment of the chemical form of residual gadolinium in the brain after repeated administration of gadolinium-based contrast agents: comparative study in rats. *Invest Radiol* 2017; 52: 396-404.
- Gathings RM, Reddy R, Santa Cruz D, Brodell RT. Gadolinium-associated plaques: a new, distinctive clinical entity. *JAMA Dermatol* 2015; 151: 316-319.
- Gianolio E, Bardini P, Arena F, Rachel S, Di Gregorio E, Iani R, et al. Gadolinium retention in the rat brain: assessment of the amounts of insoluble gadolinium-containing species and intact gadolinium complexes after repeated administration of gadolinium-based contrast agents. *Radiology* 2017; 285: 839–849.
- Hao D, Ai T, Goerner F, Hu X, Runge VM, Tweedle M. MRI contrast agents: basic chemistry and safety. *J Magn Reson Imaging* 2012; 36: 1060–1071.
- Idée JM, Port M, Raynal I, Schaefer M, Le Greneur S, Corot C. Clinical and biological consequences of transmetallation induced by contrast agents for magnetic resonance imaging: a review. *Fundam Clin Pharmacol* 2006; 20: 563–576.
- Idée JM, Fretellier N, Robic C, Corot C. The role of gadolinium chelates in the mechanism of nephrogenic systemic fibrosis: A critical update. *Crit Rev Toxicol* 2014; 44: 895-913.
- Joffe P, Thomsen HS, Meusel M. Pharmacokinetics of gadodiamide injection in patients with severe renal insufficiency and patients undergoing hemodialysis or continuous

- ambulatory peritoneal dialysis. *Acad Radiol* 1998; 5: 491–502.
- Jost G, Lenhard DC, Sieber MA, Lohrke J, Frenzel T, Pietsch H. Signal increase on unenhanced T1-weighted images in the rat brain after repeated, extended doses of gadolinium-based contrast agents: comparison of linear and macrocyclic agents. *Invest Radiol* 2016; 51: 83–89.
- Jost G, Frenzel T, Lohrke J, Lenhard DC, Naganawa S, Pietsch H. Penetration and distribution of gadolinium-based contrast agents into the cerebrospinal fluid in healthy rats: A potential pathway of entry into the brain. *Eur Radiol* 2017; 27:2877–2885.
- Jost G, Frenzel T, Boyken J, Lohrke J, Nischwitz V, Pietsch H. Long-term excretion of gadolinium-based contrast agents: linear versus macrocyclic agents in an experimental rat model. *Radiology* 2019; 290: 340-348.
- Kanal E. Gadolinium based contrast agents (GBCA): Safety overview after 3 decades of clinical experience. *Magn Reson Imaging* 2016; 34: 1341–1345.
- Kanda T, Ishii K, Kawaguchi H, Kitajima K, Takenaka D. High signal intensity in the dentate nucleus and globus pallidus on unenhanced T1-weighted MR images: relationship with increasing cumulative dose of a gadolinium-based contrast material. *Radiology* 2014; 270: 834-841.
- Lancelot E. Revisiting the pharmacokinetic profiles of gadolinium-based contrast agents. *Invest Radiol* 2016; 51: 691-700.
- Le Fur M, Caravan P. The biological fate of gadolinium-based MRI contrast agents: a call to action for bioinorganic chemists. *Metallomics* 2019; 11: 240-254.
- Lin SP, Brown JJ. MR contrast agents: physical and pharmacologic basics. *J Magn Reson Imaging* 2007; 25: 884–899.
- Lohrke J, Frenzel T, Endrikat J, Alves FC, Grist TM, Law M, et al. 25 years of contrast-enhanced MRI: developments, current challenges and future perspectives. *Adv Ther* 2016; 33: 1–28.
- Maximova N, Gregori M, Zennaro F, Sonzogni A, Simeone R, Zanon D. Hepatic gadolinium deposition and reversibility after contrast agent-enhanced MR imaging of pediatric hematopoietic stem cell transplant recipients. *Radiology* 2016; 281: 418-426.
- McDonald RJ, McDonald J, Kallmes D, Jentoft ME, Murray DL, Thielen KR, et al. Intracranial gadolinium deposition after contrast-enhanced MR imaging. *Radiology* 2015; 275: 772-782.
- McDonald RJ, McDonald JS, Dai D, Schroeder D, Jentoft ME, Murray DL, et al. Comparison of gadolinium concentrations within multiple rat organs after intravenous administration of linear versus macrocyclic gadolinium chelates. *Radiology* 2017; 285: 536-545.
- McDonald RJ, Levine D, Weinreb J, Kanal E, Davenport MS, Ellis JH, et al. Gadolinium retention: a research roadmap from the 2018 NIH/ACR/RSNA workshop on gadolinium chelates. *Radiology* 2018; 289: 517-534.
- Mercantepe T, Tümkaya L, Çeliker FB, Topal Suzan Z, Çınar S, Akyıldız K, et al. Effects of gadolinium-based MRI contrast agents on liver tissue. *J Magn Reson Imaging* 2018; 48: 1367-1374.
- Murata N, Gonzalez-Cuyar LF, Murata K, Fligner C, Dills R, Hippe D, et al. Macrocyclic and other non-group 1 gadolinium contrast agents deposit low levels of gadolinium in brain and bone tissue. *Invest Radiol* 2016; 51: 447-453
- Port M, Idee JM, Medina C, Robic C, Sabatou M, Corot C. Efficiency, thermodynamic and kinetic stability of marketed gadolinium chelates and their possible clinical consequences: a critical review. *Biometals* 2008; 21: 469–490
- Parillo M, Sapienza M, Arpaia F, Magnani F, Mallio CA, D’Alessio P, et al. A structured survey on adverse events occurring within 24 hours after intravenous exposure to

- gadodiamide or gadoterate meglumine: a controlled prospective comparison study. *Invest Radiol* 2019; 54: 191-197.
- Pietsch H, Lengsfeld P, Jost G, Frenzel T, Hütter J, Sieber MA. Long-term retention of gadolinium in the skin of rodents following the administration of gadolinium-based contrast agents. *Eur Radiol* 2009; 19: 1417-1424.
- Pullicino R, Radon M, Biswas S, Bhojak M, Das K. A Review of the Current evidence on gadolinium deposition in the brain. *Clin Neuroradiol* 2018; 28: 159-169.
- Quattrocchi CC, Ramalho J, van der Molen AJ, Rovira À, Radbruch A; GREC, European Gadolinium Retention Evaluation Consortium and the ESNR, European Society of Neuroradiology. Standardized assessment of the signal intensity increase on unenhanced T1-weighted images in the brain: the European Gadolinium Retention Evaluation Consortium (GREC) Task Force position statement. *Eur Radiol* 2019.
- Radbruch A, Weberling LD, Kieslich PJ, et al. High-signal intensity in the dentate nucleus and globus pallidus on unenhanced T1-weighted images: evaluation of the macrocyclic gadolinium-based contrast agent gadobutrol. *Invest Radiol* 2015; 50: 805–810.
- Radbruch A, Haase R, Kieslich PJ, Weberling LD, Kickingereder P, Wick W, et al. No signal intensity increase in the dentate nucleus on unenhanced T1-weighted MR images after more than 20 serial injections of macrocyclic gadolinium-based contrast agents. *Radiology* 2017; 282: 699-707.
- Ramalho J, Semelka RC, Al-Obaidy M, Ramalho M, Nunes RH, Castillo M. Signal intensity change on unenhanced T1-weighted images in dentate nucleus following gadobenate dimeglumine in patients with and without previous multiple administrations of gadodiamide. *Eur Radiol* 2016; 26: 4080–4088.
- Robert P, Lehericy S, Grand S, Violas X, Fretellier N, Idée JM, Ballet S, Corot C. T1-weighted hypersignal in the deep cerebellar nuclei after repeated administrations of gadolinium-based contrast agents in healthy rats: difference between linear and macrocyclic agents. *Invest Radiol* 2015; 50: 473-480.
- Robert P, Violas X, Grand S, Lehericy S, Idée JM, Ballet S, Corot C. Linear gadolinium-based contrast agents are associated with brain gadolinium retention in healthy rats. *Invest Radiol* 2016; 51: 73-82.
- Robert P, Frenzel T, Factor C, et al. Methodological aspects for preclinical evaluation of gadolinium presence in brain tissue: critical appraisal and suggestions for harmonization. A joint initiative. *Invest Radiol* 2018; 53: 499–517.
- Robert P, Fingerhut S, Factor C, Vives V, Letien J, Sperling M, et al. One-year retention of gadolinium in the brain: comparison of gadodiamide and gadoterate meglumine in a rodent model. *Radiology* 2018; 288: 424–433.
- Roberts DR, Lindhorst SM, Welsh CT, Maravilla KR, Herring MN, Braun KA, et al. High levels of gadolinium deposition in the skin of a patient with normal renal function. *Invest Radiol* 2016; 51: 280-289.
- Rogosnitzky M, Branch S. Gadolinium-based contrast agent toxicity: a review of known and proposed mechanisms. *Biometals* 2016; 29: 365–376.
- Rohrer M, Bauer H, Mintorovitch J, Requard M, Weinmann HJ. Comparison of magnetic properties of MRI contrast media solutions at different field strengths. *Invest Radiol* 2005; 40: 715–724.
- Semelka RC, Ramalho J, Vakharia A, Al Obaidy M, Burke LM, Jay M, et al. Gadolinium deposition disease: Initial description of a disease that has been around for a while. *Magn Reson Imaging* 2016; 34: 1383-1390.
- Sieber MA, Lengsfeld P, Frenzel T, Golfier S, Schmitt-Willich H, Siegmund F, et al. Preclinical investigation to compare different gadolinium-based contrast agents regarding their propensity to release gadolinium in vivo and to trigger nephrogenic systemic fibrosis-like lesions. *Eur Radiol* 2008; 18: 2164-2173.

- Smith AP, Marino M, Roberts J, Crowder JM, Castle J, Lowery L, Morton C, Hibberd MG, Evans PM. Clearance of gadolinium from the brain with no pathologic effect after repeated administration of gadodiamide in healthy rats: an analytical and histologic study. *Radiology* 2017; 282: 743-751.
- Taoka T, Naganawa S. Gadolinium-based contrast media, cerebrospinal fluid and the lymphatic system: possible mechanisms for the deposition of gadolinium in the brain. *Magn Reson Med Sci* 2018; 17: 111-119.
- Thakral C, Alhariri J, Abraham JL. Long-term retention of gadolinium in tissues from nephrogenic systemic fibrosis patient after multiple gadolinium-enhanced MRI scans: case report and implications. *Contrast Media Mol Imaging* 2007; 2: 199-205.
- Thakral C, Abraham JL. Nephrogenic systemic fibrosis: histology and gadolinium detection. *Radiol Clin North Am* 2009; 47: 841-853.
- Thomsen HS. Nephrogenic systemic fibrosis: A serious late adverse reaction to gadodiamide. *Eur Radiol* 2006; 16: 2619–2621.
- Thomsen HS, Marckmann P. Extracellular GBCA: differences in prevalence of NSF. *Eur J Radiol* 2008; 66: 180-183.
- Thomsen HS, Morcos SK, Almén T, et al. Nephrogenic systemic fibrosis and gadolinium-based contrast media: updated ESUR Contrast Medium Safety Committee guidelines. *Eur Radiol* 2013; 23: 307-318.
- Tweedle MF, Wedeking P, Kumar K. Biodistribution of radiolabeled, formulated gadopentetate, gadoteridol, gadoterate, and gadodiamide in mice and rats. *Invest Radiol* 1995; 30: 372-380.
- Vidaud C, Bourgeois D, Meyer D. Bone as target organ for metals: the case of f-elements. *Chem Res Toxicol* 2012; 25: 1161-1175.
- Wahsner J, Gale EM, Rodríguez-Rodríguez A, Caravan P. Chemistry of MRI contrast agents: current challenges and new frontiers. *Chem Rev.* 2018 Oct 16. doi: 10.1021/acs.chemrev.8b00363.
- Wang YX, Schroeder J, Siegmund H, Idée JM, Fretellier N, Jestin-Mayer G, et al. Total gadolinium tissue deposition and skin structural findings following the administration of structurally different gadolinium chelates in healthy and ovariectomized female rats. *Quant Imaging Med Surg* 2015; 5: 534-545.
- White GW, Gibby WA, Tweedle MF. Comparison of Gd(DTPA-BMA) (Omniscan) versus Gd(HP-DO3A) (ProHance) relative to gadolinium retention in human bone tissue by inductively coupled plasma mass spectroscopy. *Invest Radiol* 2006; 41: 272-278.

**For Further Reading: Recent Guidelines:**

- American College of Radiology. ACR Manual on contrast media, v2022. Available at: [\[URL\]](#). Accessed: 7. June 2022.
- European Society of Urogenital Radiology Contrast Media Safety Committee. ESUR Guidelines on contrast safety, v10. Available at: [\[URL\]](#). Accessed: 7. June 2022.
- Costa AF, van der Pol CB, Maralani PJ, McInnes MDF, Shewchuk JR, Verma R, et al. Gadolinium deposition in the brain: a systematic review of existing guidelines and Policy Statement issued by the Canadian Association of Radiologists. *Can Assoc Radiol J* 2018; 69: 373-382.

## Module 9.1 Gadolinium Deposition in the Brain and Body

This is an update of module 8 in the previous guideline [Safe Use of Contrast Media, part 2](#).

### Clinical question

What is the effect of gadolinium deposition in the brain and body?

### Introduction

In 2014, progressive unenhanced T<sub>1</sub>-weighted (T<sub>1</sub>w) signal intensity (SI) increases in the dentate nucleus (DN) and globus pallidus GP in patients who received at least 6 doses of linear GBCA were observed (Kanda, 2014). This publication triggered a huge amount of research on this subject, but so far, no clinical correlates of gadolinium deposition have been found. In this module a narrative review of the recent data (2019-2022) on gadolinium deposition in the brain and body organs is presented. Recommendations for a sensible use of gadolinium in diagnostic MRI will be given to limit potential effects of gadolinium deposition that may not be known at the present date.

### Search and select

For this chapter it was decided not to perform a systematic literature analysis, and therefore no search question with PICO was formulated.

### Search and select (Methods)

No systematic literature analysis was performed. Instead, the authors made an overview of all available literature from their own database and through cross referencing. A narrative literature analysis can be found below.

### Systematic literature analysis

For this chapter it was decided not to perform a systematic literature analysis.

### Justifications – from evidence to decision

### Narrative literature analysis (see also [Introduction](#))

#### Gadolinium Deposition in the Brain – Extracellular Linear GBCA

The use of linear extracellular GBCA led to visible changes in signal intensity (SI) ratios and measurable Gd depositions in the rat, dog, and human brain (Davies, 2021; De Bevist, 2020; El Hamrani, 2020; Fretellier, 2019; Grahl, 2021; Koiso, 2019; Minaeva, 2020; Richter, 2020; Wang, 2019a) and in the anterior pituitary gland (Mallio, 2019). Most depositions were in perivascular foci in the DN and GP (Davies 2021), with evidence of co-localization to parenchymal iron (Minaeva, 2020).

The amount of deposition in rat brains occurred independent of age or sex (Fretellier, 2019). Local blood-brain barrier disruptions (e.g., radiotherapy) did not lead to an increase in deposition (Jost, 2019). Active inflammation showed higher Gd concentration in inflamed areas in mouse brains (Wang, 2019a), while the presence of diabetes led to lower brain concentrations (Wang, 2019b). There was a decrease in concentration over time in all brain regions, but long-term retention over 1 year occurred preferentially in the rat DN (El Hamrani, 2020).

The use of intra-articular gadopentetate did not lead to visible Gd-deposition in human brains (Bunnell, 2021).

#### *Gadolinium Deposition in the Brain – Hepatobiliary Linear GBCA*

The use of linear GBCA such as gadobenate and gadoxetate has been limited in the EU to hepatobiliary MRI indications. The approved standard dose of gadobenate is 0.05 mmol/kg, less than the dose of linear extracellular GBCA. However, outside the EU gadobenate is used for total body indications, in doses up to 0.1 mmol/kg. Use of gadobenate led to visible SI changes in human brain (Barisano, 2019; Nguyen, 2020). Neuroinflammation led to higher Gd concentrations in the rat brain after gadobenate use (Damme, 2020).

In human cadavers, the mean Gd concentration in brain was 3-6x higher for gadobenate compared to gadoterate, but washed out over time (Kobayashi, 2021). In sheep, the level of Gd retention 10 weeks after a single dose injection was 14-fold higher for gadobenate than for gadoterate (Radbruch, 2019).

A meta-analysis on Gd deposition of gadoxetate showed significant bias of the 5 included studies, and therefore presently available data on gadolinium deposition for gadoxetate is still incomplete (Schieda, 2020).

#### *Gadolinium Deposition in the Brain – Macrocyclic GBCA*

The administration of cumulative doses of macrocyclic GBCA did not lead to visible changes in T1 signal intensity (SI) or to changes in T1 relaxation times in rat and human brains in most studies (Bennani-Baiti, 2019; Deike-Hoffmann, 2019, Forslin, 2019, Fretellier, 2019, Hannoun, 2020; Neal, 2020), but not in all (Splendiani, 2020).

Quantitative susceptibility mapping showed a relation of susceptibility changes with the number of gadobutrol injections, but only for the GP (Choi, 2020).

In rat brains macrocyclic GBCA led to measurable Gd concentrations 1-5 weeks after administration, which were lower for gadoteridol compared to gadoterate and gadobutrol. The GBCA wash-out over time led to a 3-5-fold reduction from 1 to 5 weeks and was more rapid for gadoteridol. The levels at 5 weeks were in the order of 0.14-0.30 nmol Gd/g tissue (Bussi, 2020 and 2021).

#### *Speciation of Gadolinium deposition in the brain*

In speciation analyses in rat brains, the macrocyclic GBCA gadoterate was present exclusively as the intact GBCA. For the linear GBCA gadobenate and gadodiamide a combination of intact GBCA, complexes of dissociated  $Gd^{3+}$  bound to ferritin, and  $Gd^{3+}$  bound to other macromolecules was present. Incomplete column recovery suggested presence of labile complexes of dissociated  $Gd^{3+}$  with endogenous molecules. In addition, Gd was present in insoluble amorphous spheroid structures of 100-200 nm. Gadolinium was consistently co-localized with calcium, phosphate, and oxygen, suggesting the structures composed of mixed Gd/Ca-phosphates (Strzeminska, 2021 and 2022).

#### *Gadolinium Deposition in the Abdominal Organs*

Like in the brain, administration of linear GBCA led to increased Gd concentrations in abdominal organs, like kidney and liver. In sheep, concentrations were 3-21x higher than for macrocyclic GBCA: for kidney 502 vs. 86 ng/g tissue, for liver 445 vs 21 ng/g tissue, and for spleen 72 vs 4 ng/g tissue. Gadodiamide concentrations were 879, 780 and 137 ng/g, gadobenate concentrations 179, 157 and 16 ng/g, and gadobutrol 86, 35 and 6 ng/g tissue, respectively. However, no tissue alterations were detected (Richter, 2021).

In the abdominal organs Gd was least retained after administration of gadoxetate, followed by gadobutrol and gadodiamide when clinically recommended doses were administered. Most of the retained gadolinium was excreted within 4 weeks after GBCA administration (Oh, 2020).

Administration of macrocyclic GBCA led to measurable Gd concentrations in liver and kidney 4 weeks after administration, which were lower for gadoteridol compared to gadoterate and gadobutrol. The levels for liver ranged 0.36-1.22 nmol Gd/g tissue and for kidney 39-294 nmol Gd/g tissue (Bussi, 2020 and 2021).

#### *Gadolinium Deposition in the Bone and Skin*

In rat skin, macrocyclic GBCA led to measurable Gd concentrations 1-5 weeks after administration, which were lower for gadoteridol compared to gadoterate and gadobutrol. The levels in skin were initially high, but after washout levels at 5 weeks were in the order of 0.31-0.53 nmol Gd/g tissue (Bussi, 2020 and 2021).

In human cadavers, 80 days after last GBCA exposure the mean Gd concentration in bone and skin was 2.9-4.4x higher for gadobenate compared to gadoterate. Bone was the primary Gd retention site with levels of 23-100 ng/g tissue/mmol GBCA. Gadolinium elimination rate was high for skin (Kobayashi, 2021).

#### *Potential clinical symptoms of Gd deposition*

Despite the retention of Gd in various tissues, no histopathologic changes in rat brains could be found (Ayers-Ringler 2022), nor tissue alterations in MS patients (Kühn, 2022).

In addition, no effect on sensorimotor or behavioural functions could be demonstrated for either linear or macrocyclic GBCA in mice (Akai 2021) or humans (Vymazal, 2020). Gadolinium retention was not related to symptom worsening in relapsing MS patients (Cocozza, 2019).

However, for linear GBCA, pain hypersensitivity has been seen in rats (Alkhunizi, 2020). In MS patients, increased relaxation was associated with lower information-processing speed (Forslin, 2019) or may result in mild effects on cerebellar speech or verbal fluency (Forslin, 2019; Kühn, 2022).

#### *Self-reported symptoms of gadolinium deposition*

The ACR Committee on Drugs and Contrast Media has suggested alternative nomenclature for patients with a spectrum of self-reported symptoms and signs. These include neurologic, cognitive, musculoskeletal, and other non-specific complaints, and different cytokine levels. They suggest terming these Symptoms Associated with Gadolinium Exposure (SAGE), to standardize reporting. SAGE will need to replace older terms such as gadolinium deposition



disease (GDD), gadolinium storage disease (GSD), and gadolinium storage condition (GSC) (McDonald, 2022).

In a clinical toxicology assessment of patients with potential 'Gd toxicity', none of the reported symptoms were likely to be caused by GBCA exposure (Layne, 2021).

SAGE patients may differ from normal controls in the level of cytokines and may differ in the response to chelation therapy. This suggests inflammatory, immunologic, or other physiological differences in patients with SAGE (Maecker, 2021).

#### Chelation therapy for Gadolinium deposition

Several chelating agents may influence the distribution of gadolinium after administration of linear GBCA (Acar, 2019). In rats, the chelating agent Ca-DTPA could induce a relevant urinary Gd excretion and reduce the amount of Gd in brain, but only after administration of gadodiamide (Boyken, 2019). In a study of SAGE patients Ca-DTPA could significantly increase urinary Gd excretion (Maecker, 2021). In contrast, Zn-DTPA administration could show no benefit of chelation therapy in rats after linear GBCA (Prybylski, 2019).

In patients with self-reported symptoms, there is no evidence that supports a link between gadolinium deposition and the development of clinical sequelae in patients with normal renal function. Caution should be exercised to use inappropriate chelation therapies for treatment of SAGE (Layne, 2020).

### **Recommendations**

*Disclaimer: Most recommendations in this module focus not so much on actions to be taken, but rather to increase awareness of gadolinium deposition.*

To date, even though there is evidence that gadolinium is deposited in tissues, there is no evidence of clinical symptoms nor harm associated with gadolinium deposition in the brain and body.

Ensure a strict indication for gadolinium-enhanced MRI and only use EMA-approved gadolinium-based contrast agents in all patients to minimize possible gadolinium deposition.

\*See also [module 9.2 Strategies for Dose Reduction of Gadolinium-Based Contrast Agents](#)

This guideline committee supports the ACR Committee on Drugs and Contrast Media's suggested terminology of Symptoms Associated with Gadolinium Exposure (SAGE) for self-reported symptoms and signs.

## Literature

- Acar T, Kaya E, Yoruk MD, Duzenli N, Senturk RS, Can C, et al. Changes in tissue gadolinium biodistribution measured in an animal model exposed to four chelating agents. *Jpn J Radiol.* 2019; 37(6): 458-465.
- Akai H, Miyagawa K, Takahashi K, Mochida-Saito A, Kurokawa K, Takeda H, et al. Effects of gadolinium deposition in the brain on motor or behavioral function: A mouse model. *Radiology.* 2021; 301(2): 409-416.
- Alkhunizi SM, Fakhoury M, Abou-Kheir W, Lawand N. Gadolinium retention in the central and peripheral nervous system: implications for pain, cognition, and neurogenesis. *Radiology.* 2020; 297(2): 407-416.
- Ayers-Ringler J, McDonald JS, Connors MA, Fisher CR, Han S, Jakaitis DR, et al. Neurologic effects of gadolinium retention in the brain after gadolinium-based contrast agent administration. *Radiology.* 2022; 302(3): 676-683.
- Barisano G, Bigjahan B, Metting S, Cen S, Amezcua L, Lerner A, Toga AW, Law M. Signal hyperintensity on unenhanced T1-weighted brain and cervical spinal cord MR Images after multiple doses of linear gadolinium-based contrast agent. *AJNR Am J Neuroradiol.* 2019; 40(8): 1274-1281.
- Bennani-Baiti B, Krug B, Giese D, Hellmich M, Bartsch S, Helbich TH, Baltzer PAT. Evaluation of 3.0-T MRI brain signal after exposure to gadoterate meglumine in women with high breast cancer risk and screening breast MRI. *Radiology.* 2019; 293(3): 523-530.
- Boyken J, Frenzel T, Lohrke J, Jost G, Schütz G, Pietsch H. Impact of treatment with chelating agents depends on the stability of administered GBCAs: A comparative study in rats. *Invest Radiol.* 2019; 54(2): 76-82.
- Bunnell KM, Hemke R, Hussein JS, Torriani M, Huang SY, Bredella MA. Does MR arthrography cause intracranial gadolinium deposition? *Skeletal Radiol.* 2020; 49(7): 1051-1056.
- Bussi S, Coppo A, Celeste R, Fanizzi A, Fringuello Mingo A, et al. Macrocyclic MR contrast agents: evaluation of multiple-organ gadolinium retention in healthy rats. *Insights Imaging.* 2020; 11(1): 11.
- Bussi S, Coppo A, Bonafè R, Rossi S, Colombo Serra S, Penard L, et al. Gadolinium clearance in the first 5 weeks after repeated intravenous administration of gadoteridol, gadoterate meglumine, and gadobutrol to rats. *J Magn Reson Imaging.* 2021; 54(5): 1636-1644.
- Choi Y, Jang J, Kim J, Nam Y, Shin NY, Ahn KJ, et al. MRI and quantitative magnetic susceptibility maps of the brain after serial administration of gadobutrol: a longitudinal follow-up study. *Radiology.* 2020; 297(1): 143-150.
- Cocozza S, Pontillo G, Lanzillo R, Russo C, Petracca M, Di Stasi M, et al. MRI features suggestive of gadolinium retention do not correlate with Expanded Disability Status Scale worsening in multiple sclerosis. *Neuroradiology.* 2019; 61(2): 155-162.
- Davies J, Marino M, Smith APL, Crowder JM, Larsen M, Lowery L, et al. Repeat and single dose administration of gadodiamide to rats to investigate concentration and location of gadolinium and the cell ultrastructure. *Sci Rep.* 2021; 11(1): 13950.
- Damme NM, Fernandez DP, Wang LM, Wu Q, Kirk RA, Towner RA, et al. Analysis of retention of gadolinium by brain, bone, and blood following linear gadolinium-based contrast agent administration in rats with experimental sepsis. *Magn Reson Med.* 2020; 83(6): 1930-1939.
- DeBevits JJ 4th, Munbodh R, Bageac D, Wu R, DiCamillo PA, Hu C, et al. Gray matter nucleus hyperintensity after monthly triple-dose gadopentetate dimeglumine with long-term Magnetic Resonance Imaging. *Invest Radiol.* 2020; 55(10): 629-635.

- Deike-Hofmann K, Reuter J, Haase R, Kuder T, Paech D, Bickelhaupt S, et al. No changes in T1 relaxometry after a mean of 11 administrations of gadobutrol. *Invest Radiol.* 2020; 55(6): 381-386.
- El Hamrani D, Vives V, Buchholz R, Mème W, Factor C, Fingerhut S, et al. Effect of long-term retention of gadolinium on metabolism of deep cerebellar nuclei after repeated injections of gadodiamide in rats. *Invest Radiol.* 2020; 55(2): 120-128.
- Forslin Y, Martola J, Bergendal Å, Fredrikson S, Wiberg MK, Granberg T. Gadolinium retention in the brain: An MRI relaxometry study of linear and macrocyclic gadolinium-based contrast agents in multiple sclerosis. *AJNR Am J Neuroradiol.* 2019; 40(8): 1265-1273.
- Fretellier N, Granottier A, Rasschaert M, Grindel AL, Baudimont F, Robert P, et al. Does age interfere with gadolinium toxicity and presence in brain and bone tissues: A comparative gadoterate versus gadodiamide study in juvenile and adult rats. *Invest Radiol.* 2019; 54(2): 61-71.
- Grahl S, Bussas M, Pongratz V, Kirschke JS, Zimmer C, Berthele A, et al. T1-weighted intensity increase after a single administration of a linear gadolinium-based contrast agent in multiple sclerosis. *Clin Neuroradiol.* 2021; 31(1): 235-243.
- Hannoun S, Issa R, El Ayoubi NK, Haddad R, Baalbaki M, Yamout BI, et al. Gadoterate meglumine administration in multiple sclerosis has no effect on the dentate nucleus and the globus pallidus signal intensities. *Acad Radiol.* 2019; 26(10): e284-e291.
- Jost G, Frenzel T, Boyken J, Pietsch H. Impact of brain tumors and radiotherapy on the presence of gadolinium in the brain after repeated administration of gadolinium-based contrast agents: an experimental study in rats. *Neuroradiology.* 2019; 61(11): 1273-1280.
- Kanda T, Ishii K, Kawaguchi H, Ketajima K, Takenaka D. High signal intensity in the dentate nucleus and globus pallidus on unenhanced T1-weighted MR images: Relationship with increasing cumulative dose of a gadolinium-based contrast material. *Radiology* 2014; 270(3): 834–841.
- Kobayashi M, Levendovszky SR, Hippe DS, Hasegawa M, Murata N, Murata K, et al. Comparison of human tissue gadolinium retention and elimination between gadoteridol and gadobenate. *Radiology.* 2021; 300(3): 559-569.
- Koiso T, Yamamoto M, Watanabe S, Barfod BE. Signal intensity increases in dentate nucleus/globus pallidus/pulvinar on unenhanced T1WI MR images after multiple examinations with gadodiamide. *Neuroradiol J.* 2019; 32(3): 215-224.
- Kühn I, Maschke H, Großmann A, Hauenstein K, Weber MA, Zettl UK, et al. Dentate nucleus gadolinium deposition on magnetic resonance imaging: ultrasonographic and clinical correlates in multiple sclerosis patients. *Neurol Sci.* 2022; 43(4): 2631-2639.
- Layne KA, Wood DM, Dargan PI. Gadolinium-based contrast agents - what is the evidence for 'gadolinium deposition disease' and the use of chelation therapy? *Clin Toxicol* 2020; 58(3): 151-160.
- Layne KA, Raja K, Dargan PI, Wood DM. Gadolinium concentrations in biological matrices from patients exposed to gadolinium-based contrast agents. *Invest Radiol.* 2021; 56(7): 458-464.
- Maecker HT, Siebert JC, Rosenberg-Hasson Y, Koran LM, Ramalho M, Semelka RC. Acute chelation therapy-associated changes in urine gadolinium, self-reported flare severity, and serum cytokines in gadolinium deposition disease. *Invest Radiol.* 2021; 56(6): 374-384.
- Mallio CA, Messina L, Parillo M, Lo Vullo G, Beomonte Zobel B, et al. Anterior pituitary gland T1 signal intensity is influenced by time delay after injection of gadodiamide. *Sci Rep.* 2020; 10(1): 14967.

- McDonald RJ, Weinreb JC, Davenport MS. Symptoms Associated with Gadolinium Exposure (SAGE): A suggested term. *Radiology*. 2022; 302(2): 270-273.
- Minaeva O, Hua N, Franz ES, Lupoli N, Mian AZ, Farris CW, et al. Nonhomogeneous gadolinium retention in the cerebral cortex after intravenous administration of gadolinium-based contrast agent in rats and humans. *Radiology*. 2020; 294(2): 377-385.
- Neal CH, Pujara AC, Srinivasan A, Chenevert TL, Malyarenko D, Khalatbari S, et al. Prospective imaging trial assessing gadoteridol retention in the deep brain nuclei of women undergoing breast MRI. *Acad Radiol*. 2020; 27(12): 1734-1741.
- Nguyen NC, Molnar TT, Cummin LG, Kanal E. Dentate nucleus signal intensity increases following repeated gadobenate dimeglumine administrations: A retrospective analysis. *Radiology*. 2020; 296(1): 122-130.
- Oh H, Chung YE, You JS, Joo CG, Kim PK, Lim JS, et al. Gadolinium retention in rat abdominal organs after administration of gadoxetic acid disodium compared to gadodiamide and gadobutrol. *Magn Reson Med*. 2020; 84(4): 2124-2132.
- Prybylski JP, Coste Sanchez C, Jay M. Impact of chelation timing on gadolinium deposition in rats after contrast administration. *Magn Reson Imaging*. 2019; 55: 140-144.
- Radbruch A, Richter H, Fingerhut S, Martin LF, Xia A, Henze N, et al. Gadolinium deposition in the brain in a large animal model: Comparison of linear and macrocyclic gadolinium-based contrast agents. *Invest Radiol*. 2019; 54(9): 531-536.
- Richter H, Bücken P, Martin LF, Dunker C, Fingerhut S, Xia A, et al. Gadolinium tissue distribution in a large-animal model after a single dose of gadolinium-based contrast agents. *Radiology*. 2021; 301(3): 637-642.
- Richter H, Bücken P, Dunker C, Karst U, Kircher PR. Gadolinium deposition in the brain of dogs after multiple intravenous administrations of linear gadolinium-based contrast agents. *PLoS One*. 2020; 15(2): e0227649.
- Schieda N, van der Pol CB, Walker D, Tsampalieros AK, Maralani PJ, Woo S, et al. Adverse events to the gadolinium-based contrast agent gadoxetic acid: Systematic review and meta-analysis. *Radiology*. 2020; 297(3): 565-572.
- Splendiani A, Corridore A, Torlone S, Martino M, Barile A, Di Cesare E, et al. Visible T1-hyperintensity of the dentate nucleus after multiple administrations of macrocyclic gadolinium-based contrast agents: Yes, or no? *Insights Imaging*. 2019; 10(1): 82.
- Strzeminska I, Factor C, Robert P, Szpunar J, Corot C, Lobinski R. Speciation analysis of gadolinium in the water-insoluble rat brain fraction after administration of gadolinium-based contrast agents. *Invest Radiol*. 2021; 56(9): 535-544.
- Strzeminska I, Factor C, Jimenez-Lamana J, Lacomme S, Subirana MA, Le Coustumer P, et al. Comprehensive speciation analysis of residual gadolinium in deep cerebellar nuclei in rats repeatedly administered with gadoterate meglumine or gadodiamide. *Invest Radiol*. 2022; 57(5): 283-292.
- Vymazal J, Krámská L, Brožová H, Růžička E, Rulseh AM. Does serial administration of gadolinium-based contrast agents affect patient neurological and neuropsychological status? Fourteen-year follow-up of patients receiving more than fifty contrast administrations. *J Magn Reson Imaging*. 2020; 51(6): 1912-1913.
- Wang S, Hesse B, Roman M, Stier D, Castillo-Michel H, Cotte M, et al. Increased retention of gadolinium in the inflamed brain after repeated administration of gadopentetate dimeglumine: A proof-of-concept study in mice combining ICP-MS and micro- and nano-SR-XRF. *Invest Radiol*. 2019; 54(10): 617-626.
- Wang ST, Hua ZX, Fan DX, Zhang X, Ren K. Gadolinium retention and clearance in the diabetic brain after administrations of gadodiamide, gadopentetate dimeglumine, and gadoterate meglumine in a rat model. *Biomed Res Int*. 2019; 2019: 3901907.

## Module 9.2 Strategies for Dose Reduction of Gadolinium-Based Contrast Agents

*This is a new module about strategies for dose reduction of gadolinium-based contrast agents in Magnetic Resonance Imaging.*

### Clinical question

In which way can the dose of gadolinium-based contrast agents be reduced / minimized without compromising diagnostic accuracy?

The following categories were defined:

- I Potential dose-reduction strategies for neuroimaging with gadolinium-based contrast agents
- II Potential dose-reduction strategies for cardiovascular imaging with gadolinium-based contrast agents
- III Potential dose-reduction strategies for musculoskeletal imaging with gadolinium-based contrast agents
- IV Potential dose-reduction strategies for abdominal imaging with gadolinium-based contrast agents
- V Potential dose-reduction strategies for breast imaging with gadolinium-based contrast agents

### Introduction

There is an increasing interest in the reduction of the use of gadolinium-based contrast agents (GBCAs) for clinical safety reasons, environmental aspects, logistics, and health care costs. Two main strategies for the reduction of GBCAs are imaging by using a lower dose (e.g., half-dose imaging or lower) than the standard used dose of gadolinium (Gd) of 0.1 mmol/kg body weight for contrast-enhanced (CE) MRI, as well as leaving out GBCA in MRI scan protocols to answer specific clinical questions. Leaving out GBCA involves specific clinical scenarios for various organ systems, and such approaches are to be discussed further within multi-disciplinary expert panels.

### Systematic literature analysis

For this chapter it was decided not to perform a systematic literature analysis.

### Justifications – from evidence to decision

#### Narrative literature analysis

##### Gadolinium reduction strategies for neuroimaging

Most studies published on Gd reduction strategies are primarily focused on static contrast-enhanced (CE) T1-weighted (T1w) imaging. Several studies have compared the use of half-dose imaging (e.g., 0.05 mmol/kg body weight) to full dose (e.g., 0.1 mmol/kg body weight) imaging in neuro MRI protocols. Initial studies compared the diagnostic certainty of detecting brain metastasis for different doses of GBCA. These have shown that for spin-echo MR imaging high dose GBCA was an efficient way to improve the detection of brain metastases, in particular of small metastases (Åkeson, 1995). However, other studies in the same period showed that half dose imaging with magnetization transfer did not lead to significant differences in contrast enhancement for extra-axial tumours (e.g. meningiomas) upon visual inspection when compared with standard dose imaging (Haba, 2001; Han, 1998).

At 3.0 T half-dose imaging using gadopentetate has shown to yield in significantly higher contrast-to-noise ratio (1.3-fold higher) compared to full-dose imaging at 1.5 T (Krautmacher, 2005). However, it should be noted that the older studies addressing half dose imaging such as the 1995 study by Åkeson used linear GBCA's which are currently no longer available on the European Market because of suspended marketing authorizations due to the potential risk of gadolinium retention in the human body (Åkeson, 1995). This also applies to the study by Khoury Chalouhi et al. which performed an intraindividual and interindividual comparison between 0.075 mmol/kg and 0.1 mmol/kg of gadoterate meglumine for cranial MRI because of the higher relaxivity of this GBCA agent (Khoury Chalouhi, 2014). Also two recent studies evaluated the use of half dose imaging of the high-relaxivity linear GBCA gadobenate dimeglumine demonstrated that half dose compared to full dose imaging was non-inferior with regard to visual lesion delineation, internal morphology, and contrast enhancement at 1.5 T and 3.0 T (DeLano, 2021), and small or ring-enhancing metastases can be better visualized on half-dose gadobenate dimeglumine delayed CE T2 FLAIR for than on half dose CE-T1w brain MRI scans (Jin, 2021). It should be noted that the findings of studies on linear GBCA's cannot be extrapolated to the macrocyclic GBCAs that are currently used in neuroimaging because of the restricted use within the EU.

With regard to macrocyclic agents, the literature on reduced contrast dose is still limited and mainly based on the recent findings of the LEADER-75 trial. The LEADER-75 trial is an international prospective multicentre open-label crossover study that evaluated the use of three-quarter dose high-relaxivity gadobutrol (0.075 mmol/kg) compared with standard-dose gadoterate (0.1 mmol/kg) in adults with known or suspected CNS pathology undergoing CE brain imaging at 1.5T and 3T (Liu, 2021). Efficacy analysis in 141 patients found that improvement of reduced-dose gadobutrol over unenhanced images was noninferior to improvement of standard-dose gadoterate over unenhanced images. The authors used a 20% noninferiority margin for three primary efficacy measures using mean readings ( $p \leq 0.025$ ). The total number of lesions detected by mean reading was 301 for reduced-dose gadobutrol versus 291 for standard-dose gadoterate. The sensitivity (58.7%), specificity (91.8%), and accuracy (70.2%) for malignancy from majority reading were identical for reduced-dose gadobutrol and standard-dose gadoterate. No differences in mean reader confidence ( $3.3 \pm 0.6$  for both reduced-dose gadobutrol and standard-dose gadoterate) and reader preference were found (95% CI, -0.10 to 0.11). Albeit that the LEADER-75 trial is the first study to demonstrate convincing evidence for reduced dose imaging for macrocyclic GBCA in neuroimaging without compromising reader confidence and reader preference, there are several knowledge gaps that remain. These include the potential influence of field strength, the potential differences in CE in CNS pathologies that were underrepresented in the LEADER-75 sample (e.g. 41% of the sample consisted of meningiomas and 24% of metastases), and influence of sequence design and acquisition.

In addition to static CE-T1W for brain imaging, reduced dose imaging has also been investigated for brain perfusion using dynamic susceptibility contrast (DSC). In DSC half dose imaging has shown to lead to a more accurate arterial input function (Filice, 2017) and CBV maps of comparable diagnostic quality as the corresponding images acquired with a full dose imaging (Crisi, 2017). However, in acute stroke half-dose DSC imaging was found to result in poor image quality in 40.7% of the cases receiving half-dose GBCA (0.1 ml/kg gadobenate dimeglumine body weight) vs. 6.3% of patients who received full GBCA dose (0.2 ml/kg gadobenate dimeglumine body weight), and may thus adversely affect stroke patient triage for thrombectomy (Heit, 2021). For DSC MRI in neuroimaging the field dependency remains

to be investigated, and reduced dose imaging for this application remains controversial.

More recently, several recent studies have evaluated the clinical performance of deep learning (DL)-based methods for brain MRI reducing contrast dose up to 10-fold (Gong, 2021). However the missing enhancement in small lesions indicates the need for further improvements in DL based algorithms or dosage design (Ammari, 2022; Luo, 2021). To date, DL strategies to minimize the dosage of GBCAs in brain MRI are still in its infancy and additional studies on the (potential) loss of diagnostic information are warranted.

Beyond reducing GBCA dose, the omission of the need of GBCA-based sequences in MRI scan protocols is also widely studied, in particular for the follow-up of extra-axial brain masses. The majority of the studies have focused on vestibular schwannomas, including evaluation of the diagnostic accuracy of non-CE gradient-echo constructive interference in steady state (CISS) and coronal T2w imaging in the setting of screening (Abele, 2014). A recent meta-analysis evaluated non-CE imaging for diagnosis and monitoring of vestibular schwannomas (Kim, 2019). In this meta-analysis six studies evaluated measurement difference, five articles focused on diagnostic accuracy and eight studied adverse effects. The studies showed that a non-CE MRI scan protocol with T2w imaging is highly accurate and highly reliable for diagnosing and monitoring vestibular schwannoma in comparison with CE-T1w imaging. In addition to vestibular schwannomas, also for meningiomas it has been shown that dimensions measured on pre-contrast T2 have similar results compared to measurements on CE-T1w imaging (Rahatli, 2019). One study leaving out CE-sequences in MRI protocols in children (Marsault, 2019). This study investigated the use of non-CE MRI for the follow-up of optic pathway gliomas in children, suggesting that tumour volume variation may be sufficient to assess optic pathway glioma progression (Marsault, 2019).

In addition to extra-axial masses, another disease group in which comparative studies on non-CE versus CE MRI protocols have been evaluated is multiple sclerosis. For multiple sclerosis three studies have evaluated the use of MRI protocols using non-contrast sequences for the detection of new brain lesions on follow-up imaging (Eichinger, 2021). These studies indicate that considering the very low incidence rate of new enhancing lesions in patients with non-progressive disease on follow-up, the routine administration of contrast in follow-up MRI scans is of limited value and does not change the diagnosis interval of disease progression. Finally, one study was identified that compared the use of non-CE MRI protocols to protocols using GBCAs for stroke. This study evaluated non-CE MR venography compared to conventional CE-T1w imaging and 3D gradient echo CE-T1w imaging, demonstrating that unenhanced MR venography had slightly lower sensitivity, specificity and accuracy for detecting cortical venous and/or dural sinus thrombosis (Sari, 2015) compared to the contrast-enhanced protocols.

### Gadolinium reduction strategies for cardiovascular imaging

#### *Thoracic aorta*

Sequence designs such state-state free precession (SSFP) that enable combining non-breath-hold acquisitions with cardiac gating and respiratory triggering are widely used for vascular imaging with high resolution and high contrast between blood in the aorta and coronaries compared to surrounding tissue (Amano, 2008; Deshpande, 2001; François, 2008; Krishnam, 2008). International joint-society guidelines in the field of cardiology, cardiothoracic surgery and imaging have stated that non-CE MRA and CE-MRA are both acceptable imaging studies to measure the aorta in patients with thoracic aorta disease and adults with congenital heart

disease (Baumgartner, 2010; Hiratzka, 2016). Direct comparison between non-CE MRA to CE-MRA for the assessment of the dimensions of the thoracic aorta has been performed in several studies demonstrating that diagnostic image quality can be achieved without the need for Gadolinium (Bannas, 2013; Groth, 2012; Pennig, 2021; Veldhoen, 2017; Von Tengg-Kobligh, 2009).

#### *Supra-aortic vasculature*

Several studies have compared various non-CE MRA techniques for blood flow-related luminography, such as gradient-echo based time-of-flight (ToF), with CE-MRA for evaluating stenosis of the supra-aortic arteries. These studies show that non-CE MRA techniques are promising alternatives for stenosis grading, in particular for distinguishing surgically treatable internal carotid artery stenosis, without significantly compromising image quality or diagnostic accuracy (Babiarz, 2009; Lim, 2008; Liu, 2019; Peters, 2019; Zhang, 2020).

With regard to half dose imaging, half-dose (0.05 mmol/kg body weight) CE MRA and full-dose (0.1 mmol/kg body weight) CE-MRA have been evaluated with regard to SNR, CNR at both 1.5 T and 3T, demonstrating that dose-reduction of cervical CE-MRA is feasible at 3T without compromising angiographic quality with regard to stenosis evaluation (Dehkharghani, 2015). Low dose time-resolved CE-MRA has been evaluated compared to non-contrast ToF MRA and high-resolution CE-MRA, showing that time-resolved MRA has a good image quality and accurate stenosis grading compared to high-resolution CE-MRA and might be more useful than ToF-MRA (Lee YJ, 2015).

Two studies evaluated ultralow-dose Gd (2-3 mL) time-resolved MRA versus standard dose (0.1 mmol/kg) CE-MRA for the evaluation of supra-aortic arterial stenosis at 3T. These showed that image quality and diagnostic agreement for stenotic disease in ultralow dose time-resolved MRA scans using 2-3 mL were not inferior to standard dose CE-MRA (Bak, 2017; Lohan, 2009). However, Gd doses below 2 mL were considered limited in spatial resolution leading to a tendency of overestimating stenosis grade. Also for Gd doses as low as 0.047 mmol/kg MRA of the supra-aortic arteries can be performed at 3T, without compromising image quality, acquisition speed, or spatial resolution (Tomasian, 2008). However, it should be noted that the imaging quality at local centres will depend on the local MRI physics expertise to implement non-CE MRA or ultra-low CE-MRA techniques.

#### *Abdominal vasculature, peripheral arteries, and vascular malformations*

For the abdominal aorta and pelvic vasculature only one study was identified that compared low dose (Takahashi, 2004) to standard dose CE MRA. Three studies have been published that evaluated hepatic vasculature using non-contrast MRA compared to CE sequences (Kumar, 2021; Luk, 2017; Puipe, 2012), indicating that CE-MRI is not superior in depicting hepatic anatomy.

Several comparative studies have been published that evaluated non-contrast MRA for the assessment of renal artery stenosis, in particular balances steady-state free precession MR angiography (b-SSFP MRA) has shown promise in diagnosing renal artery stenosis (Aydin, 2017; Braidy, 2012; Glockner, 2010; Khoo, 2011; Lal, 2021; Maki, 2007). Also the three-dimensional Fast Imaging Employing Steady-State Acquisition (3D-FIESTA) sequence has been compared to CE-MRA and digital subtraction angiography (Gaudio, 2014), suggesting that also 3D FIESTA sequence could be a useful tool in evaluating RAS. Further studies are needed to evaluate whether non-contrast MRA can truly replace CE-MRA to determine the



presence of significant renal artery stenosis. Five studies were identified that evaluated non-contrast MRA for the evaluation of peripheral arterial occlusive disease. Although some studies were promising with regard to potential of non-contrast MRA techniques (Hodnett, 2011; Knobloch, 2021; Thierfelder, 2014), also concerns were expressed with regard to the rate of non-diagnostic vessel segments being considerably higher for non-contrast MRA than for CE-MRA (Diop, 2013; Schubert, 2016).

A specific indication of vascular imaging is the evaluation of vascular malformations. There is limited information in this disease group. One study evaluated a low dose CE protocol for diagnostic accuracy for treatment planning and follow-up but did not compare to standard dose MRI (Anzidei, 2011). For coil-embolized intra-cranial aneurysms it has been suggested that non-contrast ToF MRA can be used as a diagnostic alternative to CE ToF MRA (Behme, 2016).

### *Heart*

With regards to cardiac imaging, various studies have been published that evaluated the possibilities of non-contrast imaging for various applications. This is of particular relevance in cardiac imaging considering that high-risk populations with chronic kidney disease often are referred for cardiac imaging due to concomitant cardiovascular disease as part of cardiorenal syndrome. Few studies have evaluated the possibilities of detecting myocardial fibrosis using non-Gd protocols (Graham-Brown, 2018) or with lowered Gd dose using higher-relaxivity contrast media such as gadobenate dimeglumine (Cheong, 2015; Galea, 2014). With regards to these studies, it can be concluded that the need of GBCA is of great relevance for the detection of myocardial disease as the distribution of the Gd chelate to the increased extracellular volume in the equilibrium phase is the pathophysiological marker of delayed enhancement imaging, which as this moment cannot be reliably replaced by existing non-contrast sequences.

Although low dose GBCA protocols can visualize myocardial fibrosis, standard dose protocols did result in overall better image quality and should be routinely preferred (Galea, 2014). One study evaluated non-contrast coronary MRA for the detection of significant coronary artery disease combined with subsequent Gd adenosine stress perfusion imaging of the heart (Heer, 2013), indicating that additional stress perfusion imaging with Gd substantially improved the diagnostic accuracy of detecting significant coronary artery disease. A specific group in which the application of reduced dose (Faggioni, 2012; Montalt-Tordera, 2021) and non-CE protocols (Chang, 2013; Elzayat, 2018; Isaak, 2021) have been evaluated are patients with congenital heart disease. For visualization of anatomy of the great vessels in congenital heart disease, non-contrast MRA protocols can be used as alternative to contrast-enhanced (CE) MRA protocols. One study described the potential of DL for the improvement of contrast in low-dose MRA studies in patients with congenital heart disease (Montalt-Tordera, 2021).

### Gadolinium reduction strategies for musculoskeletal imaging

Four studies were identified that evaluated half dose imaging for musculoskeletal indications involving the assessment of synovitis or tenosynovitis (Schueller-Weidekamm, 2013), bone and soft-tissue disease in children (Colafati, 2018), bone and soft tissue tumours (Costelloe, 2011) and the evaluation of cartilage. These studies indicate that half dose GBCA protocols may be used while maintaining image quality (Rehnitz, 2020), however the limited number of studies indicate the need for additional research on this topic.

Studies evaluating the added value of GBCAs to musculoskeletal imaging protocols were mainly focused on detecting synovitis in patients with osteoarthritis and in spinal imaging. Albeit non-CE sequences can visualize synovitis, these are limited with an underestimation for detecting synovitis in patients with osteoarthritis (Crema, 2013; de Vries, 2021; Eshed, 2015) and inflammatory arthritis (Hemke, 2013). A recent meta-analysis aimed at determining the correlation between knee synovitis assessed on non-CE and CE MRI with histology in patients with knee osteoarthritis found that CE MRI scores correlated best with inflammatory infiltrates of synovial tissue, while paucity of current evidence warrants further studies on non-contrast for detecting knee synovitis (Shakoor, 2020).

With regards to spinal imaging, only three studies have been published that evaluated the added diagnostic value of Gd to spinal imaging protocols. One study investigated the differentiation of epidural fibrosis from disc herniation (Passavanti, 2020), one the characterization of vertebral marrow infiltrative lesions (Zidan, 2014), and one debated the added value of post-Gd images in contrast to non-enhanced scans for diagnosis of spondylitis and its complications (Prasetyo, 2020).

### Gadolinium reduction strategies for body imaging

#### *Prostate*

Several studies in the past few years have been performed that have investigated the performance of non-CE MRI of the prostate versus CE prostate MRI protocols. These studies have focused on the sensitivity and specificity of detecting prostate cancer using non-contrast imaging protocols (T2w + DWI [diffusion weighted imaging] sequences) compared to CE-imaging protocols (T2w + DWI + DCE [dynamic contrast enhanced imaging]). For the non-contrast imaging protocols the ranges for sensitivity and specificity of detecting clinically significant prostate cancer were respectively 63%-95% and 71-88%, compared to sensitivity and specificity ranging between 73-95% and 45-85% for protocols including Gd (Alabousi, 2019; Bass, 2021; Cuocolo, 2021; Knaapila, 2020; Kuhl, 2017; Liang, 2020; Niu, 2018; Park, 2021; Tamada, 2021). An overview of the main studies investigating the performance of non-contrast MRI of the prostate vs contrast MRI was recently summarized by Pecoraro (2021). For intra-procedural prostate imaging for identification of ablation zone extent, non-contrast T2\*w-MRI in one study has shown to be comparable to CE T1w-MRI suggesting that this might be a method for repeated intra-procedural monitoring of the thermal ablation zone without the need for Gd (Sun, 2021). With regard to lowered Gd dose strategies for prostate cancer, only one small study in 17 patients was identified that evaluated whether administration of low doses of Gd for DCE MRI can be as effective as a standard dose in distinguishing prostate cancer from benign tissue (He, 2018).

#### *Liver*

Several studies have been performed that compared half-dose imaging with standard-dose imaging in liver MRI. Most studies focused on gadobenate dimeglumine which has high T1 relaxivity and can be used for both dynamic and delayed liver MRI. A blinded intra-individual study evaluating standard and low dose liver MRI with gadobenate, found that albeit the standard dose yields greater relative enhancement, there is overall little improvement in subjective image quality (Kamali, 2020). Evaluation of enhancement patterns and characterization showed that half-dose and standard-dose liver MRI with gadopentetate dimeglumine found that 62 out of 64 lesions (97%) were identically characterized based on similar contrast enhancement compared to standard-dose gadodiamide (De Corato, 1999).

One study comparing half-dose gadobenate dimeglumine to standard dose gadopentetate dimeglumine showed that the half-dose imaging resulted in similar diagnostic information on dynamic imaging as well as the possibility of delayed imaging in the hepatobiliary phase (Schneider, 2003). Quarter-dose (0.025 mmol/kg) with gadobenate dimeglumine was compared retrospectively for image quality with half-dose imaging for abdominal MRI in patients at risk for nephrogenic systemic fibrosis, showing that the overall enhancement quality of the quarter dose was rated as good in all phases of enhancement, but was significantly lower than that for half-dose imaging (De Campos, 2011).

A recent meta-analysis study for surveillance MRI of hepatocellular carcinoma (HCC) using shortened MRI protocols (also referred to as abbreviated MRI) assessed the pooled sensitivity and specificity of contrast-enhanced hepatobiliary phase (HBP) abbreviated MRI (T2w, DWI, CE-T1w in HBP) and non-contrast abbreviated MRI (T2w, DWI, T1w dual-gradient echo imaging) (Kim, 2021). In this study there was a good overall diagnostic performance for detecting both any-stage HCC and early-stage HC, and the contrast-enhanced HBP abbreviated MRI showed a significantly higher sensitivity for detecting HCC than the non-contrast abbreviated MRI (87% vs. 82%) but had a significantly lower specificity (93% vs. 98%) ( $p = 0.03$ ). The main limitation of the non-contrast abbreviated MRI is the relatively low lesion-to-liver contrast.

Also for liver metastases detection, non-contrast MRI protocols have been studied indicating that in particular DWI is an important sequence that improved mean specificity, positive predictive, negative predictive, and accuracy values for lesions either as small or greater than 1 cm (Colagrande, 2016). A comparative study in 175 patients with histologically confirmed 401 liver metastases and 73 benign liver lesions found no significant differences in sensitivity (range = 95.2-99.6%), specificity (range = 77.3-100%), positive predictive value (range = 92.9-100%) or negative predictive value (range = 87.5-95.7%) between the non-contrast MRI and the full MRI protocol with contrast (Hwang, 2019). These studies indicate that non-contrast liver MRI that includes DWI may serve as an alternative to contrast-enhanced MRI for detecting and characterizing liver metastases in patients with relatively high risk of liver metastases.

Finally, one study in patients with suspected possible choledocholithiasis evaluated the comparative performance of non-contrast MRI with half-Fourier acquisition single-shot turbo spin echo (HASTE) versus contrast-enhanced MRI/3D-magnetic resonance cholangiopancreatography (MRCP) (Kang, 2017). In this study the abbreviated non-contrast MRI with HASTE and full contrast-enhanced MRI/3D-MRCP resulted in high accuracy for choledocholithiasis (91.1-94.3% vs. 91.9-92.7%) and no differences in sensitivity or specificity were found, indicating that in patients with suspected choledocholithiasis, performance of non-contrast abdominal MRI with HASTE is similar to contrast-enhanced MRI with 3D-MRCP, offering potential for decreased scanning time and improved patient tolerability (Kang, 2017).

#### Other body imaging applications

Only few studies have been published that evaluate non-contrast MRI protocols for other body applications such as renal (Mawi, 2021), pancreatic (Lee, 2019), gastro-intestinal (Cattapan, 2019; Goshima, 2009; Kim SJ, 2019), and adnexal (Sahin, 2021) imaging. Albeit these studies are promising about the possibility of leaving out Gd-based sequences in MRI protocols without compromising diagnostic confidence, more studies are needed before specific recommendations on non-contrast MRI strategies for body imaging can be made.

Also for MRI studies with low dose strategies for renal renography and urography more evidence is needed (Bayrak, 2002).

### Gadolinium reduction strategies for breast imaging

Dynamic contrast-enhanced magnetic resonance imaging (DCE-MRI) is the most sensitive technique in breast imaging for the detection of breast cancer, however an increasing number of studies have investigated the potential of unenhanced or abbreviated MRI protocols without the need for GBCA in breast cancer imaging. In total seven studies were found that evaluated the application of non-contrast breast MRI protocols versus breast MRI protocols that include Gd based sequences. Although non-contrast sequences such as STIR and DWI have good specificity for the detection of breast cancer (Belli, 2016; Khalil, 2020; Telegrafo, 2015), reduced diagnostic performance for small lesions (<10 mm) limits the application of non-contrast breast MRI (Belli, 2016). Combining unenhanced MRI of the breast with additional breast tomosynthesis may improve the diagnostic accuracy of non-contrast breast MRI protocols (Girometti, 2020; Rizzo, 2021).

Some initial evaluation of the application of non-contrast breast MRI protocols has been performed in the context of evaluation of treatment response of neoadjuvant chemotherapy (Cavallo, 2019). One study evaluated high spectral and spatial resolution MRI (Medved, 2011) indicating the need for further research on new MRI sequences. In addition, protocols with reduced GBCA dose need further investigation. In the present literature search one study was identified that investigated a half dose Gd protocol for breast MRI. This study in 40 patients evaluated whether half dose gadobutrol (0.05 mmol/kg) was able to detect biopsy-proven breast cancers imaged at 3T using DCE MRI. All 49 breast cancers (of which approximately a quarter were smaller than 2 cm) were detectable using half dose gadobutrol on 3T MRI and did not differ in conspicuity scores (Melsaether, 2019).

### **Recommendations**

*In general, it can be concluded that the evidence for non-CE imaging in applications where CE imaging is considered standard of care is still too scarce to be able to draw conclusions and for this reason in this section only remarks summarizing the body of literature are provided, and no active recommendations are formulated. Few comparative studies on reduced dose imaging have been performed from which the following can be recommended:*

#### I Potential dose-reduction strategies for neuroimaging with gadolinium-based contrast agents

Findings of the LEADER-75 trial indicate that the dose of gadolinium-based contrast agents (gadobutrol) may be reduced to up to 75% of the standard dose (0.075 mmol/kg bodyweight, equivalent to 0.075 ml/kg bodyweight) in patients with suspected brain lesions.

The use of deep learning based methods for gadolinium dose reduction in patients suspected with brain metastasis is not recommended based on the current literature.

#### II Potential dose-reduction strategies for cardiovascular imaging with gadolinium-based contrast agents

The use of standard dose imaging is recommended in patients with clinical indications for the administration of gadolinium-based contrast agents in cardiac MRI.

Non-CE MRA techniques (e.g., time-of-flight MRA) are widely available and can be used for accurate evaluation of stenosis grade of the supra-aortic vasculature.

Non-CE ECG-gated MRA sequences are widely available and recommended over (low-dose) CE MRA techniques for the evaluation of aortic dimensions.

### III Potential dose-reduction strategies for musculoskeletal imaging with gadolinium-based contrast agents

The use of standard dose imaging is recommended in patients with clinical indications for the administration of gadolinium based contrast agents in musculoskeletal imaging.

### IV Potential dose-reduction strategies for abdominal imaging with gadolinium-based contrast agents

#### *Prostate*

There is increasing evidence that biparametric (T2w + DWI) protocols may be used as an alternative to multiparametric (T2w + DWI + DCE) protocols for the detection of prostate cancer (See also guideline on Prostate Cancer).

#### *Liver*

The use of standard dose imaging is recommended in patients with clinical indications for the administration of gadolinium based contrast agents in liver MRI.

### V Potential dose-reduction strategies for breast imaging with gadolinium-based contrast agents

The use of standard dose imaging is recommended in patients with clinical indications for the administration of gadolinium based contrast agents in breast MRI.

## Literature

- Abele TA, Besachio DA, Quigley E, Gurgel RK, Shelton C, Harnsberger HR, et al. Diagnostic accuracy of screening MR imaging using unenhanced axial CISS and coronal T2WI for detection of small internal auditory canal lesions. *AJNR Am J Neuroradiol*. 2014; 35(12): 2366–2370.
- Åkeson P, Larsson EM, Kristoffersen DT, Jonsson E, Holtås S. Brain metastases - Comparison of gadodiamide injection-enhanced MR imaging at standard and high dose, contrast-enhanced CT and non-contrast-enhanced MR Imaging. *Acta Radiol*. 1995; 36(3): 300–306.
- Alabousi M, Salameh J P, Gusenbauer K, Samoilov L, Jafri A, Yu H, et al. Biparametric vs multiparametric prostate magnetic resonance imaging for the detection of prostate cancer in treatment-naïve patients: A diagnostic test accuracy systematic review and meta-analysis. *BJU Int*. 2019; 124(2): 209–220.
- Amano Y, Takahama K, Kumita S. Non-contrast-enhanced MR angiography of the thoracic aorta using cardiac and navigator-gated magnetization-prepared three-dimensional steady-state free precession. *J Magn Reson Imaging*. 2008; 27(3): 504–509.
- Ammari S, Bône A, Balleyguier C, Moulton E, Chouzenoux É, Volk A, et al. Can deep learning replace gadolinium in neuro-oncology: A reader study. *Invest Radiol*. 2022; 57(2): 99–107.
- Anzidei M, Cavallo Marincola B, Napoli A, Saba L, Zaccagna F, Lucatelli P, et al. Low-dose contrast-enhanced time-resolved MR angiography at 3T: diagnostic accuracy for treatment planning and follow-up of vascular malformations. *Clin Radiol*. 2011; 66(12): 1181–1192.
- Aydin E, Yerli H, Altin C, Gezmiş E, Agildere, M. Comparison of non-contrast magnetic resonance angiography using inflow inversion recovery (Inhance) technique and contrast-enhanced magnetic resonance angiography in the assessment of renal arteries in patients with hypertension. *Iran J Radiol*. 2017; 14(3): e14599.
- Babiarz LS, Romero JM, Murphy EK, Brobeck B, Schaefer PW, González RG, et al. Contrast-enhanced MR angiography is not more accurate than unenhanced 2D time-of-flight MR angiography for determining > or = 70% internal carotid artery stenosis. *AJNR Am J Neuroradiol*. 2009; 30(4): 761–768.
- Bak SH, Roh HG, Moon WJ, Choi JW, An HS. Appropriate minimal dose of gadobutrol for 3D Time-Resolved MRA of the supra-aortic arteries: comparison with conventional single-phase high-resolution 3D contrast-enhanced MRA. *AJNR Am J Neuroradiol*. 2017; 38(7): 1383–1390.
- Bannas P, Groth M, Rybczynski M, Sheikhzadeh S, Von Kodolitsch Y, Graessner J, et al. Assessment of aortic root dimensions in patients with suspected Marfan syndrome: intraindividual comparison of contrast-enhanced and non-contrast magnetic resonance angiography with echocardiography. *Int J Cardiol*. 2013; 167(1): 190–196.
- Bass EJ, Pantovic A, Connor M, Gabe R, Padhani AR, Rockall A, et al. A systematic review and meta-analysis of the diagnostic accuracy of biparametric prostate MRI for prostate cancer in men at risk. *Prostate Cancer Prostatic Dis*. 2021; 24(3): 596–611.
- Baumgartner H, Bonhoeffer P, De Groot NMS, De Haan F, Deanfield JE, Galie N, et al. ESC Guidelines for the management of grown-up congenital heart disease (new version 2010). The Task Force on the Management of Grown-up Congenital Heart Disease of the European Society of Cardiology (ESC). *Eur Heart J*. 2010; 31(23): 2915–2957.
- Bayrak IK, Ozmen Z, Nural MS, Danaci M, Diren B. A comparison of low-dose and normal-dose gadobutrol in MR renography and renal angiography. *Korean J Radiol*. 2008; 9(3): 250–257.

- Behme D, Malinova V, Kallenberg K, Knauth M, Mohr A. Unenhanced Time-of-Flight MR angiography versus gadolinium-enhanced Time-of-Flight MR angiography in the follow-up of coil-embolized aneurysms. *J Neurol Surgery A Cent Eur Neurosurg*. 2016; 77(5): 400–405.
- Belli P, Bubi E, Bonatesta A, Patrolecco F, Padovano F, Giuliani M, et al. Unenhanced breast magnetic resonance imaging: detection of breast cancer. *Eur Rev Med Pharmacol Sci*. 2016; 20(20): 4220–4229.
- Braidy C, Daou I, Diop A D, Helweh O, Gageanu C, Boyer L, Chabrot P. Unenhanced MR angiography of renal arteries: 51 patients. *AJR Am J Roentgenol*. 2012; 199(5): W629–W637.
- Cattapan K, Chulroek T, Kordbacheh H, Wancharoenrung D, Harisinghani M. Contrast- vs. non-contrast enhanced MR data sets for characterization of perianal fistulas. *Abdom Radiol*. 2019; 44(2): 446–455.
- Cavallo Marincola B, Telesca M, Zaccagna F, Riemer F, Anzidei M, Catalano C, et al. Can unenhanced MRI of the breast replace contrast-enhanced MRI in assessing response to neoadjuvant chemotherapy? *Acta Radiol*. 2019; 60(1): 35–44.
- Chang D, Kong X, Zhou X, Li S, Wang H. Unenhanced steady state free precession versus traditional MR imaging for congenital heart disease. *Eur J Radiol*. 2013; 82(10): 1743–1748.
- Cheong BY, Duran C, Preventza OA, Muthupillai R. Comparison of low-dose higher-relaxivity and standard-dose lower-relaxivity contrast media for delayed-enhancement MRI: A blinded randomized crossover study. *AJR Am J Roentgenol*. 2015; 205(3): 533–539.
- Colafati GS, Rossi E, Carducci C, Piga S, Voicu IP, Mastronuzzi A, Tomà P. Half-dose versus full-dose macrocyclic gadolinium at 3-T magnetic resonance imaging in paediatric bone and soft-tissue disease. *Pediatr Radiol*. 2018; 48(12): 1724–1735.
- Colagrande S, Castellani A, Nardi C, Lorini C, Calistri L, Filippone A. The role of diffusion-weighted imaging in the detection of hepatic metastases from colorectal cancer: A comparison with unenhanced and Gd-EOB-DTPA enhanced MRI. *Eur J Radiol*. 2016; 85(5): 1027–1034.
- Costelloe CM, Murphy WA, Haygood TM, Kumar R, McEnery KW, Stafford RJ, et al. Comparison of half-dose and full-dose gadolinium MR contrast on the enhancement of bone and soft tissue tumors. *Skeletal Radiol*. 2011; 40(3): 327–333.
- Crema MD, Felson DT, Roemer FW, Niu J, Marra MD, Zhang Y, et al. Peripatellar synovitis: comparison between non-contrast-enhanced and contrast-enhanced MRI and association with pain. The MOST study. *Osteoarthritis Cartilage*. 2013; 21(3): 413–418.
- Crisi G, Filice S, Erb G, Bozzetti F. Effectiveness of a high relaxivity contrast agent administered at half dose in dynamic susceptibility contrast MRI of brain gliomas. *J Magn Reson Imaging*. 2017; 45(2): 500–506.
- Cuocolo R, Verde F, Ponsiglione A, Romeo V, Petretta M, Imbriaco M, et al. Clinically significant prostate cancer detection with biparametric MRI: A systematic review and meta-analysis. *AJR Am J Roentgenol*. 2021; 216(3): 608–621.
- De Campos ROP, Heredia V, Ramalho M, De Toni MS, Lugo-Somolinos A, Fuller ER, et al. Quarter-dose (0.025 mmol/kg) gadobenate dimeglumine for abdominal MRI in patients at risk for nephrogenic systemic fibrosis: Preliminary observations. *AJR Am J Roentgenol*. 2011; 196(3): 545–552.
- De Corato DR, Krinsky GA, Rofsky NM, Earls JP, Lebowitz J, Weinreb JC. Contrast-enhanced hepatic MRI: comparison of half-dose and standard-dose gadolinium DTPA administration in lesion characterization with T1-weighted gradient echo sequences. *Clin Imaging*. 1999; 23(5): 302–310.

- De Vries BA, Breda SJ, Sveinsson B, McWalter EJ, Meuffels DE, Krestin GP, et al. Detection of knee synovitis using non-contrast-enhanced qDESS compared with contrast-enhanced MRI. *Arthritis Res Ther* 2021; 23(1): 55.
- Dehkharghani S, Qiu D, Albin LS, Saindane AM. Dose reduction in contrast-enhanced cervical MR angiography: field strength dependency of vascular signal intensity, contrast administration, and arteriographic quality. *AJR Am J Roentgenol*. 2015; 204(6): W701–W706.
- DeLano MC, Spampinato MV, Chang EY, Barr RG, Lichtenstein RJ, Colosimo C, et al. Dose-lowering in contrast-enhanced MRI of the central nervous system: A retrospective, parallel-group comparison using gadobenate dimeglumine. *J Magn Reson Imaging*. 2021; 54(5): 1660–1675.
- Deshpande VS, Shea SM, Laub G, Simonetti OP, Finn JP, Li D. 3D magnetization-prepared true-FISP: a new technique for imaging coronary arteries. *Magn Reson Med*. 2001; 46(3): 494–502.
- Diop AD, Braidly C, Habouchi A, Niang K, Gageanu C, Boyer L, et al. Unenhanced 3D turbo spin-echo MR angiography of lower limbs in peripheral arterial disease: a comparative study with gadolinium-enhanced MR angiography. *AJR Am J Roentgenol*. 2013; 200(5): 1145–1150.
- Eichinger P, Schön S, Pongratz V, Wiestler H, Zhang H, Bussas M, et al. Accuracy of unenhanced MRI in the detection of new brain lesions in multiple sclerosis. *Radiology*. 2019; 291(2): 429–435.
- Elzayat WA, Onsy MM, Ali MT, El-Kiki HA, Hegazy RA. Non-contrast versus contrast enhanced MRI of the great thoracic vessels in pediatric congenital heart disease: A quantitative and qualitative analysis. *Egypt J Radiol Nucl Med*. 2018; 49(3): 747–754.
- Eshed I, Krabbe S, Østergaard M, Bøyesen P, Møller JM, Therkildsen F, et al. Influence of field strength, coil type and image resolution on assessment of synovitis by unenhanced MRI – A comparison with contrast-enhanced MRI. *Eur Radiol*. 2015; 25(4): 1059–1067.
- Faggioni L, Zampa V, Ortori S, Picano E, De Lucia R, Soldati E, et al. Time-resolved contrast-enhanced magnetic resonance angiography (CEMRA) of the left atrium-pulmonary veins complex with half dose of intravenous gadolinium-based contrast agent. Technical feasibility and comparison with a conventional CEMRA, full contrast. *Eur J Radiology*. 2012; 81(2): 250–256.
- Filice S, Crisi G, Erb G. T2\*-Correction in dynamic contrast-enhanced magnetic resonance imaging of glioblastoma from a half dose of high-relaxivity contrast agent. *J Comput Assist Tomogr*. 2017; 41(6): 916–921.
- François CJ, Hecht EM, Roditi G, Finn D JP. MR angiography series: Noncardiac chest MR angiography. *Radiographics*. 2022; 42(2): E48-E49.
- François CJ, Tuite D, Deshpande V, Jerecic R, Weale P, Carr JC. Unenhanced MR angiography of the thoracic aorta: initial clinical evaluation. *AJR Am J Roentgenol*. 2008; 190(4): 902–906.
- Galea N, Francone M, Zaccagna F, Ciolina F, Cannata D, Algeri E, et al. Ultra low dose of gadobenate dimeglumine for late gadolinium enhancement (LGE) imaging in acute myocardial infarction: a feasibility study. *Eur J Radiol*. 2014; 83(12): 2151–2158.
- Gaudio C, Busato F, Ferramosca E, Cecchelli C, Corcioni B, De Sanctis LB, et al. 3D FIESTA pulse sequence for assessing renal artery stenosis: is it a reliable application in unenhanced magnetic resonance angiography? *Eur Radiol*. 2014; 24(12): 3042–3050.
- Girometti R, Marconi V, Linda A, Di Mico L, Bondini F, Zuiani C, Sardanelli F. Preoperative assessment of breast cancer: Multireader comparison of contrast-enhanced MRI versus the combination of unenhanced MRI and digital breast tomosynthesis. *Breast*. 2020; 49: 174–182.



- Glockner JF, Takahashi N, Kawashima A, Woodrum DA, Stanley DW, Takei N, et al. Non-contrast renal artery MRA using an inflow inversion recovery steady state free precession technique (Inhance): comparison with 3D contrast-enhanced MRA. *J Magn Reson Imaging*. 2010; 31(6): 1411–1418.
- Gong E, Pauly J M, Wintermark M, Zaharchuk G. Deep learning enables reduced gadolinium dose for contrast-enhanced brain MRI. *J Magn Reson Imaging*. 2018; 48(2): 330–340.
- Goshima S, Kanematsu M, Kondo H, Tsuge Y, Watanabe H, Shiratori Y, et al. Detection and grading for oesophageal varices in patients with chronic liver damage: comparison of gadolinium-enhanced and unenhanced steady-state coherent MR images. *Magn Reson Imaging*. 2009; 27(9): 1230–1235.
- Graham-Brown MP, Singh AS, Gulsin GS, Levelt E, Arnold JA, Stensel DJ, et al. Defining myocardial fibrosis in haemodialysis patients with non-contrast cardiac magnetic resonance. *BMC Cardiovasc Disord*. 2018; 18(1): 145.
- Groth M, Henes F O, Müllerleile K, Bannas P, Adam G, Regier M. Accuracy of thoracic aortic measurements assessed by contrast enhanced and unenhanced magnetic resonance imaging. *Eur J Radiol*. 2012; 81(4): 762–766.
- Haba D, Pasco Papon A, Tanguy J Y, Burtin P, Aube C, Caron-Poitreau C. Use of half-dose gadolinium-enhanced MRI and magnetization transfer saturation in brain tumors. *Eur Radiol*. 2001; 11(1): 117–122.
- Han D, Chang KH, Han MH, Cho JY, Han SW, Kim HD, et al. Half-dose gadolinium-enhanced MR imaging with magnetization transfer technique in brain tumors: comparison with conventional contrast-enhanced MR imaging. *AJR Am J Roentgenol*. 1998; 170(1): 189–193.
- He D, Chatterjee A, Fan X, Wang S, Eggner S, Yousuf A, et al. Feasibility of dynamic contrast-enhanced magnetic resonance imaging using low-dose gadolinium: comparative performance with standard dose in prostate cancer diagnosis. *Invest Radiol*. 2018; 53(10): 609–615.
- Heer T, Reiter S, Höfling B, Pilz G. Diagnostic performance of non-contrast-enhanced whole-heart magnetic resonance coronary angiography in combination with adenosine stress perfusion cardiac magnetic resonance imaging. *Am Heart J*. 2013; 166(6): 999–1009.
- Heit JJ, Christensen S, Mlynash M, Marks MP, Faizy TD, Lansberg MG, et al. MR perfusion imaging: Half-dose gadolinium is half the quality. *J Neuroimaging*. 2021; 31(5): 1014–1019.
- Hemke R, Kuijpers TW, Van Den Berg JM, Van Veenendaal M, Dolman KM, Van Rossum MAJ, et al. The diagnostic accuracy of unenhanced MRI in the assessment of joint abnormalities in juvenile idiopathic arthritis. *Eur Radiol*. 2013; 23(7): 1998–2004.
- Hiratzka LF, Creager MA, Isselbacher EM, Svensson LG, Nishimura RA, Bonow RO, et al. Surgery for aortic dilatation in patients with bicuspid aortic valves: A Statement of Clarification from the American College of Cardiology/American Heart Association Task Force on Clinical Practice Guidelines. *Circulation*. 2016; 133(7): 680–686.
- Hodnett PA, Ward EV, Davarpanah AH, Scanlon TG, Collins JD, Glielmi CB, et al. Peripheral arterial disease in a symptomatic diabetic population: prospective comparison of rapid unenhanced MR angiography (MRA) with contrast-enhanced MRA. *AJR Am J Roentgenol*. 2011; 197(6): 1466–1473.
- Hughes J, Jan W, Goodie J, Lund R, Rankin S. MR urography: evaluation of different techniques in non-dilated tracts. *Clin Radiol*. 2002; 57(11): 989–994.
- Hwang JA, Kim YK, Min JH, Song KD, Sohn I, Ahn HS. Non-contrast liver MRI as an alternative to gadoteric acid-enhanced MRI for liver metastasis from colorectal cancer. *Acta Radiol*. 2019; 60(4): 441–450.
- Isaak A, Luetkens JA, Faron A, Endler C, Mesrobian N, Katemann C, et al. Free-breathing non-contrast flow-independent cardiovascular magnetic resonance angiography using

- cardiac gated, magnetization-prepared 3D Dixon method: assessment of thoracic vasculature in congenital heart disease. *J Cardiovasc Magn Reson*. 2021; 23(1): 91.
- Jin T, Ge M, Huang R, Yang Y, Liu T, Zhan Q, et al. Utility of contrast-enhanced T2 FLAIR for Imaging brain metastases using a half-dose high-relaxivity contrast agent. *AJNR Am J Neuroradiol*. 2021; 42(3): 457–463.
- Kamali M, Clarke SE, Costa AF. Evaluation of liver MRI examinations with two dosages of gadobenate dimeglumine: a blinded intra-individual study. *Abdom Radiol*. 2020; 45(1): 36–44.
- Kang SK, Heacock L, Doshi AM, Ream JR, Sun J, Babb JS. Comparative performance of non-contrast MRI with HASTE vs. contrast-enhanced MRI/3D-MRCP for possible choledocholithiasis in hospitalized patients. *Abdom Radiol*. 2017; 42(6): 1650–1658.
- Khalil R, Osman NM, Chalabi N, Abdel Ghany E. Unenhanced breast MRI: could it replace dynamic breast MRI in detecting and characterizing breast lesions? *Egypt J Radiol Nucl Med*. 2020; 51(1): 1–8.
- Khoo MMY, Deeab D, Gedroyc WMW, Duncan N, Taube D, Dick EA. Renal artery stenosis: comparative assessment by unenhanced renal artery MRA versus contrast-enhanced MRA. *Eur Radiol*. 2011; 21(7): 1470–1476.
- Khouri Chalouhi K, Papini GDE, Bandirali M, Sconfienza LM, Di Leo G, Sardanelli F. Less is better? Intraindividual and interindividual comparison between 0.075 mmol/kg of gadobenate dimeglumine and 0.1 mmol/kg of gadoterate meglumine for cranial MRI. *Eur J Radiol*. 2014; 83(7):1245-1249.
- Kim DH, Lee S, Hwang, SH. Non-contrast magnetic resonance imaging for diagnosis and monitoring of vestibular schwannomas: A systematic review and meta-analysis. *Otol Neurotol*. 2019; 40(9): 1126–1133.
- Kim DH, Choi SH, Shim JH, Kim SY, Lee SS, Byun JH, et al. Meta-analysis of the accuracy of abbreviated magnetic resonance imaging for hepatocellular carcinoma surveillance: Non-contrast versus hepatobiliary phase-abbreviated magnetic resonance imaging. *Cancers*. 2021; 13(12): 2975.
- Kim SJ, Ratchford TL, Buchanan PM, Patel DR, Tao TY, Teckman JH, et al. Diagnostic accuracy of non-contrast magnetic resonance enterography in detecting active bowel inflammation in pediatric patients with diagnosed or suspected inflammatory bowel disease to determine necessity of gadolinium-based contrast agents. *Pediatr Radiol*. 2019; 49(6): 759–769.
- Knaapila J, Jambor I, Perez IM, Ettala O, Taimen P, Verho J, et al. Prebiopsy IMPROD biparametric magnetic resonance imaging combined with prostate-specific antigen density in the diagnosis of prostate cancer: An external validation study. *Eur Urol Oncol*. 2020; 3(5): 648–656.
- Knobloch G, Lauff MT, Hanke M, Schwenke C, Hamm B, Wagner M. Non-contrast-enhanced MR-angiography (MRA) of lower extremity peripheral arterial disease at 3 tesla: Examination time and diagnostic performance of 2D quiescent-interval single-shot MRA vs. 3D fast spin-Echo MRA. *Magn Reson Imaging*. 2021; 76: 17–25.
- Krautmacher C, Willinek WA, Tschampa HJ, Born M, Träber F, Gieseke J, et al. Brain tumors: Full- and half-dose contrast-enhanced MR imaging at 3.0 T compared with 1.5 T - Initial experience. *Radiology*. 2005; 237(3): 1014–1019.
- Krishnam MS, Tomasian A, Lohan DG, Tran L, Finn JP, Rühm SG. Low-dose, time-resolved, contrast-enhanced 3D MR angiography in cardiac and vascular diseases: correlation to high spatial resolution 3D contrast-enhanced MRA. *Clin Radiol*. 2008; 63(7): 744–755.
- Kuhl CK, Bruhn R, Krämer N, Nebelung S, Heidenreich A, Schrading S. Abbreviated biparametric prostate MR imaging in men with elevated prostate-specific antigen. *Radiology*. 2017; 285(2): 493–505.

- Kumar A, Saxena AK, Bhatia A, Lal S, Rana P, Bawa M, Sodhi KS. Comparison of unenhanced and contrast-enhanced 3 T magnetic resonance portovenography in children with extrahepatic portal venous obstruction. *Abdom Radiol*. 2021; 46(8): 3917–3926.
- Lal H, Singh RKR, Yadav P, Yadav A, Bhadauria D, Singh A. Non-contrast MR angiography versus contrast enhanced MR angiography for detection of renal artery stenosis: a comparative analysis in 400 renal arteries. *Abdom Radiol*. 2021; 46(5): 2064–2071.
- Lee JH, Min JH, Kim YK, Cha DI, Lee J, Park HJ, et al. Usefulness of non-contrast MR imaging in distinguishing pancreatic ductal adenocarcinoma from focal pancreatitis. *Clin Imaging*. 2019; 55: 132–139.
- Lee YJ, Kim BS, Koo JS, Kim BY, Jang J, Choi HS, et al. Supra-aortic low-dose contrast-enhanced time-resolved magnetic resonance (MR) angiography at 3 T: comparison with time-of-flight MR angiography and high-resolution contrast-enhanced MR angiography. *Acta Radiol*. 2015; 56(6): 673–680.
- Liang Z, Hu R, Yang Y, An N, Duo X, Liu Z, et al. Is dynamic contrast enhancement still necessary in multiparametric magnetic resonance for diagnosis of prostate cancer: A systematic review and meta-analysis. *Transl Androl Urol*. 2020; 9(2): 553–573.
- Lim RP, Shapiro M, Wang EY, Law M, Babb JS, Rueff LE, et al. 3D time-resolved MR angiography (MRA) of the carotid arteries with time-resolved imaging with stochastic trajectories: comparison with 3D contrast-enhanced Bolus-Chase MRA and 3D Time-of-Flight MRA. *AJNR Am J Neuroradiol*. 2008; 29(10): 1847–1854.
- Liu BP, Rosenberg M, Saverio P, Weon YC, Peters S, Ardellier FD, et al. Clinical efficacy of reduced-dose gadobutrol versus standard-dose gadoterate for contrast-enhanced MRI of the CNS: An international multicenter prospective crossover trial (LEADER-75). *AJR Am J Roentgenol*. 2021; 217(5): 1195–1205.
- Liu H, Sun J, Hippe DS, Wu W, Chu B, Balu N, et al. Improved carotid lumen delineation on non-contrast MR angiography using SNAP (Simultaneous Non-Contrast Angiography and Intraplaque Hemorrhage) imaging. *Magn Reson Imaging*. 2019; 62: 87–93.
- Lohan DG, Tomasian A, Saleh RS, Singhal A, Krishnam MS, Finn JP. Ultra-low-dose, time-resolved contrast-enhanced magnetic resonance angiography of the carotid arteries at 3.0 Tesla. *Invest Radiol*. 2009; 44(4): 207–217.
- Luk L, Shenoy-Bhangle AS, Jimenez G, Ahmed FS, Prince MR, Samstein B, et al. Additive value of non-contrast MRA in the preoperative evaluation of potential liver donors. *Clin Imaging*. 2017; 41: 132–136.
- Luo H, Zhang T, Gong NJ, Tamir J, Venkata SP, Xu C, et al. Deep learning-based methods may minimize GBCA dosage in brain MRI. *Eur Radiol*. 2021; 31(9): 6419–6428.
- Maki JH, Wilson GJ, Eubank WB, Glickerman DJ, Pipavath S, Hoogeveen RM. Steady-state free precession MRA of the renal arteries: breath-hold and navigator-gated techniques vs. CE-MRA. *J Magn Reson Imaging*. 2007; 26(4): 966–973.
- Marsault P, Ducassou S, Menut F, Bessou P, Havez-Enjolras M, Chateil JF. Diagnostic performance of an unenhanced MRI exam for tumor follow-up of the optic pathway gliomas in children. *Neuroradiology*. 2019; 61(6): 711–720.
- Mawi H, Narine R, Schieda N. Adequacy of unenhanced MRI for surveillance of small (clinical T1a) solid renal masses. *AJR Am J Roentgenol*. 2021; 216(4): 960–966.
- Medved M, Fan X, Abe H, Newstead GM, Wood AM, Shimauchi A, et al. Non-contrast enhanced MRI for evaluation of breast lesions. comparison of non-contrast enhanced High Spectral and Spatial Resolution (HiSS) images versus contrast enhanced fat-suppressed images. *Acad Radiol*. 2011; 18(12): 1467–1474.
- Melsaether AN, Kim E, Mema E, Babb JS, Kim SG. Preliminary study: Breast cancers can be well seen on 3T breast MRI with a half-dose of gadobutrol. *Clin Imaging*. 2019; 58: 84–89.

- Montalt-Tordera J, Quail M, Steeden JA, Muthurangu V. Reducing contrast agent dose in cardiovascular MR Angiography with deep learning. *J Magn Reson Imaging*. 2021; 54(3): 795–805.
- Niu XK, Chen XH, Chen ZF, Chen L, Li J, Peng T. Diagnostic performance of biparametric MRI for detection of prostate cancer: A systematic review and meta-analysis. *AJR Am J Roentgenol*. 2018; 211(2): 369–378.
- Park KJ, Choi SH, Kim MH, Kim JK, Jeong IG. Performance of Prostate Imaging Reporting and Data System version 2.1 for diagnosis of prostate cancer: A systematic review and meta-analysis. *J Magn Reson Imaging*. 2021; 54(1): 103–112.
- Passavanti Z, Leschka S, Wildermuth S, Forster T, Dietrich TJ. Differentiating epidural fibrosis from disc herniation on contrast-enhanced and unenhanced MRI in the postoperative lumbar spine. *Skeletal Radiol*. 2020; 49(11): 1819–1827.
- Pasumarthi S, Tamir JJ, Christensen S, Zaharchuk G, Zhang T, Gong E. A generic deep learning model for reduced gadolinium dose in contrast-enhanced brain MRI. *Magn Reson Med*. 2021; 86(3): 1687–1700.
- Pecoraro M, Messina E, Bicchetti M, Carnicelli G, Del Monte M, Iorio B, et al. The future direction of imaging in prostate cancer: MRI with or without contrast injection. *Andrology*. 2021; 9(5): 1429–1443.
- Pennig L, Wagner A, Weiss K, Lennartz S, Huntgeburth M, Hicethier T, et al. Comparison of a novel Compressed SENSE accelerated 3D modified relaxation-enhanced angiography without contrast and triggering with CE-MRA in imaging of the thoracic aorta. *Int J Cardiovasc Imaging*. 2021; 37(1): 315–329.
- Peters S, Huhndorf M, Jensen-Kondering U, Larsen N, Koktzoglou I, Edelman RR, et al. Non-contrast-enhanced carotid MRA: Clinical evaluation of a novel ungated radial Quiescent-Interval Slice-Selective MRA at 1.5T. *AJNR Am J Neuroradiol*. 2019; 40(9): 1529–1537.
- Prasetyo M, Sirath AS, Wicaksono KP, Prihartono J, Setiawan SI. Non-contrast versus contrast-enhanced MR in the diagnosis of spondylitis: A quantitative concordance-analysis. *Eur J Radiol Open*. 2020; 7: 100306.
- Puippe GD, Alkadhi H, Hunziker R, Nanz D, Pfammatter T, Baumüller S. Performance of unenhanced respiratory-gated 3D SSFP MRA to depict hepatic and visceral artery anatomy and variants. *Eur J Radiol*. 2012; 81(8): e823-e829.
- Rahatli FK, Donmez FY, Kesim C, Haberal KM, Turnaoglu H, Agildere AM. Can unenhanced brain magnetic resonance imaging be used in routine follow up of meningiomas to avoid gadolinium deposition in brain? *Clin Imaging*. 2019; 53: 155–161.
- Rehnitz C, Do T, Klaan B, Burkholder I, Barié A, Wünnemann F, et al. Feasibility of using half-dose Gd-BOPTA for delayed gadolinium-enhanced MRI of cartilage (dGEMRIC) at the knee, compared with standard-dose Gd-DTPA. *J Magn Reson Imaging*. 2020; 51(1): 144–154.
- Rizzo V, Moffa G, Kripa E, Caramanico C, Pediconi F, Galati, F. Preoperative staging in breast cancer: Intraindividual comparison of unenhanced MRI combined with digital breast tomosynthesis and dynamic contrast enhanced MRI. *Front Oncol*. 2021; 11: 661945.
- Sadigh G, Saindane AM, Waldman AD, Lava NS, Hu R. Comparison of unenhanced and gadolinium-enhanced imaging in multiple sclerosis: Is contrast needed for routine follow-up MRI? *AJNR Am J Neuroradiol*. 2019; 40(9): 1476–1480.
- Sahin H, Panico C, Ursprung S, Simeon V, Chiodini P, Frary A, et al. Non-contrast MRI can accurately characterize adnexal masses: a retrospective study. *Eur Radiol*. 2021; 31(9): 6962–6973.
- Sari S, Verim S, Hamcan S, Battal B, Akgun V, Akgun H, et al. MRI diagnosis of dural sinus - cortical venous thrombosis: Immediate post-contrast 3D GRE T1-weighted imaging

- versus unenhanced MR venography and conventional MR sequences. *Clin Neurol Neurosurg.* 2015; 134: 44–54.
- Schneider G, Maas R, Kool LS, Rummeny E, Gehl HB, Lodemann KP, Kirchin MA. Low-dose gadobenate dimeglumine versus standard dose gadopentetate dimeglumine for contrast-enhanced magnetic resonance imaging of the liver: an intra-individual crossover comparison. *Invest Radiol.* 2003; 38(2): 85–94.
- Schubert T, Takes M, Aschwanden M, Klarhöfer M, Haas T, Jacob AL, et al. Non-enhanced, ECG-gated MR angiography of the pedal vasculature: comparison with contrast-enhanced MR angiography and digital subtraction angiography in peripheral arterial occlusive disease. *Eur Radiol.* 2016; 26(8): 2705–2713.
- Schüller-Weidekamm C, Lodemann KP, Grisar J, Schüller G, Weber M, Kainberger F, et al. Contrast-enhanced MR imaging of hand and finger joints in patients with early rheumatoid arthritis: Do we really need a full dose of gadobenate dimeglumine for assessing synovial enhancement at 3T? *Radiology.* 2013; 268(1): 161–169.
- Shakoor D, Demehri S, Roemer FW, Loeuille D, Felson DT, Guermazi A. Are contrast-enhanced and non-contrast MRI findings reflecting synovial inflammation in knee osteoarthritis: A meta-analysis of observational studies. *Osteoarthritis Cartilage.* 2020; 28(2): 126–136.
- Sun C, Wang S, Chatterjee A, Medved M, Eggner S, Karczmar GS, et al. T2\*-weighted MRI as a non-contrast-enhanced method for assessment of focal laser ablation zone extent in prostate cancer thermotherapy. *Eur Radiol.* 2021; 31(1): 325–332.
- Takahashi S, Murakami T, Takamura M, Kim T, Hori M, Narumi Y, et al. Is half-dose contrast-enhanced three-dimensional MR angiography sufficient for the abdominal aorta and pelvis? *J Magn Reson Imaging.* 2004; 19(2): 194–201.
- Tamada T, Kido A, Yamamoto A, Takeuchi M, Miyaji Y, Moriya T, et al. Comparison of biparametric and multiparametric MRI for clinically significant prostate cancer detection with PI-RADS version 2.1. *J Magn Reson Imaging.* 2021; 53(1): 283–291.
- Telegrafo M, Rella L, Stabile Ianora AA, Angelelli G, Moschetta M. Unenhanced breast MRI (STIR, T2-weighted TSE, DWIBS): An accurate and alternative strategy for detecting and differentiating breast lesions. *Magn Reson Imaging.* 2015; 33(8): 951–955.
- Thierfelder KM, Meimarakis G, Nikolaou K, Sommer WH, Schmitt P, Kazmierczak PM, et al. Non-contrast-enhanced MR angiography at 3 Tesla in patients with advanced peripheral arterial occlusive disease. *PLoS One.* 2014; 9(3): e91078.
- Tomasian A, Salamon N, Lohan D, Jalili M, Villablanca JP, Finn JP. Supra-aortic arteries: contrast material dose reduction at 3.0-T high-spatial-resolution MR angiography--feasibility study. *Radiology.* 2008; 249(3): 980–990.
- Veldhoen S, Behzadi C, Lenz A, Henes FO, Rybczynski M, Von Kodolitsch Y, et al. Non-contrast MR angiography at 1.5 Tesla for aortic monitoring in Marfan patients after aortic root surgery. *J Cardiovasc Magn Reson.* 2017; 19(1): 82.
- Von Tengg-Kobligk H, Ley-Zaporozhan J, Henninger V, Grünberg KM, Giesel FL, Böckler D, et al. Intraindividual assessment of the thoracic aorta using contrast and non-contrast-enhanced MR angiography. *RöFo Fortschritte Röntgenstr.* 2009; 181(3): 230–236.
- Zarei F, Ghaedian M, Ghaedian T. The role of contrast-enhanced and non-contrast-enhanced MRI in the follow-up of multiple sclerosis. *Acta Radiol.* 2021; 62(7): 916–921.
- Zhang J, Ding S, Zhao H, Sun B, Li X, Zhou Y, et al. Evaluation of chronic carotid artery occlusion by non-contrast 3D-MERGE MR vessel wall imaging: comparison with 3D-TOF-MRA, contrast-enhanced MRA, and DSA. *Eur Radiol.* 2020; 30(11): 5805–5814.
- Zidan DZ, Elghazaly HA. Can unenhanced multiparametric MRI substitute gadolinium-enhanced MRI in the characterization of vertebral marrow infiltrative lesions? *Egypt J Radiol Nucl Med.* 2014; 45(2): 443–453.

## Supplemental Tables

### Supplemental Table S1.

#### Physicochemical characteristics of Iodine-Based Contrast Media

Name	Structure	Ionicity	Application	Concentration (mg/ml)	Molecular Weight (Dalton)	Osmolality 37°C (mOsm/kg)	Viscosity 37°C (mPa·s)	1-Butanol/Water Partition Coefficient 37°C <i>P</i> (log <i>P</i> )
Iohexol	Monomeric	Nonionic	IV	300	821	690	6.2	0.082 (-1.086)
Iopromide	Monomeric	Nonionic	IV	300	791	586	4.6	0.149 (-0.827)
Iopamidol	Monomeric	Nonionic	IV	300	777	616	4.7	0.089 (-1.050)
Iomeprol	Monomeric	Nonionic	IV	300	777	521	4.5	0.105 (-0.979)
Ioversol	Monomeric	Nonionic	IV	300	807	645	5.5	0.031 (-1.509)
Iobitridol	Monomeric	Nonionic	IV	300	835	695	6.0	NA
Iodixanol	Dimeric	Nonionic	IV	320	1550	290	11.4	0.028 (-1.552)
Diatrizoate*	Monomeric	Ionic	Oral	370	614	2150	8.9	0.044 (-1.356)
Ioxitalamate*	Monomeric	Ionic	Oral	300	644	1710	5.3	NA

NA = not available

**Supplemental Table S2.**

**Physicochemical characteristics and stability constants of Gadolinium-Based Contrast Agents**

Name	Ligand	Structure	Ionicity	Molecular Weight ( <i>Dalton</i> )	Osmolality ( <i>mOsm/kg</i> )	Viscosity 37°C ( <i>mPa·s</i> )	T1 relaxivity in blood, 1.5T ( <i>L/mmol·s</i> )	T2 relaxivity in blood, 1.5T ( <i>L/mmol·s</i> )
Gadopentetate	DTPA	Linear	Ionic	939.0	1960	2.9	4.3	4.4
Gadodiamide	DTPA-BMA	Linear	Nonionic	537.6	789	1.4	4.6	6.9
Gadobenate	BOPTA	Linear	Ionic	1058.2	1970	5.4	6.7	8.9
Gadoxetate	EOB-DTPA	Linear	Ionic	682.0	688	1.2	7.3	9.1
Gadoteridol	HP-DO3A	Macrocyclic	Nonionic	558.7	630	1.3	4.4	5.5
Gadobutrol	BT-DO3A	Macrocyclic	Nonionic	604.7	1603	4.9	5.3	5.4
Gadoterate	DOTA	Macrocyclic	Ionic	558.6	1350	2.0	4.2	6.7
Gadopiclenol	NA	Macrocyclic	Nonionic	970.1	843	7.6	12.8	15.1

Name	Ligand	Thermodynamic Stability (pH 14) (Log Ktherm)	Conditional Stability (pH 7.4) (Log Kcond)	Kinetic Stability (37°C, pH 1) (T½; hours)	Dissociation Constant Kobs (s-1)	Excess Ligand (mmol/l)	Stability Classification EMA
Gadopentetate	DTPA	22.5	18.4	0.16	0.58	1	Low
Gadodiamide	DTPA-BMA	16.9	14.9	0.01	12.7	25	Low
Gadobenate	BOPTA	22.6	18.4	NA	0.41	0	Intermediate
Gadoxetate	EOB-DTPA	23.5	18.7	NA	0.16		Intermediate
Gadoteridol	HP-DO3A	23.8	17.1	2.0	0.00026	0.5	High
Gadobutrol	BT-DO3A	21.8	15.5	7.9	0.000028	1	High
Gadoterate	DOTA	25.6	19.3	26.4	0.000008	0	High
Gadopiclenol	NA	18.7	15.5	120.0	0.000002	NA	NA

NA = not available

Sources S2: *van der Molen, Eur J Radiol 2008; Port, Biometals 2008; Rohrer, Invest Radiol 2005; Robic, Invest Radiol 2019; Szomolanyi, Invest Radiol 2019; Personal communication with medical departments of Bayer Healthcare, Bracco Imaging, GE Healthcare, Guerbet.*